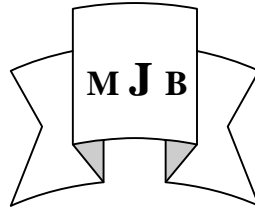


## **T-Tube Drainage VS Choledochoduodenostomy or pre-operative ERCP for the Management of Intrabiliary Rupture of Hydatid Cyst of the Liver**

Adel Shaker Al-Tamimi

College of Medicine, Al- Qadissiyia University, Al-Diwaniya, Iraq.



### **Abstract**

**Background:** Intrabiliary rupture is one of the common complications of hydatid cyst of the liver, with its possible sequel of obstruction, cholangitis and post operative biliary fistula. It should be managed properly, with accurate pre operative diagnosis and proper surgery, both for the cyst and some sort of biliary drainage with the available alternatives common bile duct exploration and T-tube drainage, choledochoduodenostomy or a pre operative endoscopic sphincterotomy, the choice is a matter of controversy.

**Objectives:** To evaluate three methods of biliary drainage, (T-tube, choledochoduodenostomy, or preoperative endoscopic sphincterotomy) during management of intrabiliary rupture of hydatid cyst of the liver, in terms of morbidity and mortality rates.

**Methods:** During the period between October 2001 till October 2007. 92 patients attending Baghdad and Al-Diwaniya Teaching Hospitals, presented with symptomatic intrabiliary rupture of hydatid cyst liver disease were included in the study, they complained from abdominal pain and jaundice, all patients were diagnosed preoperatively by ultrasonography, CT scan and Magnetic resonance cholangiopancreatography (MRCP) was performed in selected patients, 42 patients were selected randomly and subjected preoperatively to ERCP and sphincterotomy, in whom it was successful in only 36 patients. During surgery, the cyst and the associated biliary communication was managed according to the operative circumstances. The common bile duct was explored thoroughly and cleaned of hydatid element. In patient with CBD diameter > 20 mm side to side choledochoduodenostomy was performed ( 7 patients ) , while T- tube drainage was performed in younger age patients with mildly dilated CBD ( 49 patients ) . Those patients in whom a preoperative ERCP and sphincterotomy was successful, surgery was limited to hepatic hydatid cyst only (36 patients).

**Results:** The overall mortality was 1.1%, the morbidity rate was significantly higher in the CD (71.4%) and pre operative ERCP group (47.2%) than the T-tube drainage group (26.5%). There was no significant difference in the rate of development of biliary fistula in the 3 different procedures.

**Conclusion:** T-tube drainage is safe and effective method of biliary drainage during the management of intrabiliary rupture of hydatid cyst of the liver, in terms of morbidity and mortality rates. Pre operative endoscopic sphincterotomy is good alternative in experienced hands.

### **الخلاصة**

يعتبر الانشقاق داخل القنوات الصفراوية من اكثر المضاعفات شيوعا في الاكياس المائية للكبد مع احتمالات انسداد او التهاب القنوات الصفراوية اضافة الى الناسور الصفراوي , لذا يجب معالجتها بشكل دقيق مع اهمية التشخيص الدقيق قبل التدخل الجراحي

للكيس اضافة الى طريقه لبزل القنوات الصفراويه بالخيارات المتاحة وهي استكشاف القناة الصفراويه و وضع انبوب (تسي) او عملية ربط القناة الصفراويه بالاثني عشري او شق المعصره الصفراويه المنظاري قبل التداخل الجراحي.

الهدف: لتقييم ثلاثة طرق لبزل القناة الصفراويه ( بواسطة انبوب( تي) او ربط القناة الصفراويه بالاثني عشري او شق المعصره الصفراويه المنظاري قبل التداخل الجراحي ) اثناء معالجة الاكياس المائيه للكبد حسب مفردات نسبة المضاعفات و الوفيات.

الطريقة:تمت دراسة 92 مريضاً في مستشفى بغداد والديوانية التعليميين كانوا مصابين باكياس مائيه في الكبد مع انشقاق داخل القنوات الصفراويه ويعانون من الام البطن واليرقان الانسدادي , تم تشخيص جميع المرضى بواسطة السونار و بعض المرضى المنتخبين تم تشخيصهم بواسطة المفراس والرنين المغناطيسي.تم اجراء عملية شق المعصره الصفراويه المنظاري ل42 مريضاً تم اختيارهم عشوائيا والتي نجحت في 36 مريض فقط.اثناء التداخل الجراحي تم معالجة الكيس وانشقاقه الصفراوي حسب ما تقتضيه ظروف الجراحه و تم استكشاف القناة الصفراويه وتنظيفها من مواد الاكياس, في المرضى ذوات قناة صفراويه بقطر اكثر من 20 ملم تم ربط القناة الصفراويه بالاثني عشري(7 مريض) , اما انبوب (تي) فتم استخدامه في المرضى ذوي القناة الصفراويه بسيطة التوسع (49 مريض). في المرضى الذين تم شق المعصره الصفراويه المنظاري بنجاح , اقتصر التداخل الجراحي للكيس فقط(36 مريض).

النتائج: كانت نسبة الوفيات 1.1%, وكانت نسبة المضاعفات في مجموعة مرضى ربط القناة الصفراويه بالاثني عشري (71.4%) ومجموعة مرضى شق المعصره الصفراويه المنظاري(47.2%) هي اكثر بنسبه احصائيه ملحوظه من مجموعة مرضى انبوب(تي)(26.5%).لم نجد فرق احصائي ملحوظ في تطور الناسور الصفراوي في المجاميع الثلاث.

الاستنتاج: ان عملية وضع انبوب(تي) هي وسيله امينه وفعاله لبزل القناة الصفراويه عند معالجة انشقاق اكياس الكبد المائيه داخل القنوات الصفراويه اعتمادا على مفردات نسبة المضاعفات والوفيات. ان عملية شق المعصره الصفراويه المنظاري قبل التداخل الجراحي هو بديل جيد عند توفر الخبره في هذا المجال.

## Introduction

Frank intrabiliary rupture of hydatid cyst of the liver was first reported in 1928 by Dew [1]. Communication between the cyst and the biliary tree is almost always present [2, 3]. Frank intrabiliary rupture is one of the common complications of liver hydatid with approximate incidence of 5-25%. [4]. The high intra cystic pressure (active parasite) in the presence of biliary communication, forces the hydatid cyst elements into the biliary tree causing obstruction and cholangitis. The communication can be tangential usually in centrally located cyst with large caliber duct involved , or terminal usually in peripherally located cyst and the communication usually involve small caliber bile duct[2,4], such, communications is usually found during surgery and if not, they should be sought thoroughly,

and unless they are treated by immediate closure , they will be a source of post operative biliary fistula which may becomes intractable if distal common duct obstruction is unrelieved [ 5,6]

Symptomatic intrabiliary rupture should be diagnosed preoperatively and the status of the biliary tree should be evaluated in order to arrange a planned surgery to achieve the best results [7,8,9]. The definitive diagnosis of intrabiliary rupture of hydatid cyst, depends on the demonstration of intrabiliary hydatid material using ultrasound, CT scan or MRCP [3,5,8]. The surgical action should accomplish two goals, the management of the cyst and exploration and drainage of the CBD by open or endoscopic method. [8] ERCP has proven to be valuable tool for the diagnosis of rupture into the biliary tract and can provide a

preoperative sphincterotomy for CBD clearance and drainage. [3,8] The first complete endoscopic management of liver hydatid cyst with intrabiliary rupture, was reported by Al- Karawi in 1985.[10]

### **Aim of the Study**

To evaluate three methods of biliary drainage, during the management of intra biliary rupture of hydatid cyst of the liver namely T-tube drainage, choledochoduodenostomy and pre operative ERCP, in terms of mortality and morbidity rates including the post operative biliary fistula.

### **Method**

92 patients with symptomatic intrabiliary rupture of hydatid cyst liver disease were managed between October 2001 till October 2007 in Baghdad and AL-Diwaniya Teaching hospitals.

All patients had an obstructive jaundice. There were 54 female and 38 male with an age range from 19-72 years (mean= 38 years).

The duration of symptoms ranged from 20 days – 4 months. All patients complained from abdominal pain and jaundice, and 12 patients of clinical cholangitis.

All patients subjected to an initial ultrasonography, 26 patients were subjected to an additional CT scan, 36 patients were subjected to a preoperative MRCP in whom the ultrasonic findings was questionable, in addition to the conventional laboratory proof of obstructive jaundice .

All patients were diagnosed preoperatively. 74 patients have single cyst, 15 have double cyst, and 3 have 3 cyst. 78.2% (n=72) of the cysts were located in the right lobe of the liver,

19.6% (n=18) in the left lobe and 2.2 % (n=2) in both lobes. 42 patients were subjected preoperatively to ERCP and sphincterotomy in both Baghdad and Al- Najaf gastroenterology centers in whom it was successful in only 36 patients, with the other 6 patients returned to the conventional surgery and CBD exploration. In all cases 2nd or 3rd generation cephalosporin were administered intravenously during anesthetic induction. Right subcostal and midline incisions were utilized in 72 and 20 patients respectively.

### **Technique**

During surgery, the cyst was opened and cleaned of all hydatid material; the cavity was explored to detect biliary openings through which bile leaked. Identification of the site of the biliary communication usually made by direct inspection, however more recently, choledochoscopy, or laparoscopic camera, can provide 20 times magnification and better identification of the biliary openings[11,12] , this policy was adopted in 21 patients , when biliary communications was found then they closed safely with absorbable suture in peripheral cysts with small size duct involvement, however in centrally located cysts, the communications are usually with larger size duct and on attempt to close such communications may jeopardize major bile ducts, so careful closure is preferable, and in porta hepatitis cysts attempting closure would be dangerous undertaking, and it is safer to clear the cyst, with the communication left unsutured.[2,3,13,14,15]

Following exploration of the CBD, the biliary tree was washed thoroughly with saline and all parasitic elements removed, the common, Rt. and Lt. Bile ducts were irrigated with isotonic saline solution.

In 21 cases completion choledochoscopy were used to explore the CBD to ensure that the hydatid materials and debris has been removed. [11, 12], then a method of biliary drainage was attempted, the choice would be either T-tube or CD, except cases in whom preoperative endoscopic sphincterotomy was successful.

Following removal of all hydatid elements from the hepatic cyst, the cavity was managed by partial cystectomy capitonage or partial cystectomy plus intra flexion, in attempt to reduce the cavity size. In all patients external drainage of the cyst cavity was provided due to a constant risk of biliary fistula with concomitant cholangitis, on attempting this policy, high success rate would be achieved.[3,16,17,18].

In patient with CBD diameter > 20 mm , and more than 45 years of age , side to side choledochoduodenostomy was performed ( 7 patients ) , while T-tube drainage was performed in younger age patients with mildly dilated CBD (49 patients)[2,4,7]. Those patients in whom a preoperative ERCP and sphincterotomy was successful, surgery was limited to dealing with the hydatid cyst only (36 patients) [2,6,11,19]. During the post operative period cavity drainage was removed when it cease to function, T-

tube cholangiogram done 14 days post operatively. The three groups were compared with regard to the morbidity and mortality. [4, 19] All patients were followed up for one year post operatively.

The data were analyzed by Ep1 ver 6.2 computer soft ware system. The statistical significance of the calculated estimate (OR) was assessed by chi square test, P value less than 0.05 was considered statistically significant.

### **Results**

The overall mortality was 1.1% with one patient in the ERCP group who deteriorates 3 days following the procedure with features of developing sepsis for which laparotomy was done and missed retroperitoneal duodenal perforation was found and the patient died in the 7th post operative day. The over all morbidity rate was 38% and procedure related morbidity was 26.5%, 71.4%, 47.2% in T-tube, CD and pr operative ERCP respectively. The main post operative complications in order of frequency were biliary fistula, pulmonary complications, wound infection, recurrent jaundice, anastomotic leakage and residual intra abdominal abscess, and complications related to ERCP (hemorrhage, perforation and acute pancreatitis) as in the following table.

**Morbidity rate in 3 methods of biliary drainage**

<b>Morbidity</b>	<b>T-tube</b>	<b>CD</b>	<b>ERCP</b>
<b>ERCP related</b>	<b>0</b>	<b>0</b>	<b>9</b>
<b>Biliary fistula</b>	<b>6</b>	<b>1 P=0.87</b>	<b>4 P=0.8</b>
<b>Pulmonary complications</b>	<b>3</b>	<b>2</b>	<b>2</b>
<b>Wound infection.</b>	<b>2</b>	<b>1</b>	<b>2</b>
<b>Residual abscess</b>	<b>1</b>	<b>0</b>	<b>0</b>
<b>Recurrent jaundice</b>	<b>1</b>	<b>0</b>	<b>0</b>
<b>Anastomotic leakage</b>	<b>0</b>	<b>1</b>	<b>0</b>
<b>Total no.</b>	<b>13 (26.5%)</b>	<b>5 (71.4 %)</b>	<b>17(47.2 %)</b>
<b>P value</b>	<b>Reference</b>	<b>0.017</b>	<b>0.0485</b>

\* P=P value of less than 0.05 regarded as statistically significant.

Comparison of morbidity rate of the 3 different approaches revealed a significantly higher morbidity rate in the CD and pre operative ERCP groups than the T-tube drainage group with P value = 0.017 , 0.0485 respectively. There was no significant difference in the rate of development of biliary fistula in the 3 different procedures P value =0.87. Patients with T-tube drainage who developed biliary fistula the T- tube removal was delayed for 3-6 weeks with two cholangiograms performed one at day 14 and the other before removal i.e. cessation of fistula drainage, biliary fistulas developed in 6, 1 and 4 patients with T- tube, CD and pre operative ERCP respectively, all fistulas ceased to drain within 1-8 weeks. In all patients with biliary fistula in the T- tube group, the 1st cholangiogram showed functional spasm of the sphincter of Oddi which resolved in the 2nd cholangiogram. One patient who developed subphrenic abscess was managed by per cutaneous

drainage under ultrasound control. Complications related to ERCP per se were mainly related to sphincterotomy, with 5 patients develop hemorrhage, managed conservatively with transfusion, and 4 patients develop acute pancreatitis which resolved after 2-7 days without sequel. Six patients who were arranged for pre-operative ERCP and sphincterotomy in whom there was failure of cannulation of the papilla, they were converted to the conventional open surgery and included in the T- tube group. One patient develop jaundice 11 months following surgery and investigations revealed recurrent hydatid cyst of the liver with new story of intrabiliary rupture, in whom a pre operative ERCP and sphincterotomy was successful and the recurrent hydatid managed by conventional surgery.

## **Discussion**

The surgical management of hydatid cyst of the liver with intrabiliary rupture should be preceded by accurate and extensive diagnostic workup, starting with ultrasound examination which was used as initial screening tool in all our patients, presented with clinical or biochemical jaundice, CT scan was unable to delineate the exact level of biliary obstruction, or determine the nature of obstructing element whether daughter vesicles or fragment of hydatid membrane [5,7,8,9]. Preoperative MRCP was beneficial in planning the surgery and define the nature of intrabiliary pathology. [19]

Following T-tube insertion, the main problem at this stage was the functional spasm of Oddi sphincter, an occurrence which was first referred to by Gionard in 1955 who defined it as Oddi fibrosis caused by hydatid cyst [19,20], however this is not an organic fibrosis, but a functional and temporary spasm resulting from allergic reaction caused by the eau de roche passing into the CBD from the cyst rupturing into the biliary tree, which disappear soon following treatment of the cyst and the flow of hydatid material into the CBD has stopped. The flow of bile should be diverted temporarily to rest the Oddi sphincter until the time when the bile dynamics in the CBD returned to normal [2,19,20], therefore a T-tube drainage, instead of complicated procedures is sufficient for this purpose. Some authors preferred the CD as reference to the disadvantage of T-tube drainage, on the fact that T-tube itself can even cause obstruction in the post operative period, in addition it may be a source of infection and bile loss[17,21], in fact these complications was not observed in this study. We use CD in old patient with

markedly dilated CBD which is infrequent in hydatid cyst with intrabiliary rupture. Most authors prefer T- tube drainage [14,16, 20, 22, 23], the advantage of t-tube, is that it dose not damage the structure of Oddi sphincter with preservation of its normal anatomy and physiology, moreover T- tube provides means to perform subsequent cholangiographies [22,23], in addition the study revealed the lowest morbidity 26.5% with no mortality these results were comparable with other studies in which the morbidity was 19.44-43.03% with 1.8-4.5% mortality[ 24]. The length of time, the T-tube should remain in place would be largely dependant upon the rate of fistula drainage and the CBD patency as seen by cholangiography[23]. A successful preoperative ERCP and sphincterotomy provides a good diagnostic role and therapeutic drainage of the CBD, however success rate of ERCP was only 85% and is not without complications, the rate of which is a matter of endoscopist experience, and in this study appeared to be greater than T-tube drainage [6,25] however in reviewing other series they regard endoscopic sphincterotomy as an alternative treatment for patient with biliary hydatid disease with success rate of 95-100% with zero mortality and 17% morbidity[26], in other study which include 1177 patients over 2 years period, they found 30 days morbidity rate of 15.9%and procedure related mortality of 1%.[27]

## **Conclusion**

There is no single ideal management for intrabiliary rupture of hydatid cyst of the liver and the type of the surgical procedure should be tailored to the individual patient and the surrounding circumstances, however T-tube drainage appeared to be safe and effective method of cure with the



lowest morbidity rate. Preoperative endoscopic sphincterotomy is good alternative, the success rate and morbidity of which is highly dependant upon individual experience and in the hands of highly experienced endoscopist may be the best option.

### **Recommendation**

In this study, better results have been obtained with T- tube, morbidity and mortality wise, therefore T- tube drainage is a recommended procedure for most cases of hydatid cyst liver with intrabiliary rupture.

### **References**

1. Dew H; Some complications of hydatid disease, Br J, surg 1936 18; 275 -393.
2. Milicevic M: Hydatid disease; Blumgart LH Ed; surgery of the liver and biliary tract, ed 3, Edinburgh, Churchill Livingstone, 2001, pp 1176-1204.
3. Kornaras SE , Aboul-Nour TA: Frank intrabiliary rupture of hydatid hepatic cyst; diagnosis and treatment. J Am coll surg 1996;183: 466-470.
4. Barnes S, Lillemoe K: Liver abscess and hydatid cyst disease , In Zinner M, Schwartz S, Ellis H, Ashley S, McFadden D. (ed) Maingots Abdominal operations , 10th ed . Stamford CT Appleton and Lang 1997;1513-1545.
5. Marti-Bonmati L, Menor F, Ballesta A: Hydatid cyst of the liver: rupture into the biliary tree .AJR 1988; 150, 1051-1053.
6. Al Karawi MA, El-Shiekh Mohamed AR, Yasawy MI: Advances in diagnosis and management of hydatid disease. Hepato-Gastroenterology 1990;22:327-331.
7. Sayek I, Onat D. Diagnosis and treatment of complicated hydatid cyst of the liver . World J surg. 2001; 25: 21-27.
8. Kumar A, Lal BK, Chattopadhyay TK: Hydatid jaundice – an overview. Trop Gastroenterology 1993;14: 10-15.
9. Gharbi HA, Hassine W, Brauner MW et al. Ultrasound examination of hydatid liver , Radiology 1981;139 , 459.
10. Al Karawi M, Hanid MA: Endoscopic removal of daughter Echinococcus cyst from the common bile duct. Hepato-gastroenterology 1985;32:296- 298.
11. Elefteriadis E, Tzartinoglou E, Kotzampassi K, Aletras H: Choledochoscopy in intrabiliary rupture of hydatid cyst of the liver. Surg Endoscopy 1987;1: 199-200.
12. Erterm M, Karahasanoglu T, Yuvuz N et al Laparoscopically treated hydatid cysts. Arch surg;2002;137:1170.
13. Magistrelli P, Masetti R, Coppola R, Messia A, Nuzzo G, Picciocchi A: Surgical treatment of hydatid disease of the liver. Arch Surg 1991; 126:518-523.
14. Humayun MS, Rady AM, Soliman GM: Obstructive jaundice secondary to intrabiliary rupture of hepatic hydatid cyst. Int. surg 1989; 74: 4-6.
15. Akinoglu A, Bilim I, Erkocak EU: Surgical management of hydatid disease of the liver. Can J surg 1985;28:171-174.
16. Dadoukis J, Gamvros O, Aletros H.: Intrabiliary rupture of the hydatid cyst of the liver. World J surg 1984;8:786-790.
17. Gonzales EM, Selas PR, Martinez B, Garcia IG, Carazo FP, Pascual MH: Results of surgical treatment of hepatic hydatidosis : current therapeutic modification . World J surg 1991;15: 254-263.
18. Goldbalatt M, Pitt H: Hepatic Echinococcosis . In : Cameron J , Current surgical therapy 8th ed .

Philadelphia PA: Elsevier Mosby, 2004 ; 306- 311.

19. Pedrosa I, Saiz A, Arrazola J et al : Hydatid disease , Radiologic and pathologic features and complications 2000 ;20: 795-817.

20. Kayabali I, Cavusoglu T, Kutlu H, Yerdel MA: Pathophysiology, diagnosis and management of intrabiliary rupture of hydatid cyst of the liver ( a retrospective study of 32 cases ). Turk J gastroenterohepatology 1991;2:209-212.

21. Alpe A, Ariogul O, Emre A, Uras A, Okten A: Choledochoduodenostomy for intrabiliary rupture of hydatid cyst of the liver. Br J Surg 1987;74:243-245.

22. Katan YB: Intrabiliary rupture of hydatid cyst of the liver. Br J surg 1975; 62:885-890.

23. Orhan E, Haldun G , Mehmet C et al : surgical treatment of intrabiliary

rupture of hydatid cysts of the liver : comparison of choledochoduodenostomy with T-tube drainage . J digestive surg Turkey 2001;18:289-293.

24. Kenan Erzurumlu, Adem Dervisoglu et al, Intrabiliary rupture, An algorithm in the treatment of controversial complications of hepatic hydatidosis , Gastroenterology J 2005,11;2472-2476.

25. Vignote ML, de la Mata M, de Dios JF, Glomez F : Endoscopic sphincterotomy in hepatic hydatid disease open to the biliary tree . Br J surg 1990;77: 30-31.

26. H Rijina , W.G.N. Kenps et al Digestive surgery vol. 17, no.3 2000.

27.Christensen G et al, Gastrointestinal endoscopy ,60(5);721,30, November 2004