

Role of Barley in the improvement of Nephrocalcinosis in experimental rabbit model

Rafi A. M. Al-Razzuqi, Zainab A. Al-Ebady¹

Department of Pharmacology and Therapeutics, Al-Yarmouk University, Baghdad, Iraq.

¹Department of Pharmacology, Al-Diwanyia University, Al-Diwanyia, Iraq.

Address for correspondence:

Dr. Rafi AM Al-Razzuqi, Department of Pharmacology and Therapeutics, Al-Yarmouk University, Baghdad, Iraq. E-mail: rafialmajeed@yahoo.com

ABSTRACT

Introduction: Nephrocalcinosis is a state of deposition of calcium phosphate or oxalate in the renal parenchyma. It may occur in patients with renal tubular acidosis, vitamin D intoxication, and hyperparathyroidism. **Aim:** According to traditional medicine, which mentioned Barley as a herbal remedy for relieving renal pain, we attempted to evaluate the effectiveness of barley in improving nephrocalcinosis induced by a large dose of oxalic acid in a rabbit model. **Materials and Methods:** Fourteen healthy rabbits were allocated to two groups. 2 hours before induction of nephrocalcinosis, a group received water and the other received aqueous extract of barley and continued feeding for ten days. Blood samples were collected for biochemical analysis before induction and in the tenth post-induction day. Urine samples were taken to estimate urinary Ca^{2+} levels and crystals. The histopathological examination was carried to check for crystal deposits in renal tissues. **Results:** The results showed a significant reduction in blood urea nitrogen and serum Na^+ levels with insignificant change in serum creatinine and K^+ in comparison with the control group. It revealed a significant reduction in calcium deposition from renal parenchyma after 10 days of treatment, with improvement in nephrocalcinosis severity. **Conclusion:** Barley showed a significant diuretic and attenuating effect on reducing calcium deposits from renal parenchyma.

Key words: Barley, nephrocalcinosis, oxalic acid, renal tubular acidosis

INTRODUCTION

Nephrocalcinosis (NC) is a state of deposition of calcium in the form of phosphate or oxalate in the renal parenchyma that can impair kidney function.^[1] It can occur in patients with renal tubular acidosis, hyperparathyroidism, vitamin D intoxication, and healing of renal tuberculosis etc.^[2] The fragments of calcium salts may break free from the kidney to provide nuclei for the formation of different types and

sizes of stones accompanied by many symptoms.^[3] They may be consequences of genetic, dietary, water intake, environmental, and occupational factors.^[4] In traditional medicine, some medicinal plants like Barley were used to relieve renal pains.^[5] This study was made to evaluate the possible nephroprotective effect of aqueous extract of *Hordeum distichum* (Barley) in experimental model of Nephrocalcinosis (NC).

MATERIALS AND METHODS

In this study, 14 healthy rabbits weighing 900-1,100 g were used, which was approved by the ethics committee in the Al-Yarmouk University. The animals were supplied by animals' house of college of medicine. Animals were kept in separate cages provided with a wide wire mesh floor. They were fed standard oxid pellets and water *ad libitum*. The

Access this article online	
Quick Response Code: 	Website: www.ijnpnd.com
	DOI: 10.4103/2231-0738.77535

animals were allocated to two groups (each group contained seven animals).

G1 (control group) received 3 ml of water orally 2 hours before induction of NC by oxalic acid (HandW England) as a single dose of 333 mg/kg orally using a gastric tube.

G2 was given aqueous extract of Barley 1 g/kg orally as a single daily dose started at 9 am, followed by oxalic acid as a single dose of 333 mg/kg orally using a gastric tube at 11 am for induction of NC. The animals were continuously fed the aqueous extract for 10 days post induction.

The aqueous extract of barley is prepared by diluting one volume of well grinded plant to 10 volume of water at 80 °C in stopper flask. After shaking well, it is allowed to stand for 10 minutes then cooled and filtered to be used within 12 hours.^[6] The blood samples were collected from marginal ear vein for biochemical analysis and renal functions, before induction of NC to determine the normal values of blood urea nitrogen (BUN), serum creatinine, Na⁺ and K⁺ by using spectrophotometer method^[6] on the first and tenth day after induction. Urine samples were taken from the animals by catheterization after anaesthetizing them on the last day of the study to estimate urine Ca⁺² levels and search for crystals. Histopathological examination was carried to check for crystal deposits in renal tissues with the help of a polarized microscope after fixation and staining of

specimens.^[7] The results obtained were analyzed and assessed.

STATISTICAL ANALYSIS SECTION

We transformed the hazard ratios occurred during the research to their natural logarithms by calculating standard errors and corresponding confidence intervals to account for statistical heterogeneity between our study and Ahmad's study.^[9] The data were analyzed using SPSS version (version 12). We carried out group analyses based on the parameters changes before and after the induction of nephrocalcinosis in the study models besides we calculated the standard deviation of each parameter. Significance was set at P<0.05.

RESULTS

The results of this study revealed significant elevation in the levels of BUN, both serum creatinine and K⁺, with significant reduction of serum Na⁺ levels in the control group as compared to the levels of pre-induction state [Tables 1-4]. The results of barley (group 2) revealed a significant reduction in BUN (5.18 ± 0.16 vs 7.3 ± 0.2) mmol/L and reduction in serum Na⁺ levels (137.6 ± 0.4 vs 142.16 ± 0.7) mmol/L, with P < 0.05. There is insignificant change in serum creatinine (97.0 ± 0.03 vs 97.3 ± 0.5) mmol/L and serum K⁺ (4.3 ± 0.16 vs 4.2 ± 0.05) mmol/L in comparison with the control group after one day. The change in these levels became more evident after 10 days.

DISCUSSION

Nephrocalcinosis was induced in the experimental model by using a single large dose (333 mg/kg) of oxalic acid (a highly oxidising and strong Ca⁺² chelator) and this dose had been selected after several trials.^[8] We did not use Ahmad's method^[9] (where, a single oral daily dose of oxalic acid 200 mg/day was given to the animals over a period of two weeks) to induce NC, as it is material and time-consuming method. In our model of

Table 1: Mean BUN, S creatinine, K⁺, Na⁺, and urine Ca⁺² levels of the studied animals measured before induction of NC

Analyte	Measured levels (mmol/L)
BUN	4.0 ± 0.07
S creatinine	65.0 ± 8.9
S K ⁺	3.3 ± 0.8
S Na ⁺	160.0 ± 4
Urine Ca ⁺²	2.05 ± 0.07

Table 2: Mean BUN and S creatinine levels of the studied groups measured after induction of NC

Group	Agent	Dose	BUN (mmol/L)		S Creatinine (mmol/L)	
			After 1 day	After 10 days	After 1 day	After 10 days
1	Oxalic acid (control)	333 mg/kg	7.3 ± 0.2	9.6 ± 0.2	97.3 ± 0.5	100.3 ± 1.2
2	Barley	1 g/kg/day	5.18 ± 0.16	4.8 ± 0.03	97.0 ± 0.03	139.90.0 ± 0.6

Table 3: Mean S K⁺ and S Na⁺ levels of the studied groups measured after induction of NC

Group	Agent	Dose	S K ⁺ (mmol/L)		S Na ⁺ (mmol/L)	
			After 1 day	After 10 days	After 1 day	After 10 days
1	Oxalic acid (control)	333 mg/kg	1 g/kg/day	5.7 ± 0.08	142.16 ± 0.7	137.6 ± 0.4
2	Barley	1 g/kg/day	4.3 ± 0.16	3.7 ± 0.04	137.6 ± 0.4	139.1 ± 0.6

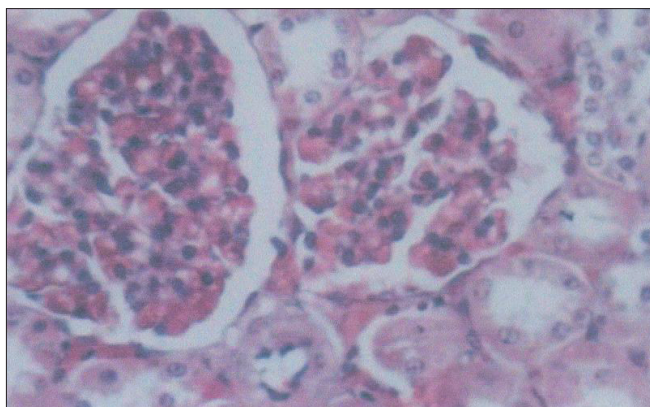


Figure 1: Normal histological appearance of renal tissue of rabbit (crystal-free) in the control group. $\times 40$.

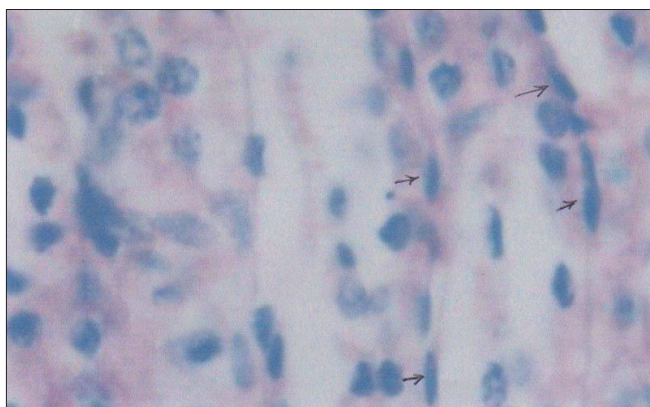


Figure 2: Heavy calcium oxalate crystals deposition in renal tissues of rabbits receiving oxalic acid. $\times 100$.

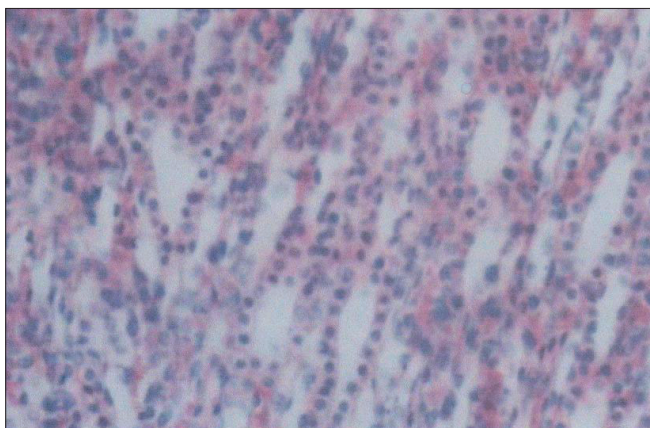


Figure 3: Mild calcium oxalate crystals deposition in renal tissues of rabbits receiving oxalic acid and Barley. $\times 100$.

NC, significant elevation in BUN and serum creatinine levels observed after induction of NC [Tables 2,3]. The idea to use some herbals like barley is to evaluate its effects in improvement of NC. Barley is a highly alkalinising food,^[10] contains a variety of antioxidants

Table: 4 Mean urine Ca^{+2} levels of the studied groups measured 10 days after induction of NC

Group	Agent	Urine Ca^{+2} levels after (mmol/L) 10 days	Crystals in urine examination
1	Oxalic acid (control)	4.1 ± 0.03	Amorphous urate, uric acid, stellar phosphate, calcium and oxalate
2	Barley	5.05 ± 0.02	amorphous urate

including 'natural scavenge reactive oxygen' derivative (SOD).^[11] Research at the University of California Davis had demonstrated that a flavonoid in barley grass known as 2-0-glycosylisovitexin (2-0-GIV) is a potent antioxidant in protecting against fat oxidation in human cells.^[12] Barley grass is high in calcium, iron, all essential amino acids, chlorophyll, flavonoids, vitamin B12, vitamin C, and many minerals, as well as enzymes. It produces significant lowering effect in BUN and serum Na^+ levels with the increase in urine Ca^{+2} levels compared to normal values^[13] and a reduction of its concentration in renal tissue [Figures 1-3]. This is due to its diuretic effect, as it reduces the activity of antidiuretic hormone on renal tubules and prevents sodium reuptake, thus increasing the tubular water bulk.^[14] Some researchers thought that this effect related to natural complexity of essential amino acids that causes water and electrolytes expulsion.^[15]

CONCLUSIONS

Herbs such as Barley have a significant diuretic and attenuating effect in reducing calcium deposits in renal tissues, with a significant effect on lowering oxalic acid toxicity through its diuretic action.

ACKNOWLEDGEMENT

We thank Dr Thulfuqar R Al-Majeed (Department of Medical Laboratory Sciences, Al-Yarmouk University) for helping in examination of the blood samples along with his guidance.

REFERENCES

1. Dorland Medical Dictionary, 2002.
2. Christopher H, Edwin R, Chilver S, John A, Burtis C and Ashood E. Davidson's principles and practice of Medicine. 19th ed. Churchill Livingstone; 2004. p. 594-9.
3. Drach GW. Urinary lithiasis, Camphil urology. WB Sanders Comp; 1998. p. 2085-100.
4. Leyva M. The role of dietary calcium in disease prevention. J Okla-State Med Assoc 2003;96:272-5.
5. David L, Hoffman E. The herbalist and version. Hopki's Technology; 1993.
6. Burtis CA, Ashood ER. Tietz text book of clinical chemistry. WB

Al-Razzuqi and A Al-Ebady.: Role of Barley in the improvement of Nephrocalcinosis in experimental rabbit model

- Sanders Comp; Vol 2, 1999. p. 1059-60.
7. Putt N, Fredrick A. Manual of histopathological staining methods. New York: John Wilay and Sons; 1972. p. 335.
 8. Mendonca DG, Martin LA, Baxmann AC, Nishua IL. Effect of an oxalate load on urinary oxalate excretion in ca²⁺ stone formation. Nephro Divison universida de federal de Sao Paulo Brazil, 2003;13:39-46.
 9. Ahmad AF. Evaluation of the effect of succinic acid administration on the urinary excretion of oxalate urolithiasis. Thesis to Mousal University; 2008.
 10. Forber B, Perrson T. kidney stone. The urology group board, 2004; 241-3.
 11. Al-Jawad FH, Hoshi A. Nephroprotective effect of some antioxidants in induced acute renal failure. Iraqi J Med Sci 2011 [In Press].
 12. Tilgner S. Medical herbalism, clinical and case studies. 1st edition , medical economic company , New jersey, 2001 .
 13. Smith LH. Urolithiasis. In: Schrier RW, Gotts CC, editors. Disease of kidney. WB Sanders Comp.; vol 1, 1996. p. 785-813.
 14. Ives HE. Diuretic agents. Basic and clinical pharmacology edition. In: Katzung BG, Masters SB Treven AJ, editors. 11th international edition. McGraw Hill; 2010.
 15. Finkel R, Cubeddu LX, Clark MA. Pharmacology, 4th international edition. Lippincott Williams and Wilkins; 2009. p. 367-81.

Source of Support: Nil, **Conflict of Interest:** None declared.
Rceived: 17-10-2010, **Accepted:** 01-01-2011

