

See discussions, stats, and author profiles for this publication at: <https://www.researchgate.net/publication/309358237>

# Epidemiological and Bacteriological Study on Subclinical Mastitis in She-Camels (*Camelus dromedarius*) in Some Areas of Middle Euphrates in Iraq

Article · January 2011

CITATION

1

READS

4

3 authors, including:



**Yahia Ismail Khudhair**

University of Al-Qadisiyah

12 PUBLICATIONS 12 CITATIONS

SEE PROFILE

Some of the authors of this publication are also working on these related projects:



Establishment and characterization Iraqi cell line derived from fetal calve kidney (FCKi7) [View project](#)



Detection and molecular analysis of bovine foamy virus cattle in Iraq [View project](#)

# Clinical and Bacteriological Study of Subcutaneous abscesses caused by gram positive bacteria in cow and sheep in Al-Qadisiya province

Y. I. Kh. AL-Tuffyli      M. I. Shekhan  
Coll. of Vet. Med./ Unive of Al-Qadisiya

## Abstract

In spite of the fact that subcutaneous abscesses occur in sporadic cases and cause low morbidity, a total of 79 (56 and 23) abscesses of cattle and sheep respectively were examined during 12 months from November 2010 to October 2011 for determining an anatomical distribution of subcutaneous abscesses with identification of clinical features and isolation of causative agents that cause these abscesses in cow and sheep in Al-Qadisiya province. The head was most commonly affected, followed by (gluteal & neck) and chest regions at percentages 80.36%, 10.71% and 8.92% respectively in cattle, and 82.6%, 13.03%, and 4.34% respectively in sheep. Also the results demonstrated that there are four types of subcutaneous abscesses vary in size (from a nutmeg fruit size up to a muskmelon). Fifty four samples out of 56 abscesses samples of cattle were demonstrated gram positive bacteria only which presented by *Staphylococcus aureus*, *S. epidermidis*, *S. hycus*, *Arcanobacterium pyogenes*, and *Corynebacterium pseudotuberculosis* at percentages (33.9%), (17.8%), (12.6%), (23.2%) and (7.1%) as well as one sample (1.8%) revealed undifferentiated bacteria, the rest two samples (3.6%) don't show any bacterial growth during culture. In sheep the 23 samples the result showed that *Staphylococcus aureus* was predominant bacterial isolates followed by *Arcanobacterium pyogenes*, and *Corynebacterium pseudotuberculosis*, *S. epidermidis*, at percentages (30.4%), (26%), (21.7%) and (17.4%) as well as one sample (4.4%) didn't reveal any growth.

## Introduction

As subcutaneous abscesses are mostly infected by different species of zoonotic bacteria, hence they may be ruptured during the skinning process, and their bacterial load can contaminate the surface of the carcass. Therefore, consumption of this infected meat may have public hygienic importance<sup>(1)</sup>. Abscesses may also develop in internal body organs such as the lungs or liver, if the organisms enter the bloodstream<sup>(2)</sup>. Most subcutaneous abscesses result from traumatic skin penetration with resulting infection. For example facial subcutaneous abscesses are common in cattle eating roughage containing foxtail

grass (*Hordeum jubatum*). Several animals in a herd may be affected at one time, the awns of these plants migrate into the cheek mucosa, causing subcutaneous abscesses.<sup>(3)</sup> The *Corynebacterium*, *Staphylococcus*, *Streptococcus*, *Pasteurella* spp., *Escherichia coli*, and other gram-negative rods. *Peptostreptococcus anaerobius* and *Eubacterium tortuosum* were isolated in external and internal abscesses each in goats<sup>(4)</sup>. This study aimed to identify subcutaneous abscess clinically and isolation of their causative microorganism in Al-Qadisiya province.

## Materials and Method

Samples taken by inspiration the pus with sterile syringes with 17G needles, thick pus samples taken by dissected subcutaneous abscesses with sterile surgery blade and sampled by the sterile swabs. The samples were placed into sterile tubes containing Peptone

water medium. Then, it were cultured on Brain Heart Infusion Agar and Blood Agar plates. Finally, the media were incubated at 37 °C for 24h to 48h in aerobic and anaerobic conditions<sup>(4)</sup>. After incubation the appeared colonies were identified by routine

bacteriological techniques such as gram staining and biochemical tests (Catalase, Coagulase, Simmon citrate, Urease, Gelatin melting, Nitrate reduction, TSI, OF and Carbohydrate fermentation)<sup>(5)</sup>. API 20 SREPT system Biomerieux,

France, API Coryne system Biomerieux, then was applied for further identification technique. All subcutaneous abscesses treated surgically as open wound and injectable penicillin- streptomycin course<sup>(3)</sup>.

### Results and Discussion

The results were showed that distribution of subcutaneous abscesses depend on body anatomical location, in cattle, there are a great variety in sites of infection, in spite of most abscesses developed on head region (facial subcutaneous abscesses) which was most commonly affected, followed by neck and chest regions at percentages 80.36%, 8.92%, and 10.71% respectively, also in sheep the head was higher percentage

followed by (gluteal& neck )and chest regions at percentages 82.6%, 13.03%, and 4.34% respectively (table 1).Head abscesses in cattle located in the lower jaw (dewlap) , cheeks, and occasionally in the neck close to the head (image 1, 2, 4), whereas the predominant anatomical site of head abscession in sheep was lower jaw ( submandibular ),throat region (image 5,6, and 7).

Table -1:- showing percentages of distribution of subcutaneous abscesses at body sites in cattle and sheep.

region of affection	cattle		sheep	
	No.	%	No.	%
Head	45	80.36	18	82.6
Neck and chest	5	8.92	2	4.34
Gluteal region	6	10.71	3	13.03

Clinically, animals have a much greater proportion of abscesse in the head region, related possibly to superficial injury during browsing and the nature of grasser which have the high property of prickly plant, wound in the skin or oral mucosa may result from puncture by thorny vegetation <sup>(6)</sup> .An abscesses in other body location occur secondary for trauma as a result of fighting between animal, contamination of injection sites, and may be any injurious conditions. The organism gains access to the body through contaminated abrasions or wounds and the infection may remain localized in the form of a subcutaneous abscess with inflammation of the draining regional lymph nodes<sup>(7,8)</sup>.The results also demonstrated that there are four types of subcutaneous abscesses vary in form and

nature content depended on causative agent, but in general it are usually round, the size varying from a nutmeg fruit size up to a muskmelon, sometimes two or more are located very close:

❖ Hot, tension (but not hard ) and contain a watery large quantity and dark gray with gases which were odorous odder and slightly painful to animal. Animal have slight elevated temperature and inappetance(image. 6)

❖ Fluctuant abscesse, sometime with one to two draining sinuses, and exudation of purulent secretion containing whitish granules, predominantly odorless. An animal's were normal of vital signs except restlessness and pain at touching (image1,3 and 8).

❖ Firm (hard ) usually small and have very thickness surrounding skin,

abscesses content was little thick white and odorless pus, An animal was normal.

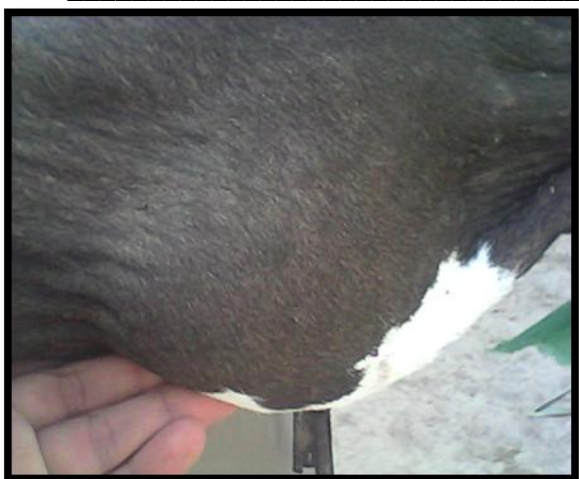❖ Diffuse abscess, small proportion of subcutaneous abscesses of sheep were of a more diffusive in nature, whose pus is diffused in the subcutaneous tissue, that diagnosed in leg, animals may have an increased temperature, loss of appetite and lethargy with lameness.

This results in agreement with<sup>(9)</sup> who showed and demonstrated the characteristic features of oedematous swellings in the dewlap, flank and other locations. The swelling may exceed the size of a water-melon. On cutting or puncturing, such swellings constantly release a serous bloody exudate. The results of study demonstrates that aerobic and facultative anaerobic bacteria could isolated from subcutaneous abscesses. out of 56 cattle abscesses samples there are 54 samples demonstrated gram positive bacteria only which presented by *Staphylococcus aureus*, *S. epidermidis*, *S. hycus*, *Arcanobacterium pyogenes*, *Corynebacterium pseudotuberculosis* and


undifferentiated bacteria at percentage (33.9%), (17.8%), (12.6%), (23.2%), (7.1%), and (1.8%) respectively. whereas the rest two samples (3.6%) don't showed any bacterial growth during culturing (table 2). The result of the isolated bacteria from subcutaneous abscesses of cattle are in agreement with<sup>(10)</sup> while disagree with the result of<sup>(5,7,11)</sup> who isolated *Pasteurella*, *E. coli*, *Klebsiella pneumonia* from subcutaneous abscesses of cattle, sheep and goat. Also in sheep the samples cultures revealed that *Staphylococcus aureus* was predominant bacterial isolated followed by *Arcanobacterium pyogenes*, and *Corynebacterium pseudotuberculosis S. epidermidis*, at percentage (30.4%), (26%), (21.7%), and (17.4%) respectively as well as one sample (4.4%) was negative in culturing (table 2). These bacterial were agreement with<sup>(2, 4,12)</sup>. The negative culture of 3 samples in our study may be return to the bacterial causes of this samples were steric anaerobic or required to special facilities.

Table(2) numbers and percentages of bacteria isolates from subcutaneous abscesses in cattle and sheep

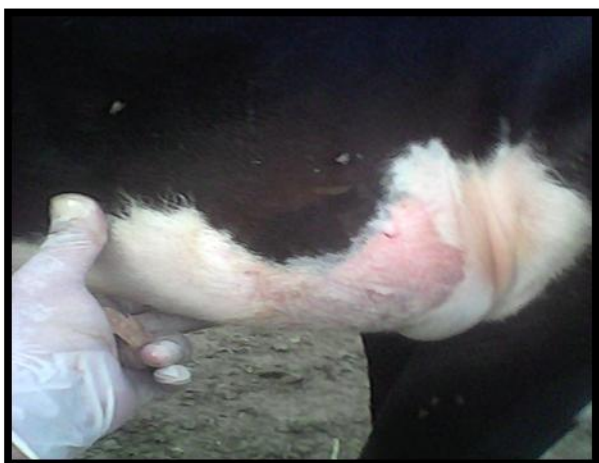Bacterial Isolates	Cattle		Sheep	
	No.	%	No.	%
<i>S. aureus</i>	19	33.9	7	30.4
<i>S. epidermidis</i>	10	17.8	4	17.4
<i>S. hycus</i>	7	12.6	–	–
<i>A. pyogenes</i>	13	23.2	6	26
<i>C. pseudotuberculosis</i>	4	7.1	5	21.7
Undifferentiated bacteria	1	1.8	–	–
No growth	2	3.6	1	4.4
Total	56		23	



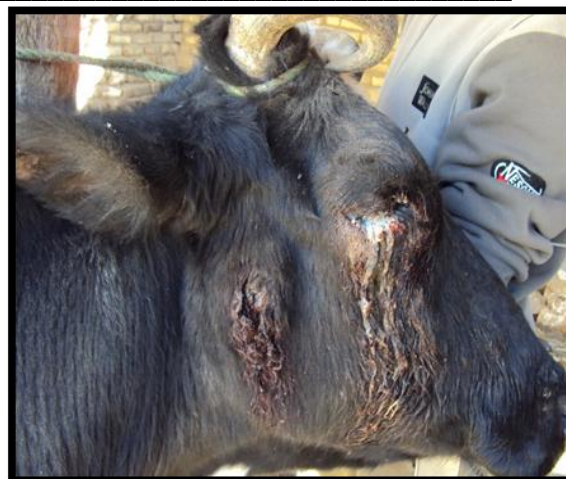( Image:1)large submandibular subcutaneous abscess in cow



( Image:2) subcutaneous abscesses in cheeks of cow



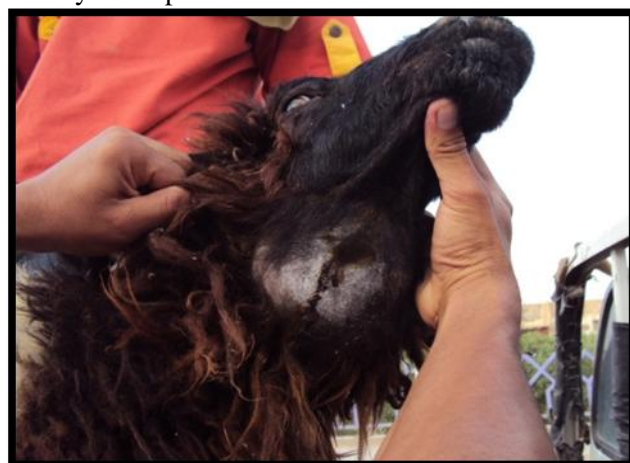(Image:3 ) large, tension subcutaneous abscess in subaxillary (above a thoracic ribs ) in cattle



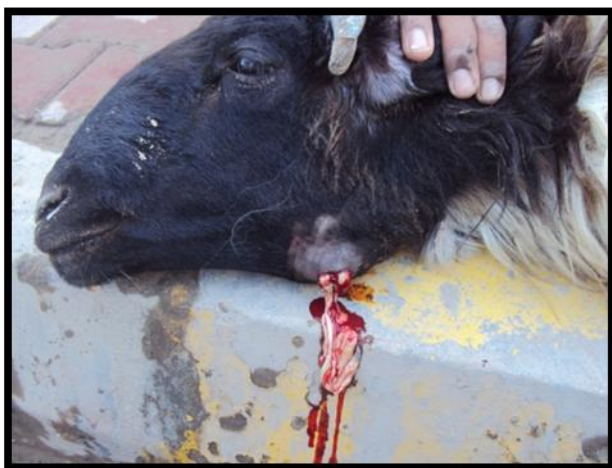(Image:4) ruptured subcutaneous abscess in cheek of cattle with affected eye by contamination with pus



( Image:5) subcutaneous abscess showing white creamy color pus in submandibular in Ram



(Image:6) ) large, tension subcutaneous abscess in larynx region, contain gases with black color and odorous odor pus



(Image:7) A ram affected with subcutaneous Abscess showing white creamy color pus in submandibular

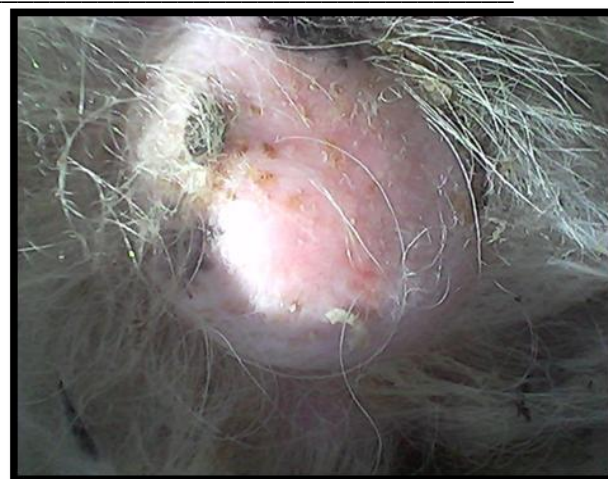

Image:8). subcutaneous abscess in the tail of Ram was contain thick dried pus

### References

- 1.Smith HW. (1971). Beta-lactams versus glycopeptides in treatment of subcutaneous abscesses infected with *Staphylococcus aureus*. *Adv Vet Sci Comp Med*. 15:67-100
- 2.Gezon H.M; Bither HD.; Hanson LA. And Thompson JK. (1991) Epizootic of external and internal abscesses in a large goat herd over a 16 – year period . *J. Am. Vet. Med. Assoc*. 15; 198: 257-63.
- 3.Radostits, O.M.; Gay, C.C.; Hinchcliff, K.W.; and Constable, P.D. (2007). *Veterinary Medicine, A Textbook of the Diseases of Cattle, Horses, Sheep, Pigs and Goats*. 10<sup>th</sup> ed. Elsevier Saunders, Spain.
- 4.Tadayon RA; Cheema; AH, Muhammed, (1980). Microorganisms associated with abscesses of sheep and goats in the south of Iran, *Am J Vet Res*. May;41:798-802.
- 5.Macfaddin, J.F. (2000):*Biochemical Test for Identification of Medical Bacteria* .3 Ed .William and Wilkins ,U.S.A Wood C A. and Wisniewski R M. (1989). The Use of a Microagglutination Assay for the Detection of Antibodies to *Corynebacterium pseudotuberculosis* in Naturally Infected Sheep and Goat Flocks *Can .J. Vet. Res*; 53: 313-318.
- 6.Mary,C.S.; David,M.S.(1994):*Goat Medicine*. Lippincott Williams & Wilkins (USA), pp (51).
- 7.Mosa, T.; Abbas, I.; Mohammad, Y. P.; Amir, T.; Hossein, T. (2010). Bacteria associated with subcutaneous abscesses of cattle caused by *hypoderma* spp larvae in north of Iran. *J.Vet Res. Forum*. 1: 123-127.
- 8.Stephen,J.E.; Edward, C.F. (2010): *Textbook of Internal Medicine*,7<sup>th</sup> ed., Saunders, Elsevier, Canada.
- 9.Barakat, A.A.; Selim S.A; Atef A.; Saber M.S.; Nafie E.K.; and El-Ebeedy A.A.(1984) :Two serotypes of *Corynebacterium pseudotuberculosis* isolated from different animal species *Rev. Sci. Tech. Off. Int. Epiz.*, 3, 151-163
10. Slee, KJ(1985)A microaerophilic coccus in pyogenic infections of ruminants.. *Aust.Vet.J.*;62:57-9.
11. Al-Harbi, K.B.(2011): Prevalence and Etiology of Abscess Disease of Sheep and Goats at Qassim Region, Saudi Arabia. *Vet. World*, 2011, Vol.4(11):495-499

12. Paula I.; Menzies and C. Anne Muckle Can. (1989) :The Use of a microagglutination assay for the detection of antibodies to

*Corynebacterium pseudotuberculosis* in naturally infected sheep and goat flocks, J. Vet. Res.; 53: 313-318.

## دراسة سريرية بكتيرية للخراجات التحت الجلدية المتسببة بواسطة جراثيم موجبه لصبغه الكرام بالأبقار والأغنام في محافظة القادسية

يحي إسماعيل خضير  
مسار إبراهيم شيخان  
كلية الطب البيطري/ جامعة القادسية  
الخلاصة

على الرغم من كون الخراجات التحت الجلدية تحدث بشكل حالات مفردة و بنسبة حدوث قليلة ، تم فحص 79 حاله موزعه 56 حاله أبقار و 23 حاله أغنام خلال الفترة من تشرين الثاني إلى تشرين الأول 2011 لتحديد نسب توزيع الإصابة تشريحيًا وكذلك عزل العوامل الجرثومية المسببة في الأبقار والأغنام في محافظة القادسية . أظهرت النتائج إن منطقه الرأس كانت الأكثر تعرضا للإصابة تلتها منطقه الأطراف الخلفية ثم منطقه العنق وبنسب تراوحت 80.36% و 8.92% و 10.71% على التوالي في الأبقار و 82.6% و 13.03% و 4.38% على التوالي في الأغنام. وبينت الدراسة وجود اربع اشكال سريرية تتباين في الحجم (من حجم ثمرة الجوز إلى حجم الشمام) وتباين في طبيعة مكوناتها اعتمادا على نوع المسبب. أظهرت نتائج العزل إن 54 عينة من الأبقار من مجموع 56 عينة من الأبقار كانت المسبب لها جراثيم موجبه لصبغه كرام وهي المكورات العنقودية الذهبية و المكورات العنقودية الجلدية و المكورات العنقودية هايكس ووتدييات الفيجية و الوتدييات السل الكاذبة بنسبه عزل 33.9% و 17.8% و 12.6% و 23.2% و 7.1% بالإضافة الى عزلة واحدة 1.8% لم يتم تحديدها وعينتين 3.6% لم تظهر اي نمو جرثومي خلال الزرع البكتيري. إما في الأغنام فقد أظهرت المكورات العنقودية الذهبية في 23 عينة تلتها الوتدييات الفيجية و الوتدييات السل الكاذبة و المكورات العنقودية الجلدية 30.4% و 26% و 21.7% و 17.4% بالإضافة إلى عزلة واحدة لم تظهر اي نمو جرثومي.