

Macroanatomical investigations on the oral cavity of male Porcupines (*Hystrix cristata*)

Walaa Fadil Obead¹, Abdularazzaq baqer kadhim², fatimha Swadi zghair²

¹Department of Anatomy and Histology, Faculty of Veterinary Medicine" University of Kerbala, Iraq.

²Division of Anatomy and Histology", Faculty of Veterinary Medicine" University of Al-Qadisiyah, Iraq.

Abstract:

"Six adult males hystrix crestate was utilizes to decide the district anatomy of their mouth. The mouth was the advent via disjunct the temporo-mandibular united and the topographically and Morphometric tagged of the tongue, cheek pouch, major salivary glands, palate, lips and teeth were studied. The upper flange discovered a philtrum rollover from "the median bulkhead of the nostrils and terminating at the oral chapping in a dissimilarity triangle to depiction the elongated incisors". The lower flange bent a smooth arch ventral to the upper flange. A standard number of jagged Palatine ridges are eight. Histological appearance of the tongue was confirmed after staining of the eosin and the haematoxylin. The parotid, the mandibular, and the sublingual are major salivary glands were well developed". This labor information baseline investigates data on the anatomy of the *Hystrix cristata* mouth and will have usefulness informative the adaptive appearance in this rodent to its lifestyle, habitat and diet.

Keyword: Oral cavity, Tongue, Salivary gland, Palate, *Hystrix crestate*.

INTRODUCTION

"Rodents include main and the majority varied collection of mammals through over 1700 dissimilar types (1). The porcupine accustoms to the Hystricidae relations form a little collection of the sort Rodentia. Even though some morphological monographs on the organs of the porcupine (2). Have been investigated .The major subdivisions of the digestive system are oral cavity, pharynx, esophagus, stomach, and intestine, associated with these structures are the accessory organs, principally mouth with the tongue, teeth, oral glands, pancreas, liver and the gallbladder" (3,4). The oral cavity is the first part of the alimentary canal. Its boundaries rostrally by the lips, continuous caudally and laterally with the cheeks and dorsally with the mylohyoid muscles. The exterior is covered with long hair either the inner part of the mucous lining is transferred to the mucous membrane of the mouth along the corner of the mouth to the caudal side of the pointed dental incisors (5).

In research facility rats, the upper lip is isolated midsagittally by a no-limit, lacking hair philtrum and the wrinkle is managed as an unlimited pocket roughly the neck of the unrivaled incisors and caudal as a wrinkle heading far towards the top of mouth" (6). "The cheeks frame the parallel outskirt of the oral hole, similar to the lips is made out of three layers "remotely secured by the skin, center layer strongly and inside mucous film lining". The cheek frames the horizontal outskirt of the oral cavity. It proceeds rostrally with the lips and has same layers as the lip. It additionally frames the cranial outskirt of the oral hole appropriate. "The top of the mouth is distanced into two sections hard and delicate sense of taste "The hard sense of taste has a short hard segment (7, 8). "The delicate sense of taste is long in rabbit and partitions the pharynx into oral and nasal segments with the last getting the opening of the Eustachian tube. Disgustingly, as of its dorsal and ventral compacted tilt to the epiglottis's base, the tongue was separated into three sections: the caudal division (root), the medially packed division (body) and the rostral division (summit). It's realistic a spatula created zenith more extensive cranially and decreasing down caudally pending about the caudal 33% as of which it had a predictable width which point, a raised dorsal prominence (torus linguae) was experiential on the dorsum. The cranial 2-3 of the dorsum exhausted a center lingual sulcus, and the root was settled in the hyoid bone (9) Epithelium covering of the tongue is keratinized stratified squamous epithelium. The substantial organs are the parotid, mandibular and

sublingual organs be inverse and fine urbanized." (9, 10). The aim of the study anatomy and histology of oral cavity of porcupian.

MATERIAL AND METHOD:

Six grown-up male porcupine was utilized for the study. The creatures were getting from confined seekers in diwanyiah. "The creatures are calmed with an i.m infusion of ketamine (35 mg/kg) and xylazine (5 mg/kg)" (11). The body weights are confirming in the adjoining kg. After anesthesia, the mouth was approach using disjoint the temporomandibular joined together. Typical saline is utilized as a part of canny the viscerated tissues to maintain the ordinary cadaver physiology.

The tongue was dissected out and then set in formalin concentrated 10% for 48h and next, dehydrated from side to side a climbing incline of alcohol in different concentrated (70%, 80%, 90%, 100%) 2hours".

"The tissues are then clear by use xylene, and put it in the paraffin wax at 58°C and cut it at 5 µm by a microtome apparatus. The embedded by paraffin sections were stained with H & E" (12).

RESULTS:

The mean weight of the *hystrix cristata* was 15045.0 ± 48.06 kg. The mean weight of tongue 19.98 ± 0.39 g while the mean of tongue length 20.15 ± 0.93 cm. The mean length of hard and soft palate 15.80 ± 0.47 cm. The mean weight of the parotid gland was 0.81 ± 0.03 g, mandibular gland was 1.68 ± 0.049 g, and sublingual gland was 1.47 ± 0.04 g while the mean of length of parotid gland was 2.47 ± 0.04 cm, mandibular gland was 2.76 ± 0.61 cm, and sublingual gland was 4.62 ± 0.14 cm (Table 1).

The upper lip (labium maxillae) was cleared by a deep fissure Philtrum. The lip covered with skin on the outside and mucous membrane inside (Fig.1).

The lip forms the rostral border of the mouth and is continuing with the gum caudally and the cheeks laterally. The caudal continuations of the cheeks formed a pouch with great elasticity and had same histological structures of the lips (Fig.2).

The oral cavity proper was formed by the gum rostrally, palate dorsally, the cheeks laterally and tongue (Fig.3). The hystrix cristata has a dental formula was (I 2/2, C 0/0, P 0/0 M 3/3) =20. Upper and lower incisors, and the upper and lower molar teeth were observed to be held up in the maxillary bone and the mandibular bones individually.

The upper incisor was long, curved and covered with the enamel on the outer surface, giving it a chisel-like edge with their labial and buccal surfaces being convex and concave, respectively (Fig.3). The division of palatum durum, connecting the incisive papilla and the medial surface of the first molar teeth limited two serrated crosswise running, Palatine ridge, rugae Palatina.

Between the two molar portico another six otherwise eight serrated configurations, lower rugae crosses the hard palate, enclosed with heavily cornified epithelium and their caudal edges eyed little-cornified papillae (Fig.4). The cheek pouches included anatomically of buccal and sublingual parts. The buccal part barred the mucosa of the cheeks medially and the medial face of the masseter muscle.

In this study, three salivary glands parotid, mandibular and The sublingual salivary gland were found. The parotid salivary gland was paired, non lobulated, elongated, canoe-like and was located ventral to the ear. It was also located dorsal to the mandibular salivary gland and cranial to the masseter muscle (Fig.5a,b).

The mandibular salivary gland was non lobulated, paired, roughly rounded shape and was located ventral to the parotid salivary gland. Disgustingly, as of its dorsoventrally compressed tilt to the epiglottis's base. The tongue consists from three parts body, apex and root.

It presented a spatula-shaped apex even about the caudal 1-3 from which it had a conjoined width, at which tip, dorsal eminence torus linguae (Fig.6) was experiential on the dorsum. The cranial 2-3 of the dorsum bore a median lingual sulcus, and the root is embedded in the hyoid bone.

The epithelial layer of the tongue was keratinized stratified squamous epithelium (Fig.7a) Lingual papillae, the mechanical and gustatory papillae be fair on the dorsal surface of the tongue. Filiform papillae cylinder projected on top of the surface of the tongue and enclosed the rostral part of the tongue Keratinised stratified squamous epithelium (Fig.8).

The caudal ending of the dorsal surface is free of mechanical papillae. All papillae appeared anatomically as pale dots. Fungiform papillae located at the apex and the dorsal surface of the prominence of the tongue irregularly scattered among the filiform papillae (Fig.9).

The epithelium enclosed taste buds incrustated a crux of the connective tissue inside each papilla Their connective tissue crux shaped finger similar to secondary processes and eyelet a generic conical hat of cornified epithelium. The vallate papillae be a few spread on the dorsum of the tongue solely rostral to the root. They seemingly as great planar structures that extend somewhat above the tongue surface (Fig10 a,b). Stratified squamous epithelium encased the surface of papilla and taste. Taste buds are additionally beginning at locales self-sufficiently of the unique gustatory organs inside the mouth and in the terminal parts of excretory conduits of the salivary organs" (Fig.7b).

DISCUSSION

Fodder metamorphoses are also overbalanced to be an answerable factor for the mass body cursor apart as of natural morphologies. Large index of the mastication apparatus and the mouth point to a larger surface region and naturalistic big jawbone muscles and larger categories gap which is requisite in fodder metamorphoses this agreement with (13,14). "The moderately larger body weight of males in all the samples calculated is in the bike to the finding of (18)who found the be alive weight of male giant rat to be elevated than females irrespective of the period.

"The relatively longer apical tongue (20.15 ± 0.93) in our deliberating, comparable to that of the Wistar rat (2.6 cm, 0.8 cm) can be mightily connected to relation differences in a dimension that's disagreement with (15). The tongue of the African giant rat likens that of the spatula configuration equine tongue (16) as the middle abate idealize the firmness of the molar teeth. The

cornified stratified squamous epithelium apart from the filiform and fungiform papillae of the tongue offends it from breakthrough mastication. It can cause rodent to obtain the benefit of coarse foods with abate. The comparatively little number of vallate papillae is an indicator that these rats connect meals with little taste identifiable that's acceptable with"(17).

Cheek pouch is accommodatively appearance for storeroom and carrying of a large quantity of feed for sign agreement with (18). This betokens that the celerity of gaining food is advanced in rodents with the pouches and be able to serve up a benefit in times of paucity. Though, the relationship of the pouch to composition like the pectoral muscle, salivary glands adduced a risk factor in fettles where acrimonious objects are naively chosen up as volume food.

The cheek pouches participate a necessary in the economizing of these rodents the pouches authorize individuals to xploit seed income professionally all through their home variety and go those seeds to sites anywhere the collector can put a forth greater degree of manage more than them Vander that's acceptable with (19). Dispossession to the larger size of the salivary glands of the hystrix crestate comparableness to those of the Wister rat, the porcupine is thus projected as an appropriate research replica for studying the pathogenesis of salivary gland tumours (20),

The macroscopic studies of the mouth present imminent into the adaptive morphology and mechanism by which the hystrix crestate accompanier and manipulate its food for suitable feed alteration to body accumulation. The conclusion deciding in this document, add to the body of information in the considerate of the anatomy of this rodent. Three salivary glands were observed namely the parotid, sublingual and mandibular salivary glands. The parotid salivary gland was located at the base of the ear, and ventral to it was the mandibular gland. The parotid salivary glands were observed to be non-lobulated while the mandibular salivary gland was lobulated. This finding was at variance with the observations of and (9) who documented four salivary glands in rabbit and laboratory rat (10).

The hystrix crestate was observed to have two incisor teeth and three molar teeth each in the upper and lower jaw with no canine and no premolar teeth. However, this was not the same observation at rabbit (10) and rat (18). The absence of the canine teeth gives rise to a diastema or stretch of the jaw which was devoid of teeth. The presence of the diastema may be suggestive of its dietary nature which allows room to maneuver the bulky food and to provide space for the cheek pouch. This observation is agreement with the observation of (10,18,20).

Table (1). Morphmetric parameters of body and oral cavity in adult porcupine. Data are given as mean \pm sem.

Parameter	Mean \pm SEM
Tongue Weight	19.98 \pm 0.39 g
Tongue length	20.15 \pm 0.93 cm
Length of hard and soft palate	15.80 \pm 0.47 cm
Weight of parotid gland	0.81 \pm 0.03 g
Weight of mandibular gland	1.68 \pm 0.049 g
Weight of sublingual gland	1.47 \pm 0.04 g
Length of parotid gland	2.47 \pm 0.04 cm
Length of mandibular gland	2.76 \pm 0.61cm
Length of sublingual gland	4.62 \pm 0.14 cm

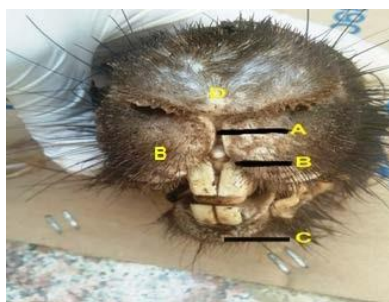


Fig1. Macrograph showing the: A-fissure of upper lip, B-upper lips ,C-lower lip ,D –nose.



Fig 2. Macrograph showing the extent of the cheek pouch.

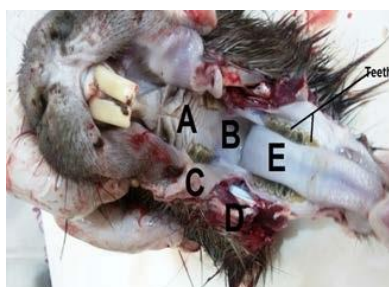

Fig 3. Macrograph showing the: A-hard palate, B-soft palate C- cheek D-gum E-tongue.

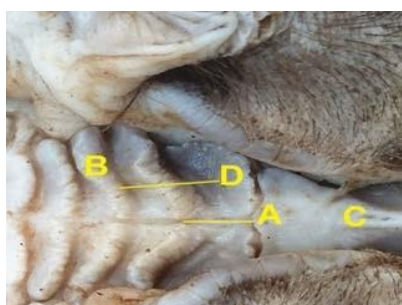


Fig 4. Macrograph showing the hard palate A-middle groove, B- rugae, C-incisive canal,D-cornified papilla.

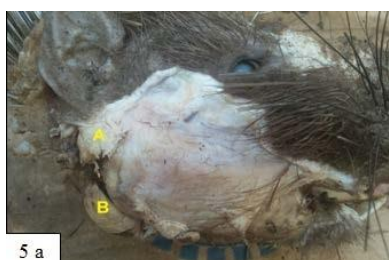

Fig 5 a. Macrograph showing the salivary gland A- parotid, B- mandibular.

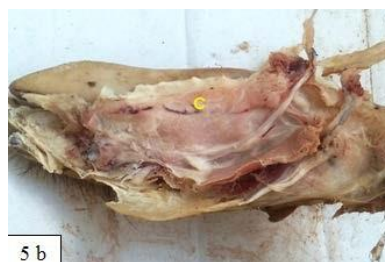

Fig 5 b. Macrograph showing the salivary Gland C- sublingual.

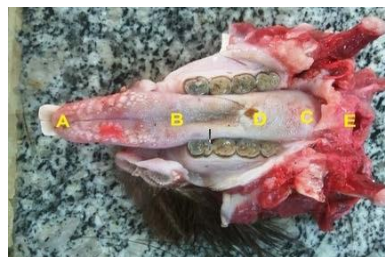

Fig 6. Macrograph showing the Tongue A-apex, B-body, C- root, D- torus lingue, E- epiglottis.

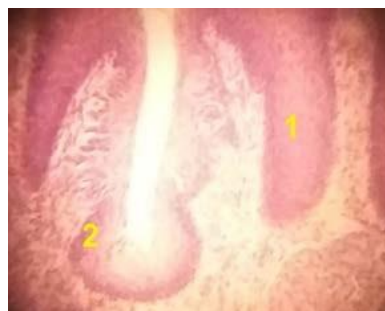

Fig 7a. Histological section showing the Tongue 1,2 keratinized stratified squamous epithelium (H&E 100x).

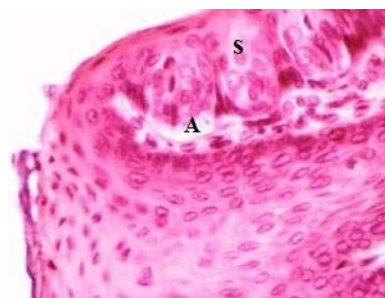

Fig 7b. Histological section showing taste bud a and s basal cells (H&E 100x).

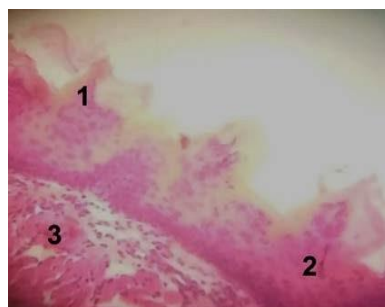


Fig 8. Histological section showing the Tongue 1- fileform papillae 2- keratinized stratified squamous epithelium 3- skeletal muscle (H&E 100x).

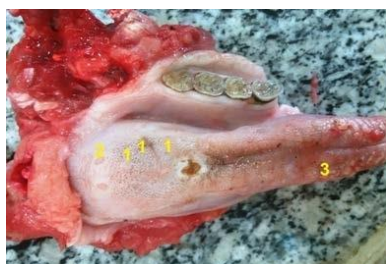

Fig 9. Macrograph showing the Tongue papillae 1-fungiform 2-circumvallet 3-filiform.

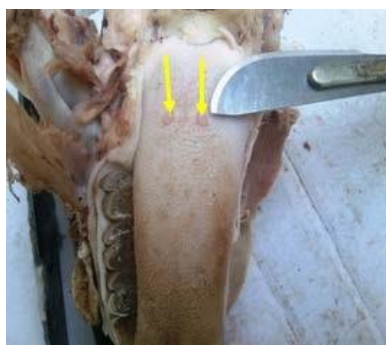

Fig 10 a. Macrograph showing the Circumvallet papillae

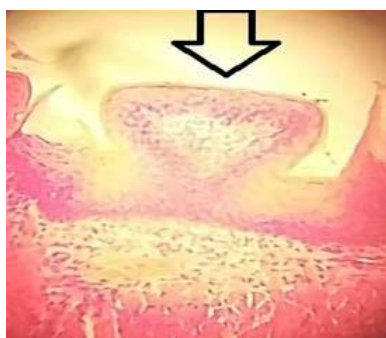

Fig 10 b. Histological section showing the Circumvallet papillae (H& E 400x).

REFERENCES

- Besselsen,D.G. (2002) Biology of Laboratory Rodents. Research Animal Methods, pp. 443 -453
- Asoje,T.A; Aire,T.A.(1986) Microstereological and Histochemical Studies of the Salivary Glands of the African Giant Rat (*Cricetomys gambianus*-Water House) *Acta Anatomica* , 117:65-72 .
- El-Sayyad,H.I.; Sabry, D.A.;Khalifa,S.A.; Abou-El-Naga,A.M. and Foda,Y.A. (2011) Studies on tongue of reptilian species *Psammophis sibilans*, *Tarentola annularis* and *Crocodylus niloticus*. *Int. J. Morph.*, 29(4):1139-1147.
- Dellmann, H. and Brown, E.M. (1987) Histology of the Digestive System. In Textbook of Veterinary Histology. Third edition. Lea and Febiger. pp. 229-247.
- George,C.K. (1973) The Digestive System. In Comparative Anatomy of the Vertebrate. 7th.pp.373-412.
- Rudolf, H. and Stromberg,M.W. (1976) The Digestive System. In Anatomy of Laboratory Rat. 7th edition, pp. 43 –51.
- Adeniyi,P.A.O; Owolabi,J.O.; Ghazal,O.K.; and Fatunke,I.D. (2010) A comparative histomorphology of tongue and dentition in rats,bats and hedgehogs. *Inter. J. of Biomed. and Heal. Sci.*, 6(3): 137-141.
- Stanbury, P. (1972) Lagomorphs: In Looking at Mammals. ELBS 3rd edition, pp.117
- Mustapha ,O.A; Ayoadei ,O.E; and Ogunbunmi,T.K. (2015) Morphology of oral cavity of the African giant rat *Bulgarian Journal of Veterinary Medicine* ,pp. 19-30
- Getty,R.(1975) Sissions and Grossman's. In Gross Anatomy of Domestic Animals: vols. I and II. 5th edition.pp 847-893 and 1232-1240 .
- Ivany,J.M. and Muir,W.W.(2004) Farm animal anesthesia. In Fubini, S.L.and Dusharme, N.G. (Eds.). Farm animal surgery. Saunders company.pp:97-112.
- Luna, L.G. (1968) Manual of histologic staining methods of the armed forces institute of pathology, 3rd ed. McGraw-Hill Inc., New York, USA, pp. 34, 35, 94, 95, 157-159, 162, 163.
- Wang,D. H.; Pei,Y.X.; Yang, J. C. and Wang, Z. (2002) Digestive tract morphology and food habits in six species of rodents: *Folia Zoologica*, 52, 51–55.
- Hebel,R. and Stromberg,M.(1976) Anatomy of the Laboratory Rat. The Wilkins and Wilkins Company, pp. 43–46.
- Sisson,S. and Grossman, J. D.(1953) The digestive system. In: The Anatomy of the Domestic Animals, 4th company Philadelphia and London, pp .392
- Atalar,O; Karan.M. (2011) The light Eletron microscopic structure of the papilla vallatae in the porcupine (*Hystrix cristata*). *J. Anim. Vet. Adv.* 10: 3080.3084.
- Nasr,E.S; Gamal,A.M; and Elsheikh,E.H.(2012) Light and scanning electron microscopic study of the dorsal lingual papillae of the rat *Arvicanthis niloticus* (Muridae, Rodentia). *J. Am. Sci. New York*, v. 8, n. 4, p. 619-627.
- Abayomi,T.A; Ofusori,D.A; Ayoka,O.A; and Odukoya,S.A. (2009) A Comparative Histological Study of the Tongue of Rat (*Rattus Norvegicus*),Bat (*Eidolon Helvum*) and Pangolin (*Manis Tricuspis*). *Int. J. Morphol.*, 27(4): 1111-1119.
- Scott,J.; Burns,J. and Flower,E.A.(1988) Histological analysis of parotid and submandibular glands in chronic alcohol abuse: A necropsy study. *Journal of Clinical Pathology*, 41, 837–840.
- Karan,M.; Yilmaz,S. and Aydin,A.(2010) Morphology of the Filiform Lingual Papillae in Porcupine(*Hystrix cristata*). *Anat. Histol. Embryol.*, 40: 100-103.