Ministry of Higher Education

And Scientific Research

University Of AL-Qadisiyah

Collage of Veterinary Medicine

Comparison Different Types Of Suturing Techniques Of Intestinal Surgical Intervention

A research submitted to

Veterinary medicine college/AL-Qadisiyah University,

It's partial of fulfillment to get B.Sc. in medical and surgery

Of Vet .Med.

By

Ahmed Mohammed Abd-Alkadhim

Lecture

Rafid H. Farman

2018A.D

1439A.H

جمهورية العراق

وزارة التعليم العالي والبحث العلمي

جامعة القادسية

كلية الطب البيطري

مقارنة انواع مختلفة من تقنيات الخياطة في التداخل الجراحي للأمعاء

بحث مقدم إلى

كلية الطب البيطري / جامعة القادسية وهي جزء من متطلبات نيل درجة الباكالوريوس في علوم الطب و الجراحة البيطرية

من قبل

احمد محمد عبد الكاظم

بأشراف

المدرس المساعد

رافد هادي فرمان

1439هـ **2018 م**

بِسۡمِ ٱللَّهِ ٱلرَّحۡمَٰنِ ٱلرَّحِيمِ

(فتعالى الله الملك الحق ولا تعجل بالقرآن من قبل أن يقضي أليك وحيه وقل رب زدني علما)

صدق الله العلي العظيم

سورة طه:من

الايه 114

Certificate of supervisor

I certify that Ahmed Mohammed Abd-Alkadhim has completed the fulfillment of her graduation project for the year 2017/2018 under my construction.

Supervisor

Rafid H. Farman

Certificate of instructor

We certify that Ahmed Mohammed Abd-Alkadhim has completed the fulfillment of her graduation project for the year 2017/2018 under my construction.

Dr. Muthana Hadi

Head of depart. Of Int& Prev. med.

الخلاصة

هدفت هذه الدراسة على تسليط الضوء على نوع الخيوط وتقنيات الخياطة التي تستعمل في التداخل الجراحي للأمعاء والتحقق من العوامل التي تحدد أي من تلك التقنيات الأحسن لخياطه الأمعاء .

أثبتت البحوث الحديثة ان تقنيه المشبك المعدني مناسبة اكثر مقارنة مع الخياطة التقليدية في الطب البيطري بسبب قصر الوقت المتبع في الخياطة ، تخريش اقل للأنسجة ، انخفاض معدل التلوث ومن ثم سرعة الشفاء وخصوصا في الأمعاء الغليظة ، لكنها تسبب تضيق خصوصا مع الأمعاء الصغيرة القطر مقارنة مع الخياطة التقليدية كذلك تحتاج معدات خاصة. من ناحيه أخرى كان هنالك أراء مختلفة من قبل الباحثين حول استعمال تقنيات الخياطة للأمعاء بصف واحد أو صفين لمنع تسرب محتويات الأمعاء خلال الشق الجراحي، فضل البعض منهم تقنية الصفين للخياطة لجعل الشق الجراحي اكثر قوة ولمنع التسريب بينما الأخرون اثبتوا ان صف واحد كافي لغلق الجرح مع افضليه قصر وقت الخياطة وتقليل التضيق الحاصل خصوصا مع الأمعاء ذات قطر تجويفي الصغير. الاستنتاج من هذه الدراسة ، ان كل أنواع وتقنيات الخياطة ممكن استعمالها مع بعض المحاسن والمساوئ. ان تقنية الخياطة التي يفضل استعمالها الجراح لخياطه الأمعاء تعتمد على اذا كان التداخل الجراحي فتح الأمعاء أو قطع جزء منها ومن ثم خياطته ، مكان العملية وقطر الأمعاء كذلك المواد المستعملة للخياطة .

Summary

This review aimed to highlight on the types of suture material and technique that using in intestinal surgical intervention and investigate the factors that determine which technique is best for intestine suturing.

The recent researches confirm that the clips technique are more suitable compared with conventional suture techniques in veterinary medicine, because short time, less irritant to tissue and lower infection rate then fast recovery specially with large intestine but its causes stenosis in small diameter intestine compared with conventional suture techniques, either need special equipment. Otherwise in suture mattress there were deferent opinions by researchers about using one or two row to suture the intestine to prevent the leakage of ingesta throw the incision, some researchers prefer two row of suturing to make an incision more strong and prevent leakage, while another researcher confirm that only one row enough to seal the incision with advantage of less time of suturing and little stenosis specially with small diameter of intestine lumen. The conclusions of this study, all The absorbable suture material and patterns are prefer to use with little advantage and disadvantage between them. The suture technique that surgeon prefer to use to suturing the intestine depend on if the intervention was enterotomy or Enteractomy, the site and the diameter of intestine type of suture material.

Introduction

2. Enterotomy.

It's make an opening in the wall of intestine to treat certain defect then suturing by several way, it's a dirty procedure that requires caution to prevent contamination which being the main cause of peritonitis. The enterotomy is closed with two rows of absorbable suture material. This method insuring less suture material in the peritoneal cavity and could reduce risk of adhesions to foreign material, so the adhesions are very rare in the large colon. An enterotomy might be required in the small colon to remove an impaction with food material or enterolith (Freeman, 2010a).

2.1. Enteractomy.

It's a cutting and removes part of intestine make to remove lesion from intestine then make an anastomosis of two ends by suturing of single row or by stapling

2.2. Complications of intestinal surgery.

There are many problems may accrue after intestinal surgery such as stenosis and may cause interception, volvulus or twisting, while in large intestine the defect like colon displacements, cecal impaction, large colon volvulus and enterocolitis may be happening. Surgery is the finest way to prevent these events. Mucosal damage after surgery due to persistent vascular occlusion and causes necrosis on the edge of incision and prevent anastomosis of intestine and escape of ingesta throw it, peritonitis and anastomotic outflow, abscessation, and death are more apposite complications, while adhesions and postoperative obstruction and stenosis are very rare, either the hemorrhage from the incision ends, which can leads to hemorrhagic shock. There is some substantiation that an enterotomy can increase the risk of postoperative incisional infections and other incisional problems in the body wall, because the high bacterial amount in the intestine which are increasing the probabilities of contamination to the edges of the body wall incision (Freeman, 2010b; White, 2010).

2.3. Suture materials use in intestinal surgery.

Suture is any material used to approximate the tissue ends and give supporting though the tissue healing. Suture materials divided into natural or synthetic, absorbable or non-absorbable. Each has a classic role when used correctly for wound closure techniques. Absorbable suture materials like chromic gut, polygalactin 910 (Vicryl) and polyglycolic acid (Dexon) are usually used in the viscera (Bright, 2009; Ellison, 2011). Absorbable sutures are designed to breakdown with the time then absorbed by the body. The aim of used to produce temporary support until the healing tissue will support itself. The ideal of this suture material will continue tensile strength until collagen replacement is complete and will remain non-reactive. Absorption occurs by hydrolysis in synthetic suture or phagocytosis and proteolysis in natural suture. (Boothe, 2003; Eyarefe and Amid, 2010).

Other type of Suture material used in intestinal surgery is staple; Stapling was use in surgical procedures early. Several methods of returning interrupted continuity of the large and small bowel are available to the surgeon (Weakley and Wilk, 1982). The healing of wound that suturing by stapling happening by primary intention with a minimal inflammation resulting and wound strength during the first week after surgery and established by an shortened or absent lag Period (Ballantyne *et.al.*, 1985).

Other advantage of this technique is shortened anesthesia and surgery time and reduced abdominal contamination. Titanium staples are used in most procedures, but absorbable staples are also available. Absorbable staples and specially designed equipment is used primarily in laparoscopic surgery. But the disadvantage of this technique is decrease the diameter especially in small intestine (Blackford and Blackford, 2006).

2.4. Suturing technique of intestinal surgery.

Many studies showing that submucosal opposition with direct approximation of wound edge can result in primary intestinal healing then fast healing because the submucosa was the strongest fragment of intestinal wall. Another advantages of are lumen diameter is not compromised, wound strength meets or exceeds everting or inverting wound strengths and adhesions are minimal. Unfortunate submucosal apposition result in healing by second intension with indirect bridging. Eversion or tissue overlap delays healing so should be avoided. Delayed fibrin seal formation

and mucosal re-epithelialization, increased mucocele formation, extended inflammatory response and marked adhesion formation all characterize everted healing. Everting anastomosis also has an increased predisposition for leakage and should never be used. Inversion of the wound edge produces an internal cuff of tissue that reduces lumen diameter. Hemodynamic compromise of the inverted submucosa occurs resulting in mucosal edema and necrosis. Inverting anastomosis are reflected by a quick serosa to serosa seal and minimal adhesion formation. Because of their safety against leakage, inverting patterns may be the favorite technique for the colon, while in small intestine is not favorite. Submucosal apposition is suitable with two - layers closure than with single – layer closure (Brown, 2003; Ellison, 2011).

There are many type of techniques that use in intestinal surgery:

1- Simple Continuous mattress suture:

This technique is easy to perform and uses can used to close the internal organ like intestine anastomosis (KOH, 2013). (Figure,1). Either performs a two-layer continuous suture closure for colon, bladder and bowel repair, and closure after myomectomy and hysterectomy (Sazhin, *et.al*, 2006; Yoo, 2008).

2- Lembert mattress suture:

A variation of the vertical mattress suture. Can be used as facial plication; closure interrupted or continuous pattern. Penetrates the hollow viscera submucosa but not the lumen of the bowel (Kumar, 2009) (Figure, 2).

3- Cushing mattress suture:

Penetrates the submucosa but not the lumen of the bowel. Closure of hollow viscera Provides less inversion than Lembert (Hendrickson, 2007) (Figure, 3).

4-Connell mattress suture:

Similar to Cushing except penetrates bowel lumen. Subject to first layer of closure for hollow viscera wicking of bowel contents, unlike Lembert, and Cushing (Blackford and Blackford, 2006) (Figure, 4).

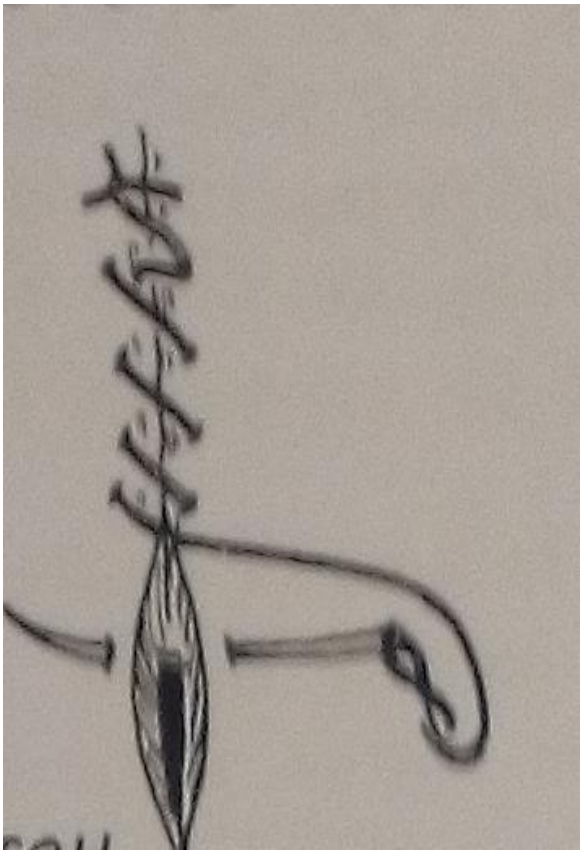



Fig. 1: Simple Continuous mattress suture Fig. 2: Lembert patterns suture technique.

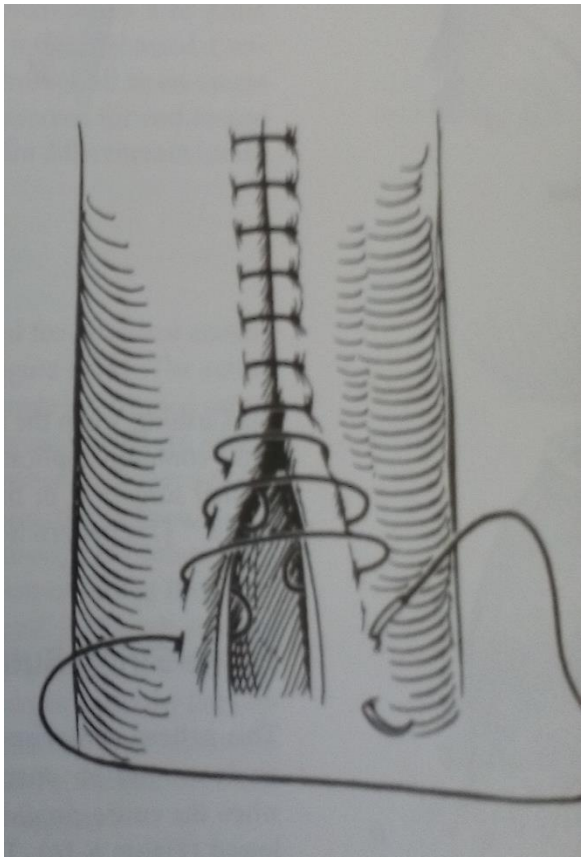

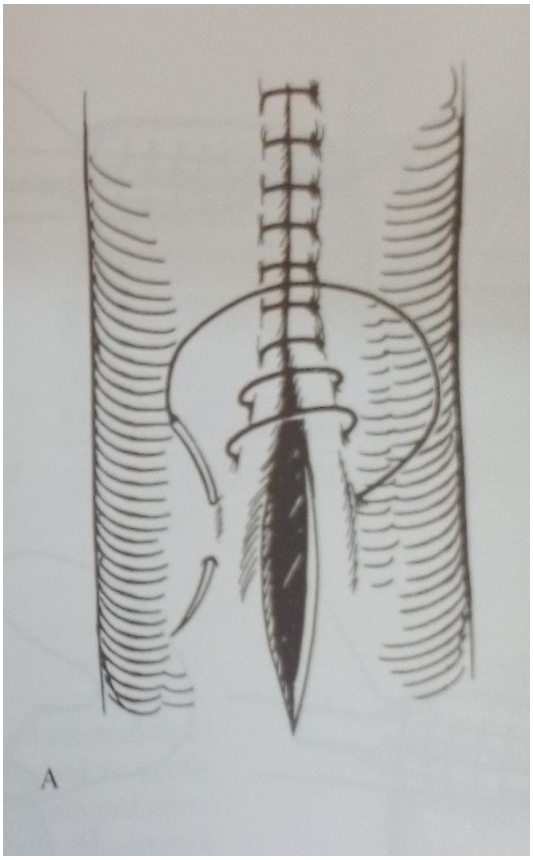

Fig.3: Cushing patterns suture technique. Fig.4: Connell patterns suture technique.

2.5. Comparative between hand suturing and mechanical stapling technique.

There are many factors can determine the type and way of technique that decided to using in intestinal suturing like the diameter of intestine , time and type of operation and the Bursting pressure on the site of operation. These factors could determine the type of material, sutures or clips and the way of suturing, single or double row to insuring there is no leakage from the site of operation.

There were no significant changes find in operation like length of hospital stay, and recurrence between the stapling and hand-sewn techniques. The differences just in the operation times in the stapling that is significantly shorter than those in the hand-sewn either between one and two row techniques (Hayashibe, 2013). Either stapled functional end to end anastomosis is associated with fewer leaks than hand suturing anastomosis (Choy *et. al*., 2011). While Hanson, *et.al*.,(1988) found that the suturing technique in small colon anastomosis was superior than the stapling technique because of significantly larger lumen diameters, better anastomotic healing, and minimal intra-viscera adhesion. Either tight stapling in ileocolostomy

had reduced suture line blood flow than the two-layered manual anastomosis (Chung, 1987).

Bowel anastomosis can be safely achieved using a suturing technique with a single row of sutures comparatively than a double row technique, however, relatively few authors use the single layer method as a standard technique (Crha *et. al.*, 2008; Lara and Tapanes, 2012; Rosenberg and Wara , 2012). Double-layers anastomosis consists of an internal layer of continuous or interrupted absorbable suture and an external layer of interrupted may absorbable or non-absorbable suture. This technique of single-layer was promoted because of reducing the operating time with decrease the inflammatory response and fibrosis are minimal and lower cost. While double row closure cause vascular necrosis of the inverted cuff of tissue which prolong the wound healing and increased intraluminal projection of tissues making the animal more predisposed to obstruction, and everting patterns increase the possibility adhesion between the edges of wound (Burch *et. al.*, 2000; Shikata *et. al.*, 2006).

Demarquay *et. al*., (2010) reported that colonic incision which were less than 10mm treated by suturing with hemoclips, while Raju, *et. al*., (2007) preformed that endoluminal closure of a 4cm colon perforation with clips was successful in the most of cases. Sutures were useful in the closure of gaping colon perforations that could not be closed with clips.

2.5.1.Stenosis Degree.

Inverting technique in suturing like Connells or Cushing patterns specially two row causes stenosis more than the everting technique like of intestinal suturing in ruminants(Singh *et.al.*, 1985) while Farman and Eesa,(2015) reported that stapling causes stenosis more than single layer suturing in colotomy of goats . (Figure, 20, 21).

Ibrahim (2010) in his study of colonic anastomosis found that inverting suture technique causes stenosis more than other techniques, this researcher disagree with(Edwards, 1986 and Hanson *et.al.*,1988), whom found that the suturing technique in colon anastomosis in horses was better than the stapling technique because of significantly larger lumen diameters, better anastomotic healing and minimal intra-abdominal adhesion formation.

On other hands (Dauod, 2007) proved that everting suturing causes more stenosis compared with other technique due to the Coup rims out of mucosa causes the increasing of inflammatory stage and more ischemia with tissue debris.

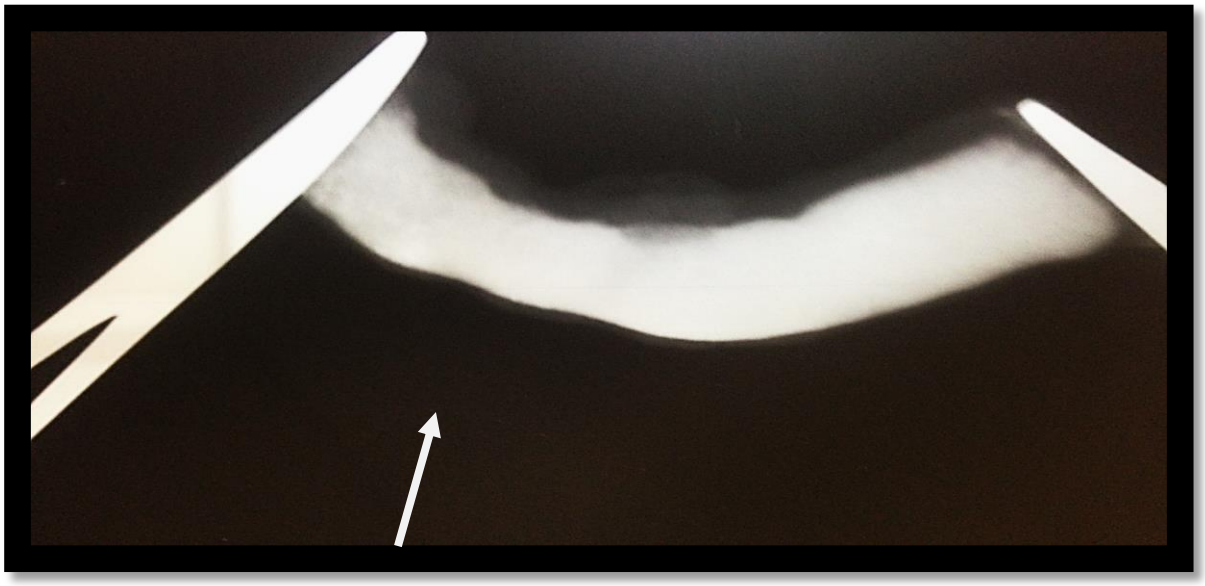

Figure, 5: Radiographic section show stenosis site of colon in Connells group. (Farman and Eesa, 2015).

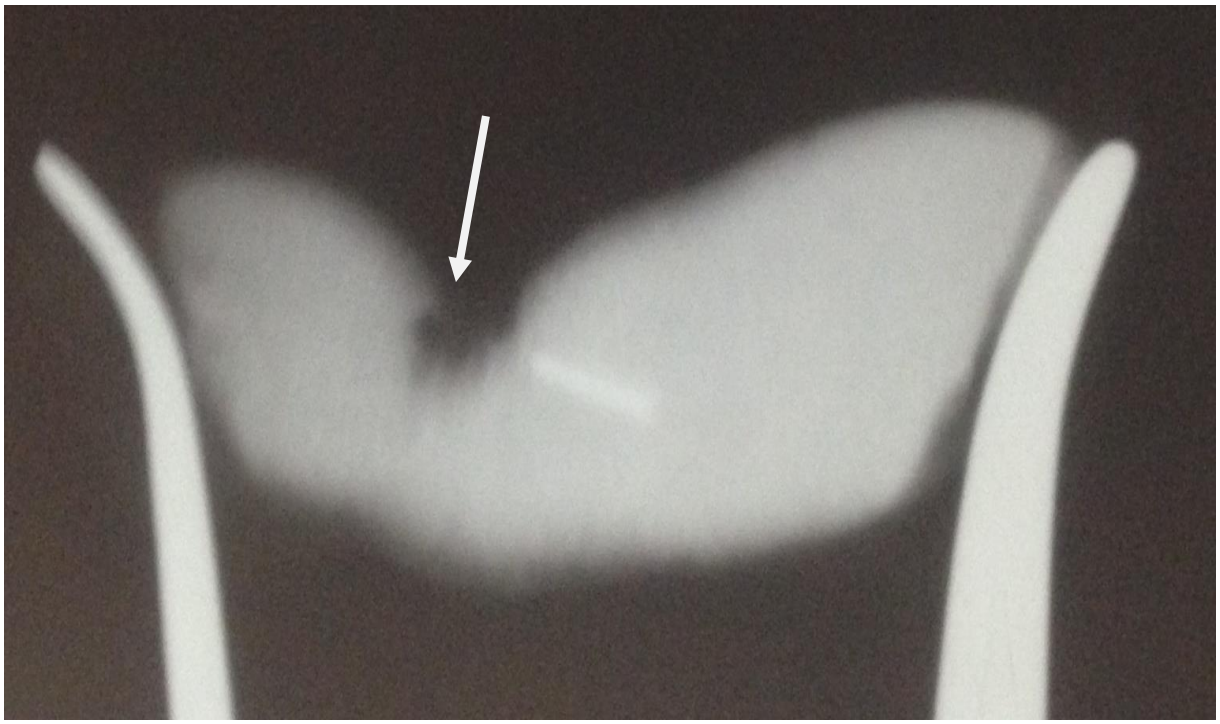

Figure, 6: Radiographic section show stenosis site of colon in clips group. (Farman and Eesa, 2015).

2.5.2. Bursting Pressure.

Other factor could determine which of techniques of suturing of intestine was pressure that depending on better adhesion and heeling of wound.

Many researcher found that the bursting pressure in inverting technique like Connells or Cushing was more than in clips technique in few days post-operative due to rapid adhesion between the two serosa in case of inverting suture together with acceleration of healing process , while in clips group the reduction in pressure may be due to approximated between two serosa that causes prolonging of inflammatory phase and decreasing in formation of collagen which response on the adhesion(Ellison, 2011;Dauod, 2007;Farman and Eesa,2015).

Conclusions

The conclusions of this study discovered that:

1- All absorbable suture material and patterns are prefer to use with little advantage and disadvantage between them.

2- The suture technique that surgeon prefer to use to suturing the intestine depend on if the intervention was enterotomy or enteractomy, the site and the diameter of intestine type of suture material.

References

Ballantyne, G.H.; Burke, J.B.; Rogers, G.; Lampert, E.G. and Boccia, J. (1985). Accelerated wound healing with stapled enteric suture lines. Annals Surg., 201(3):360–364.

Blackford, L.W. and Blackford, J.T.(2006) Suture Materials and Patterns.in: EQUINE SURGERY.3ed. Ch. 17 Pp.: 187-202

Boothe, H.W. (2003). Suture material, tissue adhesive, staplers and ligating clips. In Slatter, D. (ed.) Textbook of small animals surgery .Saunders Company .Pp. 235-243.

Bright, R.M. (2009). Intestinal surgery: Keeping it safe and. Proceeding of the Southern European Veterinary Conference (SEVC). www.ivis.org.

Brown, D.C. (2003). Small intestine. In Slatter, D.(ed.). Textbook of small animal's surgery .Saunders Company .Pp:646-650.

Burch, J.M.; Franciose , R.J. and Moore, E.E. (2000). Single-layer continuous versus two-layer interrupted intestinal anastomosis: A prospective randomized trial. Ann. Surg., 231:832-837.

Choy, P.Y.; Bissett, I.P.; Docherty, J.G.; Parry, B.R.; Merrie, A. and Fitzgerald, A. (2011). Stapled versus hand sewn methods for ileocolic anastomosis. Cochrane Database Systematic Rev., Vol.7,No.9.

Chung, R.S. (1987). Blood flow in colonic anastomoses. Effect of stapling and suturing. Ann. Surg., 206(3):335-339.

Crha, M.; Lorenzova, J.; Urbanova, L.; Fichtel, T. and Necas, A. (2008). Two techniques of intestinal wall suture in surgical treatment of ileus in dogs and the importance of omentalisation. Acta. Vet. Brno., 77: 263-267.

Dauod, M.S.(2007). A comparative study between two methods of intestinal anastomosis in goat. M.Sc. thesis college of Vet. Med., Baghdad University. Baghdad – Iraq.

Demarquay, J.F.; Perrin, H.; Hastier, P.; Higuero, T.; Ferrari, C.; Rampal, P. and Dumas, R.(2010). Large iatrogenic colonic perforation treated by endoscopic suturing. Gastroenterol Clinical Bio., 34(2):150-153.

Edward, G.B.(1986). Resection and anastomosis of small intestine: current methods applicable to the horse. Eq. Vet. J. 18:322-330.

Ellison, G.W. (2011). Reducing your complications with small animal surgery. Proceedings of the Southern European Vet. Conference(SEVC). www. Ivis. org.

Eyarefe, O.D. and Amid, S.A. (2010). Small bowel wall response to enterotomy closure with polypropylene and polyglactin 910 using simple interrupted suture pattern in rats. Int. J. Anim. Vet. Adv., 2(3): 72-75.

Farman R. H. and Eesa. M. J. (2015) Laparoscopic colotomy suture using clips and Connell techniques in goats: A comparative study. AL-Qadisiya Journal of Vet. Med. SciVol. 14 No. 1.

Freeman, D.(2010a). Complications in colic surgery and how to avoid them. Italian Association of Equine Vet. (SIVE), Pp: 100-105.

Freeman, D. (2010b). Challenge technique in colic surgery. Italian Association of Equine Veterinarians (SIVE), pp: 82-90.

Hanson, R.R.; Nixon, A.J.; Calderwood-Mays, M.; Gronwall, R. and Pendergast J.F.(1988). Comparison of staple and suture techniques for end-to-end anastomosis of the small colon in horses. Am. J. of Vet. Res., 49(9):1621-1628.

Hayashibe, A. (2013). The comparison of clinical results between hand suturing and mechanical stapling for gastrojejunostomy and jejunojejunostomy after SSPPD. International J. of Surg., 11(2):161-163.

Hendrickson, DA(2007) suture patterns in: techniques in large animal surgery .3ed. ch.6pp77-88.

Ibrahim, J.K.h.(2010). Acomparative study between cross mattress and schmiedens suture techniques on colon end- to- anastomosis in goats. M.Sc. thesis, Vet. Med. College. Baghdad University. Iraq. (unpublished).

KOH, C.H. (2013). Laparoscopic Suturing In The Vertical Zone. Endopress@t-online.de. P.P:2-20.

Kumar, A.(2009)suture and suture materials in: Veterinary surgical techniques. Ch4. Pp 59-73.

Lara, Y.V. and Tapanes, V.R. (2012). Single layer intestinal extramucosal suturing using two semi-continuous sutures in patients with abdominal surgery. Revista Cubana de Medicina Militar, 41(2):167-174 .

Raju, G.S.; Shibukawa, G.; Ahmed, I.; Brining, D.; Poussard, A.; Xiao, S.Y.; Coe, J.; Cropper, M.; Martin, D. and Hull, J.(2007). Endoluminal suturing may overcome the limitations of clip closure of a gaping wide colon perforation. Gastrointestinal Endoscopy, 65(6):906-911.

Rosenberg, J..and Wara, P. (2012). Bowel anastomosis can be safely performed using a suturing technique with a single layer instead of two layers. Ugeskr Laeger, 174(36):2071-2073.

Sazhin, V.P.; Gostkin, P.A.; Sazhin, A.V. and Siatkin, D.A.(2006). Laparoscopic Surgery of Colon Cancer. Khirurgiia (Mosk), (8):21-26.

Shikata, S.; Yamagishi, H. and Taji, Y. (2006). Single- versus two- layer intestinal anastomosis: a meta-analysis of randomized controlled trials. BMC. Surg., 6:2.

Singh, A.P.; Singh, G.R.; Bharagava, A.V. and Mogha, I.V. (1985). Comparison of six techniques of intestinal anastomosis in the bovine: An experimental study. Indian J. Animal sci. 55;905-911.

Weakley, F.L. and Wilk, P.J.(1982). Stapling in intestinal surgery. South Med J., 75(11):1318-1323.

White, R.N.(2010). Complications of gastro-intestinal surgery. International Congress of the Italian Association of Companion Animal Veterinarians(SCIVAC), pp:251-252.

Yoo, J. (2008). Laparoscopic Colorectal Surgery. The Permanente J., 12(1

):27-31.