

## Original Research Article

# Histopathological evaluation of focal ischemic brain damage as a result of acute ruminal lactic acidosis in lambs

Qassim Haleem Kshash<sup>1</sup>, Asaad Jassim<sup>1</sup> and Afaf Abdulrahman Yousif<sup>2\*</sup>

<sup>1</sup>College of Veterinary Medicine/Al Qadissiya University; Iraq

<sup>2</sup>College of Veterinary Medicine, Department of Preventive and Internal Veterinary Medicine/Baghdad University, Iraq

\*Corresponding author

## ABSTRACT

Lactic acidosis is a physiological condition characterized by low pH in body tissues and blood (acidosis) accompanied by the buildup of lactate, especially D-lactate, and is considered a distinct form of metabolic acidosis. The current study was conducted to evaluate the histopathological changes in brain that occur due to increased levels of lactic acid after experimentally induced acute ruminal acidosis in lambs. Eight clinically healthy young lambs (6-8 months) (Awassi), with average weight of  $30.2 \pm 2.25$  kg were selected for this study. These eight young lambs are equally subdivided into two groups: treated group (4) animals and control group (4) animals. Acute Ruminal acidosis was induced intraruminal intubation of 15g /kg BW sucrose via stomach tube. Prior to the infusion of sucrose (0 time), samples from rumen content were obtained to immediate determine normal pH values. Samples of rumen fluid were collected after 12 h of the infusion of sucrose. Clinical manifestation were notice on affected animals and then the histopathological biopsies were taken after 24 hours from three animals of treated group to study the morphological alterations that occur due to acute acidosis. The clinical signs that appears on animals immediately after induction of ruminal acidosis are depression, granting teeth, congestion of conjunctiva, some loss their appetite, while some others preferred roughage diet, salivation, urine retention, ataxia and difficult in gait(laminitis), and some of animals suffering from profuse pasty or watery diarrhea. Mean ruminal PH changed rapidly over the first 12 hours of ruminal lactic acidosis ( $4.31 \pm 0.41$ ). The histopathological alteration in the brain of lambs were obvious subdural hematoma and perivascular and pericellular edema with perivascular cuffing of inflammatory cells as well as multifocal subdural hemorrhage and thrombi. This study revealed a different pathological changes in the brain of lambs with lactic acidosis.

### Keywords

Ischemic brain damage; acute ruminal acidosis; lambs.

## Introduction

D-Lactate is normally present in the blood of mammals at nanomolar concentrations due to methylglyoxal metabolism; millimolar

d-lactate concentrations can arise due to excess gastrointestinal microbial production. Grain overload in ruminants,

short-bowel syndrome in humans, and diarrhea in calves can all result in profound d-lactic acidemia, with remarkably similar neurological manifestations (Ewaschuk *et al.*, 2005). With *acute* acidosis, ruminal acidity and osmolality increase markedly as acids and glucose accumulate; these can damage the ruminal and intestinal wall, decrease blood pH, and cause dehydration that proves fatal. Polioencephalomalacia, liver abscesses, and Laminitis often accompany acidosis (Enemark, 2008).

## Materials and Methods

Eight clinically healthy young lambs (6-8 months) (Awassi), with average weight of  $30.2 \pm 2.25$  kg were selected for this study. These eight young lambs are equally subdivided into two groups: treated group (4) animals and control group (4) animals. There were no any parasitic infections in animals. All of the experiment animals were kept for three weeks under the same condition for adaptation to the new environment, with feeding on alpha-alpha grass. Acute Ruminal acidosis was induced by intraruminal intubation of 15g/kg BW sucrose via stomach tube (Slyter, 1976). Prior to the infusion of sucrose (0 time), samples from rumen content were obtained using stomach tube provide with vacuum pump and its pH was measured immediately to determine normal values (pH meter, Germany) were collected after 12 h of the infusion of sucrose.

Clinical manifestations were notice on affected animals and then the histopathological biopsies were taken after 24 hours from three animals of treated group to study the morphological alterations those occur due to acute ruminal acidosis. Routine histopathological process was performed

to obtain slides stained with haematoxylin and eosin (H&E) for histological evaluation (Bancroft *et al.*, 1994). To assess differences between the control (hour zero) and induction of acidosis, T-test was performed for analysis of data and probability of  $P < 0.05$  were considered to be statistically significant.

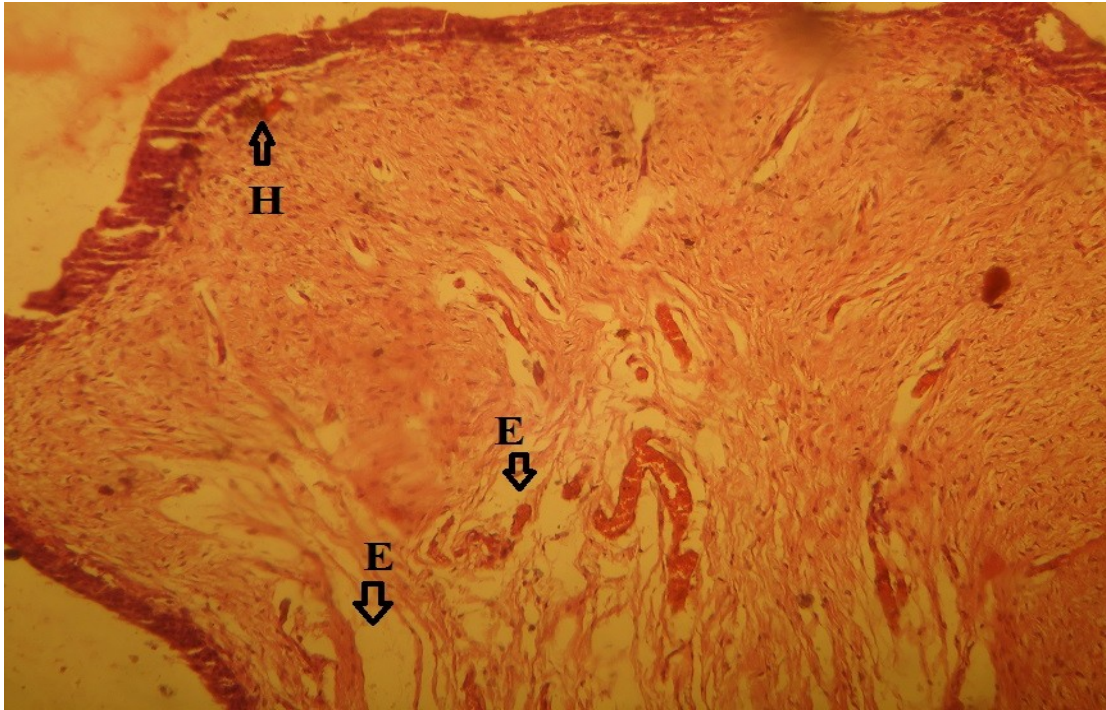
## Ethical approval

This study was approved by the ethical and research committee of Veterinary Medicine College/University of Al-Qadesia.

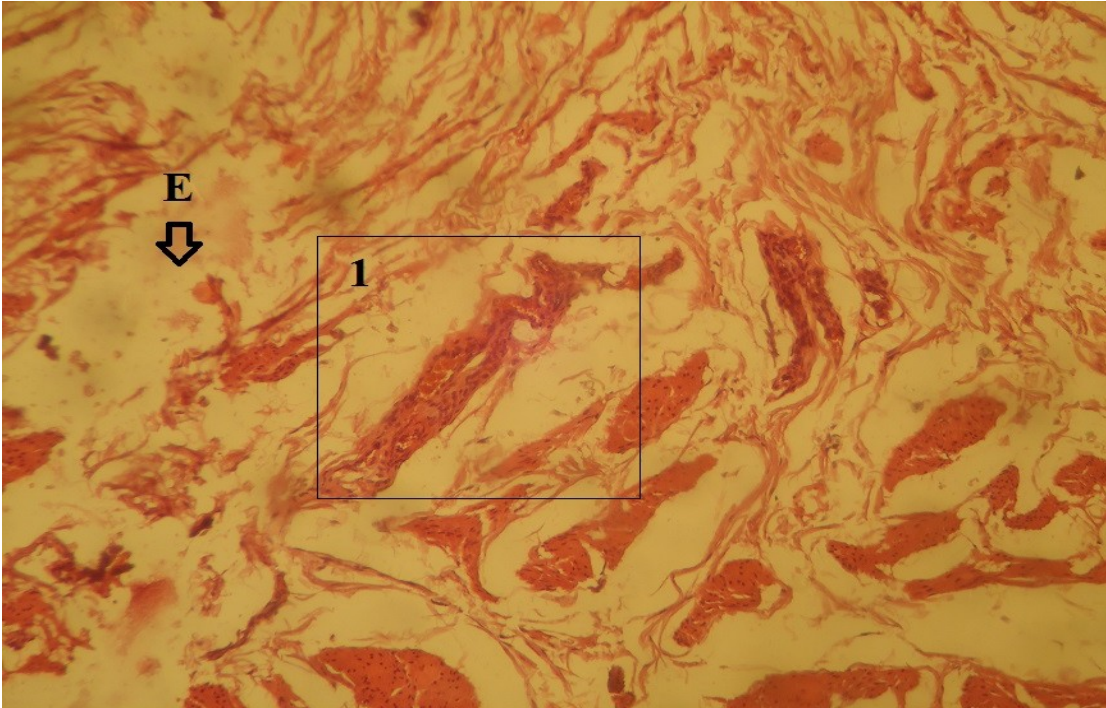
## Results and Discussion

The clinical signs that appears on animals immediately after induction of ruminal acidosis are depression, grinding teeth, congestion of conjunctiva, some loss their appetite, while some others preferred roughage diet, salivation, urine retention, ataxia and difficult in gait(laminitis), and some of animals suffering from profuse pasty or watery diarrhea. Mean ruminal pH changed rapidly over the first 12 h of ruminal lactic acidosis ( $4.31 \pm 0.41$ ).

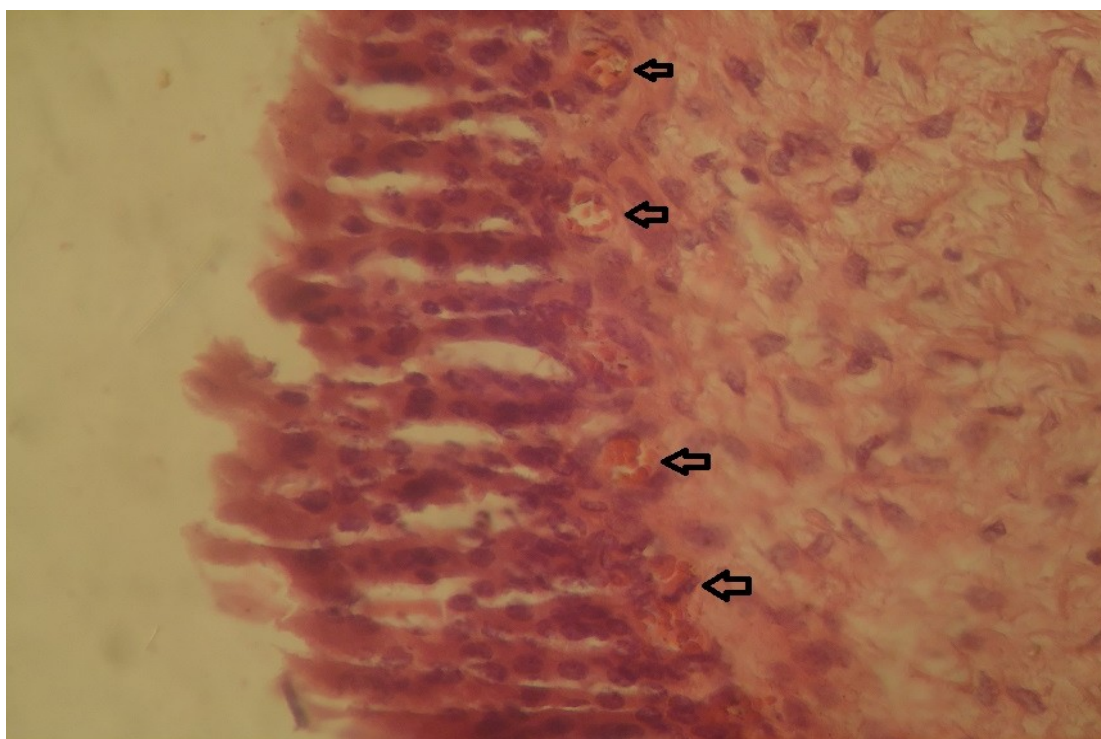
This results were in accordance with (Nikolov, 1998) that revealed that after treatment of the experimental group with 20 ml/kg body mass molasses, decreased rumen pH and the increased serum and rumen lactate concentrations occur progressively in parallel with the severity of disease. Metabolic acidosis in mammalian organisms occurs due to accumulation of D-lactate isomer in blood following absorption from the rumen because there was no specific mechanism for the metabolisation of D-lactate (Gentile *et al.*, 2002).



**Figure.1** section of brain characterized by subdural hematoma (H) with pericellular and perivascular edema (E). H&E, 100X.



**Figure.2** section of brain characterized by edema and perivascular cuffing of inflammatory cells (1). H&E, 100X.



**Figure.3** section of brain characterized by multifocal subdural hemorrhage and thrombosis (arrows). H&E, 100X

Changing ruminal pH by fermentation large amount of easily digested carbohydrates that occur rapidly and result in formation of greater amount of lactate and propionate simultaneously with decrease in acetate and butyrate concentrations (Nikolov, 1998). This led to multiplies *S. bovis* until ruminal pH is less than 5.0, a pH that allows an increase in *Lactobacillus* growth. Both of these bacterial species produce D and L-lactic acid. D-lactate and L-lactate will absorb across the rumen wall and the consequence is decrease blood pH. As L-lactate is metabolized more rapidly than D-lactate, the metabolic acidosis is due in large part to the accumulation of the latter (Bolton and Pass, 1988). The toxic metabolites resorbed in blood from the rumen impaired all parenchymal tissues (liver, heart, brain etc.) (Raundhawa, 1987). The histopathological alteration in the brain of sheep that suffering from

experimentally induced lactic acidosis were showed obvious subdural hematoma and perivascular and pericellular edema (figure 1) with perivascular cuffing of inflammatory cells (figure 2) as well as multifocal subdural hemorrhage and thrombi (figure 3). Some of our results were in accordance with these revealed by (Evans *et al.*, 1976) that discover presence of pronounced edemas and hyperaemia in the meninges (pia mater), and brain as well as perivascular and pericellular edema in the brain, while he didn't indicate to perivascular cuffing of inflammatory cells as we mentioned. Other studies (Dshurov, 1976) revealed that injection of sucrose and consequent hypercapnia and then hypoxia caused an increase in cerebral vascular permeability to sucrose in foetal and new-born sheep.

Severe newborn encephalopathy and respiratory complications were recorded

by (Low *et al.*, 1997) that occur as threshold of metabolic acidosis during delivery. Hyperglycemia, intra and extracellular acidosis one causes of ischemia or hypoxia and consequent brain damage and when ischemia is complicated by excessive acidosis, the ischemic damage encompasses post-ischemic seizures, edema, and pannecrosis. Hemorrhagic infarction and cerebral hematoma are feared events that may follow cerebral ischemia (Lyden and Zivin 1993). The cellular and molecular mechanisms responsible for these alterations have not been adequately defined. But, the acidosis may causes damage to inhibitory GABAergic cells by raising  $Ca_i^{2+}$  to levels, which will overload the buffering systems and cause cell death (Siesjö *et al.*, 1993).

## References

- Bancroft, J. D., Cook, H. C. & Stiling, R. W. 1994. Manual of Histological Techniques and their Diagnostic Application, 3rd edn. New York: Churchill Livingstone
- Bolton, J. R. and Pass, D. A. 1988. The alimentary tract. Clinicopathologic principles for veterinary medicine. W. F. Robinson and C. R. R. Huxtable. Cambridge, Cambridge University Press.UK: 99-121.
- Dshurov, A. 1976. The effect of hypercapnia on a blood-brain barrier mechanism in foetal and new-born sheep. J.Physiol. 255(3):701-14.
- Enemark, J.M.D. 2008. The monitoring, prevention and treatment of sub-acute ruminal acidosis (SARA): A review. Vet. J.176: 32-43.
- Evans, C.A.; Reynolds, J.M.; Reynolds, M.L. and Saunders, N.R. 1976. Pathomorphologic changes in the ruminal acidosis of sheep. Arch. Exp. Veterinarmed. 30(6):881-7.
- Ewaschuk, J. B.; Naylor, J. M. and Zello, G. A. 2005. D-Lactate in Human and Ruminant Metabolism. J. Nutr. 135 (7): 1619-1625.
- Gentile, A.; Sconza, S. and Lorenz, I. 2002. D-lactic metabolic acidosis in calves as a consequence of experimentally induced ruminal acidosis. Abstracts XXII World Buiatrics Congress, 175.
- Low, J. A.; Lindsay, B.G. and Derrick, E.J. 1997. Threshold of metabolic acidosis associated with newborn complications. Am J Obstet Gynecol. 177(6):1391-4.
- Lyden, P.D. and Zivin, J.A. 1993. Hemorrhagic transformation after cerebral ischemia: mechanisms and incidence. Cerebrovasc Brain Metab Rev. 5(1):1-16.
- Nikolov, Y. 1998. Clinical experimental studies on acute rumen acidosis in buffaloes (*Bubalus bubalis* L.). V. Influence on several blood and rumen biochemical parameters. VET. ARHIV. 68 (6): 205-212.
- Nikolov, Y. 1998. Clinical experimental studies in acute rumen acidosis in buffaloes (*Bubalus bubalis* L.). IV. Influence of acidosis on blood, rumen liquid and urine electrolytes. Vet. Arhiv. 68: 1-9.
- RaundhawA, S. S. 1987. Evidence of toxic factors in the rumen liquor of healthy and acidotic buffalo calves. Acta Vet. 56: 455-464.
- Siesjö, B. Katsura, K.; Mellergård, P.; Ekholm, A.; Lundgren, J. and Smith, M.1993. Neurobiology of Ischemic Brain Damage; Chapter : Acidosis-related brain damage. Elsevier B.V. 96:1-26.
- Slyter ,L.L 1976 Influence of acidosis on rumen function. J. Anim. Sci.43:910-929.