

# Grossly and Microscopic Study of the Primary Bronchi and Lungs of Wood Pigeon (*Columba palumbus*)

Saffia Kareem Wally Alumeri\*

Nabeel Abd Murad Al-Mamoori\*\*

Abdulla aad Hadi Al-Bishtue\*\*\*

\*, \*\* College of Veterinary Medicine, AL- Qadissiya University

\*\*\* College of Veterinary Medicine, Kufa University

## Abstract:

The present study included ten specimens of adult pigeon wood (*Columba palumbus*) collected from market of Al-Diwanyia city, divided the specimens into two groups five specimens for grossly study and five specimens for histological study. Opened the birds and extracted the right and left bronchi and left and right lungs for the purpose of grossly and histological studies. The study included grossly study for external bronchi. The total length of left bronchi was (  $0.7 \pm 0.1$  cm ) and right bronchi was (  $0.65 \pm 0.05$  cm ) and the basic structure of bronchi was the cartilage has – C – shape, also determine relationship bronchi with the neighboring organs. The grossly study involved the lungs right and left, it is found that the lung has two surfaces ( Costal and Visceral ) and two ends ( Distal and Proximal ) also detected relation to organs nearby, found that the average length of the right lung was (  $2.8 \pm 0$  cm ) while left lung was (  $2.75 \pm 0.05$  cm ) and average width of right lung was (  $2.45 \pm 0.65$  cm ) while the left lung was (  $2.7 \pm 0.7$  cm ).

The histological study involves the histological description of external and internal bronchi of the lungs and histological description of the left and right lungs.

**Keyword:** Primary bronchi, Lung, Wood pigeon, Grossly, Microscopic.

## دراسات عيانية, ومجهرية للقصبات الأولية ولرئتي حمام الغابة البالغ (*Columba domestica*)

صفية كريم والي العمري\*  
نبيل عبد مراد المعموري\*\*  
عبد الله عايد هادي البوشتيوي\*\*\*

\*, \*\* كلية الطب البيطري، جامعة القادسية  
\*\*\* كلية الطب البيطري، جامعة الكوفة

## الخلاصة:

شملت الدراسة الحالية عشرة عينات من حمام الغابة (*Columba palumbus*) جمعت من أسواق مدينة الديوانية وقسمت العينات إلى مجموعتين خمسة عينات للدراسة العيانية وخمسة عينات للدراسة النسجية. شرحت الطيور واستخرجت القصبات الخارجية والرئتين اليمنى واليسرى لغرض الدراستين العيانية والانسجية. تضمنت الدراسة دراسة عيانية للقصبات الخارجية وبلغ طول القصبة اليسرى (  $0.7 \pm 0.1$  cm ) بينما القصبة اليمنى

كانت (  $0.65 \pm 0.05$  cm ) ، أن الوحدة البنائية للقصبات الأولية هي الغضاريف الزجاجية على شكل حرف - C- وعلاقتها مع الأعضاء المجاورة كما شملت الدراسة الرئتين اليمنى واليسرى ووجد أن الرئة تملك سطحين ( ضلعي و حشوي ) ونهايتين ( قاصية و دائية ) وعلاقتها بالأعضاء المجاورة ووجد أن معدل متوسط طول الرئة اليمنى كان (  $2.8 \pm 0$  cm ) بينما الرئة اليسرى (  $2.75 \pm 0.05$  cm ) ومعدل متوسط عرض الرئة اليمنى كان (  $2.45 \pm 0.65$  cm ) بينما الرئة اليسرى (  $2.7 \pm 0.7$  cm ) .

تناولت الدراسة النسجية الوصف النسجي للقصبات خارج وداخل الرئتين والوصف النسجي للرئتين اليمنى واليسرى.

## Introduction:

The respiratory organs of birds differ from mammals due to specific structures includes nasal cavity, larynx, trachea, syrinx, bronchi, lungs and sacs (1; 2 and 3), while in mammals the respiratory system includes nostrils, nasal cavity, larynx, trachea, bronchi, lungs and absence of syrinx and sacs (4). The respiratory system plays a vital role in thermo-regulation, the sense of smell, and voice are associated with it ( 5; 6 and 7).

The primary bronchi consist of cartilaginous rings held together by connective tissues. They extend from the tracheal bifurcation to the hilus of the lungs. The lungs is bright red and very small in comparison to the size of the thorax. Each lung is adhered to the ribs and have the shape of a trapezium in African Guinea Fowl (8) While (9) describe the lungs of the duck as bright red-triangular or quadrilateral-shape, not divided into lobes, and has in the upper border several rows of grooves caused by embedded the vertebral ribs.

In birds the trachea bifurcation at the syrinx to the right and left primary bronchi, both enter the target lungs via the hilus at septal surface as an primary bronchus (10; 11; 12; 13 and 14).

The basic structure of primary bronchi was consist of series -C- shape of cartilage rings connect together by annular ligaments and the distance between the rings cartilage differ according to bird species. The secondary bronchi originate from primary bronchi at dissimilar position with variable number, and named according to the parts of the lung which they supplies (15; 16; 17; 18; 19; 20; 21; 22; 23; 24 and 25).

In avian the lungs is specialized organ and differ from other organs by extension during the mechanisms for ventilation (23). The lung was firmly attachment to the ribs that leaves deep costal impressions. (25 and 26)

The lung of birds are unlobuled and deeply imprinted by the thoracic vertebra the primary bronchus pass through the lung and it is caudal border is continuous with abdominal air sac ( 27; 28 and 29).

**The aim of study:** Design this study to providing anatomical and histological information and data about adult pigeon wood (*Columba palumbus*).

## Materials and Methods:

Ten adult wood pigeons collected from Al-Diwanyia city markets in above first year of their age used for this study. The Wood Pigeon was deeply anesthetized by intramuscular administration of diazepam (1 mg/kg) and ketamine HCl (30 mg/kg) combination (30), after that open the chest to make bleeding by puncture of the heart to get full hemorrhage and then wash the specimen with tap water to get rid of the impurities that may be present during the process of opening the chest and then record the specifications of the primary bronchi and lungs and its relationship with the

neighboring organs. Separates the lungs and bronchi to recorded macroscopic measurements, Finally reservation samples textured formalin (10% concentration) to make microscopic slides examined under a microscope.

In addition, by using the subsequently instruments (ruler, vernier, and amplifier lens (X6 and X12), the grossly study includes the following:

- 1-Length of primary bronchi.
- 2- Length and width of left and right lungs.

### **Results:**

The grossly examination of the primary bronchi and lung of Wood pigeon was located inside box the ribs of thoracic cavity (Fig. 1 and 2 ). Bronchi appeared as short tubes extend caudally from the syrinx to the hilus of the lung at the proximal third of the lung at the visceral surface. The bronchi laterally was against ascending ,descending aorta and interior and inferior vena cava and partially at region attachment of hilus of lung covered with base of heart while ventrally was opposite the esophagus and proximal part of lung. The basic structure of primary bronchi was the cartilage has – C – shape which opened from medial side, connected together by annular ligaments . The mean total length of left primary bronchi was (  $0.7 \pm 0.1$  cm ) and right primary bronchi was (  $0.65 \pm 0.05$  cm ).

The lungs was bright pink color, pyramidal-shaped enclosed between first and sixth ribs. Each lung contain two surfaces the costal (dorsal) surface was convex on dorsal border of this surface. Seen in this surface six deep grooves derivation embedded in the third to the sixth ribs guide to separate the lung to five lobes the first and hindermost lobes smaller than the other lobes ( Fig. 3 and 4). The lobes of lung was disconnected by prominent five grooves due to against with third, fourth, fifth, sixth and seventh. The first, second and third lobes were contain shallow grooves originated from impression of muscles and ligaments of ribs (Fig. 2 ).

The visceral (Ventral) surface concave contain the hilus on the proximal third (Fig. 3). The lung were contain two extremity proximal part narrow and extend cranially, distal part was wide and extended caudally. The distal part of the left lung observed contact with left kidney while distal part of right lung was very contact with right kidney and formed impression because the right kidney was introduced than left kidney. Lungs were appeared (left and right) two border medial thick and based on muscles of vertebral column, lateral border was thin and against ribs dorsally and viscera ventrally. Left and right lung showed surrounded by thin colorless membrane pleura and air sacs.

The mean total length of the right lung was (  $2.8 \pm 0$  cm ) while the left lung was (  $2.75 \pm 0.05$  cm ) and mean width of the right lung was (  $2.45 \pm 0.65$  cm ) while the left lung was (  $2.7 \pm 0.7$  cm ).

### **Histological study of the primary bronchi and lungs:**

The current study was appeared the walls of the primary bronchi were lined by pseudostratified columnar ciliated epithelium that it was based into lamina propria and submucosa was loose connective tissue which continued with the perichondrium which confined the hyaline bronchial cartilage. The perichondrium connective tissue externally was surrounded by adventitial connective tissue (Fig. 5).

The primary bronchi were branched inside of lung into secondary bronchi that was embedded in the lung parenchyma and lined by pseudostratified columnar ciliated epithelium. The lamina propria and submucosa were loose connective tissue and hyaline cartilage was absent but replaced by small

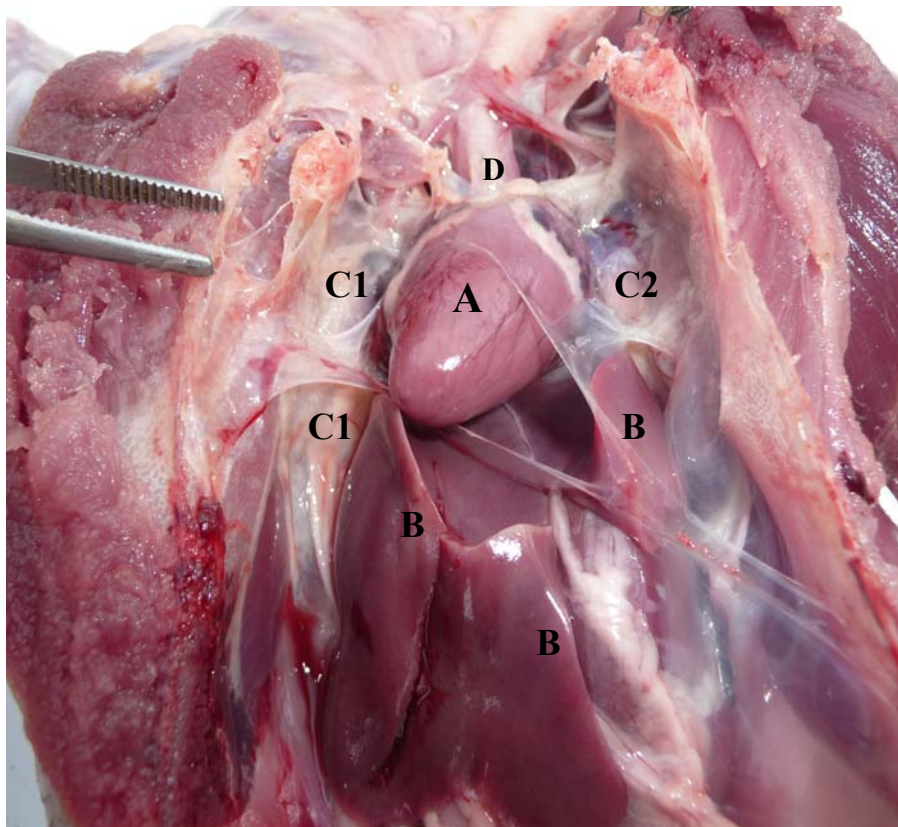
layer of the smooth muscle bundles. The bronchial walls inside the lung were openings lead to small anastomosing parabronchi. (Fig. 5).

The parabronchi were opened into the several dilated chambers called atria, that led to the smaller dilated ducts called infundibula, which led to very small and complicated network of the air capillaries includes veins and arteries. ( Fig. 6)

The histological structure of parabronchi was consists of three layers, the simple squamous epithelium, loose connective tissue layer, and thick smooth muscle fibers while the atria, infundibula, and air capillaries were lined by similar that the parabronchial epithelium and connective tissue but smooth muscles absent except on the atrial openings ( Fig. 6)

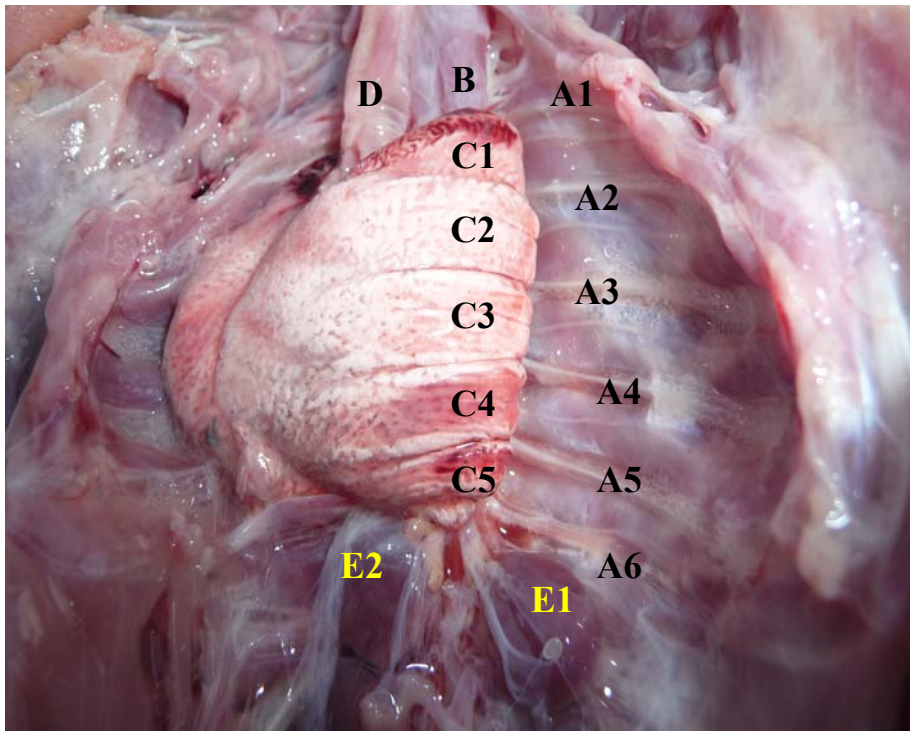
The Secondary bronchi, parabronchi, atria, infundibula and air capillaries were together with connective tissues constitute lobules of lungs. (Fig. 6).

The epithelium of air capillaries and the endothelium of blood capillaries were separated by basement membrane only. Air and blood capillaries intermingled with each other to formed the blood-gas barrier.

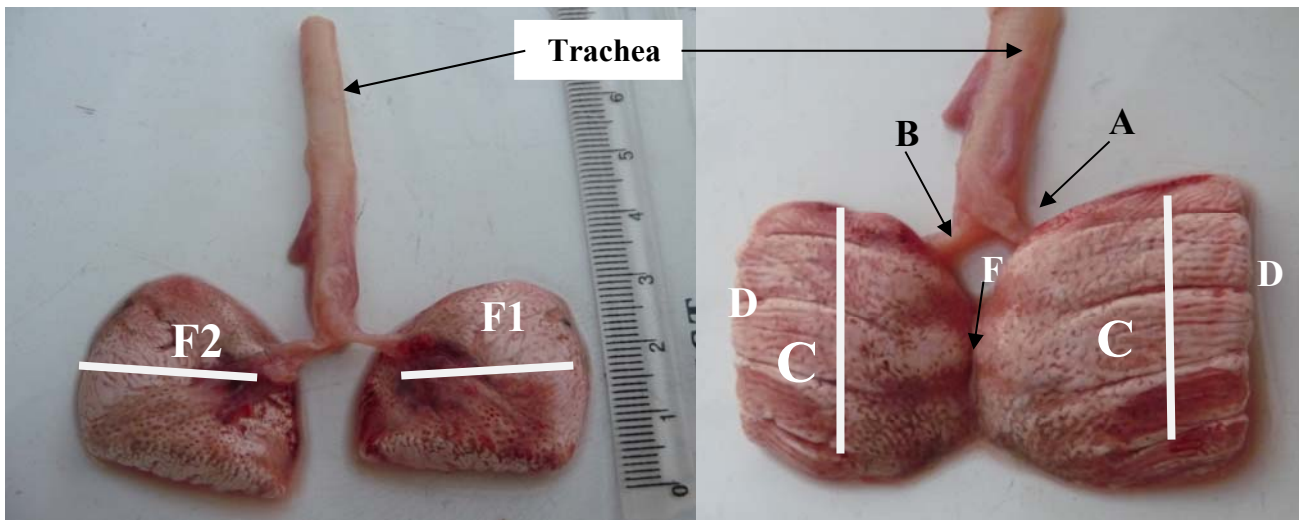


**Figure(1): Explain ventral view of the thoracic cavity of the wood pigeon:**

Heart(A), Liver(B), Right Lung (C1), Left lung(C2), Trachea(D)

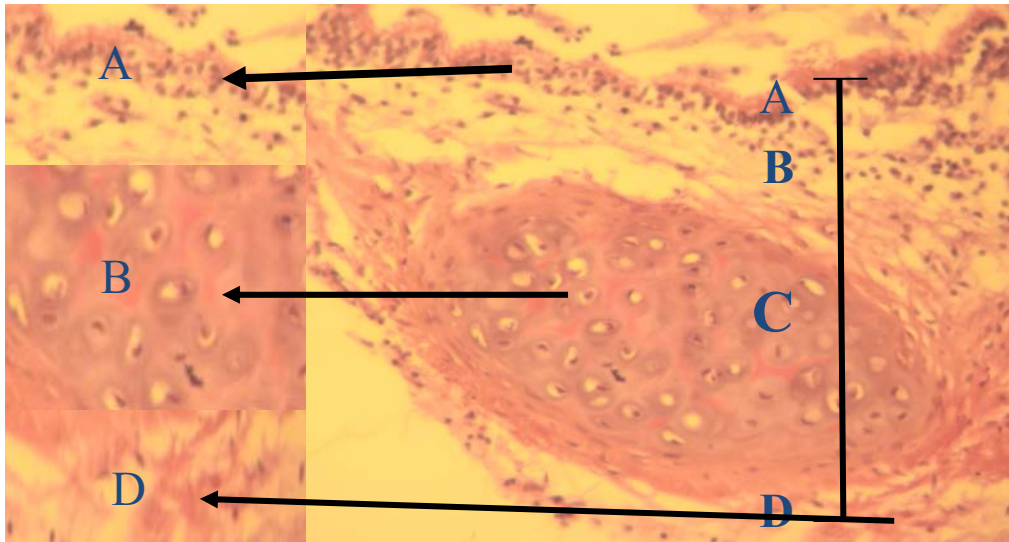


**Figure(2):** Ventral view : Ribs A(1,2,3,4,5,6), Esophagus(B), Lobes of left lung C(1,2,3,4,5), Trachea(D), Left kidney (E1), Right Kidney (E2).

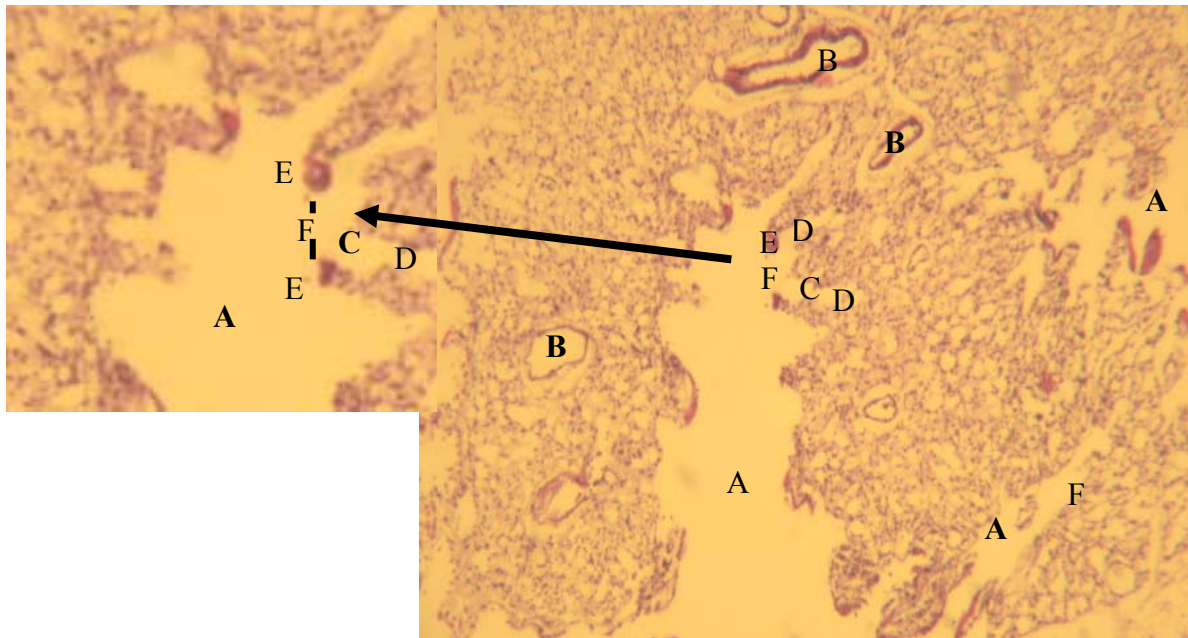


**Figure(3):** Visceral (ventral) surface.

**Figure(4):** Costal ( dorsal ) surface: Left primary bronchus (A), Right primary bronchus (B), Costal (dorsal) surface and lobulated of lung (C), Medial border of lung(D), Lateral border of lung (F).



**Figure (5):** Cross section of the primary bronchi in Wood Pigeon explain the layers of Primary bronchus: (A) Pseudostratified columnar ciliated epithelium. (B) Loose connective tissue of lamina propria-submucosa.(C) hyaline cartilages (D) perichondrium. H & E stain 100X and 400X.



**Figure (6):** Cross section of the lung in the Wood Pigeon: (A) atrial opening. (B) interparabronchial blood vessels (C) atria (D) infundibula (E) smooth muscle fibers (F). interparabronchial septa. H & E stain 100X and 400X.

## Discussion:

The present study was focused on left and right bronchi and lungs of adult wood pigeon, basic structure of primary bronchi was the cartilage has – C – shape. Histology primary bronchi were lined by pseudostratified columnar ciliated epithelium that it was based into lamina propria and externally was surrounded by adventitial connective tissue. The lungs was appeared have parabronchi were opened into the several dilated chambers called atria and epithelium of air capillaries and the endothelium of blood capillaries were separated by basement membrane only. These consequences in agreement with (7;10;13;14;15; 17;18;21;22;23;27; 28;29 and 30) in several types of the birds.

The right and left bronchi of Wood pigeon was approximately equal which disagree with (14;17 and 29) in ostriches and Turkey who mentioned that the right bronchi was relatively longer (5cm), and relatively narrower in compared with the left bronchi (4cm).

Lungs in Wood pigeons appear bright pink color, pyramidal-shaped. These results disagreement with (7) who showed that the lung appeared as flattened rectangular structure, elongated parallelogram, and trapezium-shaped in chicken, turkey, and duck respectively. The different in colors of the lungs in birds referred to the blood supplied (17).

The lungs of Wood pigeon in this study extend from the first to the sixth ribs firmly attachment with it, agree with ( 11 ) the lung in *Columba domestica* pigeon extend from first to sixth ribs.

The lung of the Wood pigeons in this study contain two surface ( costal and visceral ), differ from other birds like duck and turkey characterized by present three surfaces ( Costal, Vertebral, and Septal ) (6; 19 and 21).

The dimensions of the lung in Wood pigeon was the total length of the right lung was (  $2.8 \pm 0$  cm ) while the left lung was (  $2.75 \pm 0.05$  cm ) and mean width of the right lung was (  $2.45 \pm 0.65$  cm ) while the left lung was (  $2.7 \pm 0.7$  cm ), disagreement with ( 11 ) show the mean length of right and left lungs was (  $3.1 \pm 0.66$ cm), while the mean width of right and left lungs was (  $3.1 \pm 0.66$ cm) in *Columba domestica* pigeon, this difference is caused by the species of pigeon.

## References:

1. **Akester AR (1960):** The comparative anatomy of the respiratory pathways in the domestic fowl (*Gallus domesticus*), pigeon (*Columba livia*) and domestic duck (*Anas platyrhynchos*). **J Anat, 94, 487-505.**
2. **King AS, Mclelland J (1984):** Respiratory System. In: Birds their structure and function, 2nded, **Bailiere Tindall, England, 110-144.**
3. **Dyce K.M., Sac W. O. and Wensing C. J. G. (2010):** Text book of Veterinary Anatomy.4<sup>th</sup> Edition .**Saunders Elseveir.pp:799-804.**
- 4-**Pasquini C., Spurgeom T. and Pasquini S.(1997):** Anatomy of domestic animal.7<sup>th</sup> edition.**SUDS. pp:305-307.**
- 5- **Gerrit P. K. and Clark L. C.(1972):** The lung and air-sac system of the common grackle. **The Auk 89: 817-825.**
- 6- **Rastogi, S. C. (2007):** Respiration. In: Essential of animal physiology. **New Age Inter. (P) Ltd. PP. 263-285**

- 7- Pesek, L. (2000): The avian respiratory system. **Winged Wisdom Pet Bird Magazine 1: 1-3**
- 8- Lbe C.S., Onyeanusu B.I., Salami S.O., Umosen A.D. and Maidawa S.M.( 2008): Studies of the Major Respiratory Pathways of the West African Guinea Fowl (*Numida meleagris galeata*): the Morphometric and Macroscopic Aspects. **International Journal of Poultry Science 7 (10): 997-1000.**
- 9- McLelland, J., (1990): Respiratory system. In: A Colour Atlas of Avian Anatomy. **Wolfe Publishing Ltd. Eng. PP. 95-119.**
- 10- Eurell and Froppier (2005): Text book of Veterinary Histology 6<sup>th</sup> Edition : **Lippincott Williams & Wilkins.**
- 11- AL-Mahmodi, A.M. (2012): Macroscopic and Morphometric Studies of the Extrapulmonary Primary Bronchi and Lungs of the indigenous adult Male Pigeon (*Columba domestica*) **Kufa Journal For Veterinary Medical Sciences Vol. (3) No. (1).**
- 12- Reese, S., Dalamani, G., and Kaspers, B. (2006): The avian lung-associated immune system: A Review. **Vet. Res. 37: 311-324**
- 13- Onuk, B.; Haziroglu R.M.; Kabak, M. (2009): Gross anatomy of the respiratory system in goose (*Anser anser domesticus*): Bronchi and sacci pneumatici. **Ankara Univ. Vet. Fak. Derg. 56: 165-170**
- 14- AL-Mussawy, A.M.M. (2011): Anatomical and Histological Study of Major Respiratory Organs (Larynx, Trachea, Syrinx, Bronchi and Lungs) In Indigenous Male Turkey (*Meleagris gallopava*). **M.S. Thesis. AL-Qadisiya Uni. Vet. Med. College.**
- 15- Getty, R. (1975): Aves respiratory system. In: Anatomy of domestic animals. **W.S. saunders co. Philadelphia. PP. 1884-1917**
- 16- Aughey, E and Frye, F.L.(2001). Comparative Veterinary Histology with Clinical Correlates. **Manson publishing. Pp: 93 – 95.**
- 17- Maina, J.N. (2000). Comparative Respiratory Morphology: Themes and Principles in the Design and Construction of the Gas Exchangers. **Anat Rec B New Anat. 261:25–44**
- 18- Maina, J.N., and Africa M. (2000): Inspiratory aerodynamic valving in the avian lung: Functional morphology of the extrapulmonary primary bronchus. **J. Exp. Biol. 203: 2865-2876**
- 19- Nganpiep, L.N., and Maina, J. N. (2002): Composite cellular defense stratagem in the avian respiratory system: functional morphology of the free (surface) macrophages and specialized pulmonary epithelia. **J. Anat. 200: PP. 499–516**



- 20- **Gartner and Haitt, ( 2006 )**: Color Atlas of Histology 4<sup>th</sup> Edition. **Lippincott Williams & Wilkins.**
- 21-**Aspinall, V., and O'Reilly, M. (2005)**: Bird respiratory system. In: Introduction to Veterinary Anatomy and Physiology. **Butter Worth-Heine Mann. PP. 164-168.**
- 22- **Swenson, M.J. (2004)**: Ducks physiology of domestic animals. 9<sup>th</sup> (Ed): **Darya. Garya. Ganj., New Delhi. PP. 203**
- 23- **Demirkan, A. Ç., Kurtul, I., and Haziroglu, R. M. (2006)**: Gross morphological features of the lung and air sac in Japanese Quail. **J. Vet. Med. Sci. 68 (9): 909-913**
- 24- **Baumel, J.J., King, A.S., Breazile, J.E., Evans, H.E., and Vandan Berge, J.C. (1993)**: Respiratory system. In: Hand book of Avian Anatomy Nomina Anatomica Avium 2nd (Ed): **club. Cambridge, Massachusetts. PP. 257-299**
- 25- **Incei, N.G., Pazvant,G., and Hasan, A. ( 2012 )**: Anatomical features of the syrinx in sea gulls. **Ankara Univ. Vet. Fak. Derg, 59**
- 26- **Sereno, P.C., Martinez, R.N., Wilson, J.A., Varricchio, D.J., Alcober, O.A., Larsson, H.C.E. (2008)**: Evidence for avian intrathoracic air sacs in a new predatory dinosaur from argentina. **PLoS ONE 3(9): 1-20**
- 27- **Nickel R, Schummer A, Seiferle E (1977)**: Anatomy of the Domestic Birds. Verlg Paul Parey, **Berlin- Hamburg, 65-70.**
- 28- **Frandsen, R.D., Wilke, W.L., Fails, A.D. (2009)**: Poultry respiratory system. In: Anatomy and Physiology of farm Animals 7<sup>th</sup> (Ed): **Wiley-Black Well. PP. 471-474**
- 29- **Schachner, E.R., Lyson, T.R., and Dodson, P. (2009)**: Evolution of the respiratory system in nonavian theropods: Evidence from rib and vertebral morphology. **Ana. Rec. 292:1501–1513.**
- 30- **Thurman JC, Tranquilli WJ, Benson GJ (1996)**: Lumb and Jones Veterinary Anesthesia, 3th ed., **Lea Febiger, London.**