

Effectiveness of 10% povidone iodine as ascolicidal agent in hydatid cyst surgery in compared with other scolicidal agents

Ali Nayyef Assi*

الخلاصة

دراسة اجريت على 120 مريض خلال 3 سنوات 2004-2006 في مستشفى الحسين التعليمي في الناصرية والمتابعة للمرضى خلال فترة 5 سنوات. هدف الدراسة هو معرفة مدى قوة البوفادين ايودين 10% في قتل طفيليات مرض الاكياس المائية مقارنة بالسائل الكبريتي. اظهرت نتائج الدراسة ان 10% من المرضى الذين خضعوا لعملية ازالة الكيس او الكحول لا على التعيين للمرضى اثناء عملية ازاله الكيس ومنتظر لمدة 20 دقيقة تم ازاله الكيس بالسائل الكبريتي واثبتت نتائج الدراسة ان 10% من المرضى الذين خضعوا لعملية ازاله الكيس او الكحول لا على التعيين للمرضى اثناء عملية ازاله الكيس ومنتظر لمدة 20 دقيقة لم يتكرر المرض. وذلك التأكيد من مدى تأثير هذه المواد الثلاثة على خلايا الكبد او وظائف الكبد. ص و ط اائف الكبد ال دورى لم دهس تبة شين هورن خلال دراستنا. انا ادين اي مفيد وفعال ج دافى قتل طفيليات الاكياس المائية مقارنة بالماء ادين الاخرين وله تاثيرات جانبية قليلة على الكبد ووظائفه وله اق نسبه على ع وده الاكياس المائية بالنسبة الى الماء ادين الاخذ ان يتبين ان ح باس تخدام البوف ادين اي ودين 10% كمحلول قاتل لطفيليات الاكياس المائية اثناء عملية ازاله الكيس ولأنه ايضا ارضى ومتوفر.

Abstract

Hydatid disease or Echinococcal disease, is a parasitic disease that affects both humans and other mammals such as sheep, dogs, rodents and horses.^[1] There are three different forms of Echinococcosis found in humans, each of which is caused by the larval stages of different species of the tapeworm of genus Echinococcus^[1]. This study was done in the AL-Husseinteaching hospital (AL-Nassiyria) during 3 years (between 1st January 2004 to december 2006) and follow up for 5 years, 120 patients [70 females and 50 males] ages range between 12 years to 56 years presented with hydatid cyst in the liver only we concentrate on the hydatid cyst of liver (un complicated cases) confirm the diagnosis by U/S and CT scan, and after surgery follow up also by U/S and CT scan for 5 years.

*Consultant Surgeon – Thi qar medical college

Povidone-iodine (PVP-I) is a stable chemical complex of polyvinylpyrrolidone (povidone, PVP) and elemental iodine. It contains from 9.0% to 12.0% available iodine, calculated on a dry basis.^[1] To evaluate effectiveness of 10% povidone iodine as ascolicidal agent in liver hydatid cyst surgery in compare with hypertonic saline solution and alcohol, povidone iodine have a better effect as a scolicidal effect because (1) there's a lower recurrence rate during 5 years post operatively follow up (2) there is little post operative complication related to the povidone iodine (3) mild direct effect on the liver cell during six months follow up postoperatively according to the liver function tests results as compare with other scolicidal agents, so we can use povidone iodine 10% in surgical operation for hydatid cyst as ascolicidal because it highly effective against the scolices, little intra or post operative effects on the liver cells, cheap and widely available.

Key Words: Hydatid cyst, povidone iodine, alcohol, hypertonic saline.

Introduction

Echinococcosis, which is often referred to as hydatid disease or Echinococcal disease, is a parasitic disease that affects both humans and other mammals, such as sheep, dogs, rodents and horses.[1] There are three different forms of Echinococcosis found in humans, each of which is caused by the larval stages of different species of the tapeworm of genus *Echinococcus*. The first of the three and also the most common form found in humans is cystic Echinococcosis (also known as unilocular Echinococcosis), which is caused by *Echinococcus granulosus*. The second is alveolar Echinococcosis (also known as alveolar colloid of the liver, alveolar hydatid disease, alveolococcosis, multilocular Echinococcosis, "small fox tapeworm"), which is caused by *Echinococcus multilocularis* and the third is polycystic Echinococcosis (also known as human polycystic hydatid disease, neotropical Echinococcosis), which is caused by *Echinococcus vogeli* and very rarely, *Echinococcus oligarthus*. Alveolar and polycystic Echinococcosis are rarely diagnosed in humans and are not as widespread as cystic Echinococcosis, but polycystic Echinococcosis is relatively new on the medical scene and is often left out of conversations dealing with Echinococcosis, and alveolar Echinococcosis is a serious disease that not only has a significantly high fatality rate but also has the potential to become an emerging disease in many countries. Echinococcosis is a disease that has been recognized by

humans for centuries. There has been mention of it in the Talmud. It was also recognized by ancient scholars such as Hippocrates, Aretaeus, Galen and Rhazes. Although Echinococcosis has been well known for the past two thousand years, it wasn't until the past couple of hundred years that real progress was made in determining and describing its parasitic origin. The first step towards figuring out the cause of Echinococcosis occurred during the 17th century when Francisco Redi illustrated that the hydatid cysts of Echinococcosis were of "animal" origin. Then, in 1766, Pierre Simon Pallas predicted that these hydatid cysts found in infected humans were actually larval stages of tapeworms. A few decades afterwards, in 1782, Goeze accurately described the cysts and the tapeworm heads while in 1786, *E. granulosus* was accurately described by Batsch. Half a century later, during the 1850s, Carl von Siebold showed through a series of experiments that *Echinococcus* cysts do cause adult tapeworms in dogs. Shortly after this, in 1863, *E. multilocularis* was identified by Rudolf Leuckhart. Then, during the early to mid 1900s, the more distinct features of *E. granulosus* and *E. multilocularis*, their life cycles and how they cause disease were more fully described as more and more people began researching and performing experiments and studies. While *E. granulosus* and *E. multilocularis* were both linked to human echinococcosis before or shortly after the 20th century, it wasn't until the mid 1900s that *E. oligarthus* and *E. vogeli* were identified as and shown as being causes of human echinococcosis.[2][3][4]*E. granulosus* is present virtually worldwide since there are very few countries that are considered to be completely free of *E. granulosus*. [5] An important fact to keep in mind is that the areas of the world where there is a high incidence of infection by *E. granulosus* often coincide with rural, grazing areas where dogs are able to ingest organs from infected animals. *E. multilocularis* mainly occurs in the Northern hemisphere, including central Europe and the northern parts of Europe, Asia, and North America. However, its distribution was not always like this.[6] For instance, until the end of the 1980s, *E. multilocularis* endemic areas in Europe were known to exist only in France, Switzerland, Germany, and Austria. But during the 1990s and early 2000s, there was a shift in the distribution of *E. multilocularis* as the infection rate of foxes escalated in certain parts of France and Germany. As a result, several new endemic areas were found in Switzerland, Germany, and Austria and surrounding countries such as

the Netherlands, Belgium, Luxembourg, Poland, the Czech Republic, the Slovak Republic, and Italy. While alveolar echinococcosis is not extremely common, it is believed that in the coming years, it will be an emerging or re-emerging disease in certain countries as a result of *E. multilocularis*' ability to spread.[7] Unlike the previous two species of *Echinococcus*, *E. vogeli* and *E. oligarthus* are limited to Central and South America. Furthermore, infections by *E. vogeli* and *E. oligarthus* (polycystic echinococcosis) are considered to be the rarest form of echinococcosis.[8] *Echinococcus* eggs contain an embryo that is called an oncosphere or hexacanth. The name of this embryo stems from the fact that these embryos have six hooklets. The eggs are passed through the feces of the definitive host and it is the ingestion of these eggs that lead to infection in the intermediate host.[8] From the embryo released from an egg develops a hydatid cyst, which grows to about 5–10 cm within the first year and is able to survive within organs for years.[9] Cysts sometimes grow to be so large that by the end of several years or even decades, they can contain several liters of fluid. Once a cyst has reached a diameter of 1 cm, its wall differentiates into a thick outer, non-cellular membrane, which covers the thin germinal epithelium. From this epithelium, cells begin to grow within the cyst. These cells then become vacuolated and are known as brood capsules, which are the parts of the parasite from which protoscolices bud. Often, daughter cysts will also form within cysts.[8] *Echinococcus* adult worms develop from protoscolices and are typically 6mm or less in length and have a scolex, neck and typically three proglottids, one of which is immature, another of which is mature and the third of which is gravid (or containing eggs).[8] The scolex of the adult worm contains four suckers and a rostellum that has about 25-50 hooks.[10] The major morphological difference among different species of *Echinococcus* is the length of the tapeworm. *E. granulosus* is approximately 2 to 7 mm while *E. multilocularis* is often smaller and is 4 mm or less.[11] On the other hand, *E. vogeli* is found to be up to 5.6 mm long and *E. oligarthus* is found to be up to 2.9 mm long.[6] In addition to the difference in length, there are also differences in the hydatid cysts of the different species. For instance, in *E. multilocularis*, the cysts have an ultra thin limiting membrane and the germinal epithelium may bud externally. Furthermore, *E. granulosus* cysts are unilocular and full of fluid while *E. multilocularis* cysts contain little fluid and are multilocular. For *E. vogeli*, its hydatid cysts are large and are actually polycystic since the

germinal membrane of the hydatid cyst actually proliferates both inward, to create septa that divide the hydatid into sections, and outward, to create new cysts. Like *E. granulosus* cysts, *E. vogeli* cysts are filled with fluid.[8]As one can see from the life cycles illustrated above, all disease-causing species of *Echinococcus* are transmitted to intermediate hosts via the ingestion of eggs and are transmitted to definitive hosts by means of eating infected, cyst-containing organs. When thinking about transmission, it is important to remember that humans are accidental intermediate hosts that become infected by handling soil, dirt or animal hair that contains eggs. In order to formally diagnose a patient with any type of Echinococcosis, one must use a combination of tools that involve imaging techniques, histopathology and/or nucleic acid detection and serology. For cystic Echinococcosis, imaging is the main method that is relied on for diagnosis while serology tests (such as indirect hemagglutination, ELISA (enzyme linked immunosorbent assay), immunoblots or latex agglutination) that use antigens specific for *E. granulosus* are used to verify the imaging results. The imaging technique of choice for cystic Echinococcosis is ultrasonography since it is not only able to visualize the cysts in the body's organs [15] but it is also inexpensive, non-invasive and gives instant results.[16] In addition to ultrasonography, both MRI and CT scans can and are often used although an MRI is often preferred to CT scans when diagnosing cystic Echinococcosis since it gives better visualization of liquid areas within the tissue.[15] In the human manifestation of the disease, *E. granulosus*, *E. multilocularis*, *E. oligarthus* and *E. vogeli* are localized in the liver (in 75% of cases), the lungs (in 5-15% of cases) and other organs in the body such as the spleen, brain, heart and kidneys (in 10-20% of cases). In the patients who are infected with *E. granulosus* and therefore have cystic Echinococcosis, the disease develops as a slow-growing mass in the body. These slow-growing masses, often called cysts, are also found in patients that are infected with alveolar and polycystic Echinococcosis. The cysts found in those with cystic echinococcosis are usually filled with a clear fluid called hydatid fluid, are spherical and typically consist of one compartment and are usually only found in one area of the body. While the cysts found in those with alveolar and polycystic Echinococcosis are similar to those found in those with cystic Echinococcosis, alveolar and polycystic Echinococcosis cysts usually have multiple compartments and have infiltrative as opposed to

expansive growth.[2][18] Depending on the location of the cyst in the body, the patient could be asymptomatic even though the cysts have grown to be very large or be symptomatic even if the cysts are absolutely tiny. If the patient is symptomatic, the symptoms that an infected patient exhibits will also depend largely on where the cysts are located. For instance, if the patient has cysts in the lungs and is symptomatic, they will have a cough, shortness of breath and/or pain in the chest. On the other hand, if the patient has cysts in the liver and is symptomatic, they will suffer from abdominal pain, abnormal abdominal tenderness, hepatomegaly with an abdominal mass, jaundice, fever and/or anaphylactic reaction. In addition, if the cysts were to rupture while in the body, whether during surgical extraction of the cysts or by some kind of trauma to the body, the patient would most likely go into anaphylactic shock and suffer from high fever, pruritus (itching), edema (swelling) of the lips and eyelids, dyspnea, stridor and rhinorrhea.[19]. Unlike intermediate hosts, definitive hosts are usually not hurt very much by the infection. Sometimes, a lack of certain vitamins and minerals can be caused in the host by the very high demand of the parasite. For simple cases of cystic Echinococcosis, the most common form of treatment is surgical removal of the cysts combined with chemotherapy using albendazole and/or mebendazole before and after surgery. However, if there are cysts in multiple organs or tissues, or the cysts are in risky locations, surgery becomes impractical. For inoperable cases such as these, chemotherapy and/or PAIR (puncture-aspiration-injection-reaspiration) become alternative options of treatment.[20] In the case of alternative treatment using just chemotherapy, albendazole is preferred with an adult dosage of 400 mg orally, twice a day for 1–5 months and a pediatric dosage of 15 mg/kg/day (max. of 800 mg) for 1–6 months.[21] An alternative to albendazole is mebendazole at a dosage of 40 to 50 mg/kg/day for at least 3 to 6 months. The other alternative to surgery is PAIR with chemotherapy. PAIR is a minimally invasive procedure that involves three steps: puncture and needle aspiration of the cyst, injection of a scolicidal solution for 20-30 min, and cyst-re-aspiration and final irrigation. Patients who undergo PAIR typically take albendazole or mebendazole from 7 days before the procedure until 28 days after the procedure. While surgery still remains as the standard for cystic Echinococcosis treatment, there have been a number of studies that suggest that PAIR with chemotherapy is more effective than surgery in

terms of disease recurrence, and morbidity and mortality.[22] In addition to the three abovementioned treatments, there is currently research and studies looking at new treatment involving percutaneous thermal ablation (PTA) of the germinal layer in the cyst by means of a radiofrequency ablation device. This form of treatment is still relatively new and requires much more testing before being widely used.[11].Povidone-iodine (PVP-I) is a stable chemical complex of polyvinylpyrrolidone (povidone, PVP) and elemental iodine. It contains from 9.0% to 12.0% available iodine, calculated on a dry basis.[1]This unique complex was discovered at the Industrial Toxicology Laboratories in Philadelphia by H. A. Shelanski and M. V. Shelanski.[2] They carried out tests in vitro to demonstrate anti-bacterial activity, and found that the complex was less toxic than tincture of iodine in mice. Human clinical trials showed the product to be superior to other iodine formulations.[3]It was first sold in 1955, and has since become the universally preferred iodine antiseptic. [3]PVP-I is completely soluble in cold water, ethyl alcohol, isopropyl alcohol, polyethylene glycol, and glycerol. Its stability in solution is much greater than that of tincture of iodine or Lugol's solution.Free iodine, slowly liberated from the povidone-iodine (PVP-I) complex in solution, kills eukaryotic or prokaryotic cells through iodination of lipids and oxidation of cytoplasmic and membrane compounds. This agent exhibits a broad range of microbicidal activity against bacteria, fungi, protozoa, and viruses. Slow release of iodine from the PVPI complex in solution minimizes iodine toxicity towards mammalian cells.Following the discovery of iodine by Bernard Courtois in 1811, it has been broadly used for the prevention and treatment of skin infections, and the treatment of wounds. Iodine has been recognized as an effective broad-spectrum bactericide, and it is also effective against yeasts, molds, fungi, viruses, and protozoans. Drawbacks to its use in the form of aqueous solutions include irritation at the site of application, toxicity and the staining of surrounding tissues. These deficiencies were overcome by the discovery and use of PVP-I, in which the iodine is carried in a complexed form and the concentration of free iodine is very low. The product thus serves as an iodophor. In addition, it has been demonstrated that bacteria do not develop resistance to PVP-I,[4] and the sensitization rate to the product is only 0.7%[5] Consequently, PVP-I has found broad application in medicine as a surgical scrub; for pre- and post-operative skin cleansing; for the treatment and prevention of infections in wounds,

ulcers, cuts and burns; for the treatment of infections in decubitus ulcers and stasis ulcers; in gynecology for vaginitis associated with candidal, trichomonal or mixed infections. For these purposes PVP-I has been formulated at concentrations of 7.5–10.0% in solution, spray, surgical scrub, ointment, and swab dosage forms. It is available without a prescription under the generic name povidone-iodine or the brand name Betadine. It is used in pleurodesis (fusion of the pleura because of incessant pleural effusions). For this purpose, povidone-iodine is equally effective and safe as talc, and may be preferred because of easy availability and low cost.[6] 2.5% buffered PVP-I solution can be used for prophylaxis of neonatal conjunctivitis (*Ophthalmia neonatorum*) which can lead to blindness, especially if it is caused by *Neisseria gonorrhoeae*, or *Chlamydia trachomatis*. PVP-I appears to be very suitable for this purpose because unlike other substances it is efficient also against fungi and viruses (including HIV and Herpes simplex).[7] PVP-I can be loaded into hydrogels (based on carboxymethyl cellulose, poly(vinyl alcohol) and gelatin, or on crosslinked polyacrylamide). These hydrogels can be used for wound dressing. The rate of release of the iodine in the PVP-I is heavily dependent on the hydrogel composition. The release rate increases with more CMC/PVA and decreases with more gelatin. PVP-I can also be used to reduce skin damage from mustard gas, although it must be applied immediately post-exposure to have any effect, and mustard gas exposure is usually not noticed until the onset of skin irritation, by which point PVP-I administration is useless. Recently povidone-iodine has found application in the field of nanomaterials. A wound-healing application has been developed which employs a mat of single wall carbon nanotubes (SWNTs) coated in a monolayer of povidone-iodine.[8] It has been previously shown that the polymer polyvinylpyrrolidone (PVP, povidone) can coil around individual carbon nanotubes to make them water-soluble.[9].

Aim of study

To evaluate effectiveness of 10% povidone iodine as ascolicidal agent in liver hydatid cystsurgery in compare with hypertonic salinesolution and alcohol.

Patients and methods

This study was carried out at al Hussein teaching hospital on 120 patients [70 females and 50 males] having an uncomplicated hydatid cyst in the liver through 3 years and follow up for 5 years post operatively, after we confirm diagnosis of hydatid cyst in the liver by US and CT scan and to be sure that there is no any other cyst in the liver or abdominal cavity, we take consent of operation from the patients after we explain to him (her) why, when, who and where we do the operation and the post operative complication that will be occur. We divided patients to 3 equal groups randomly **group A** we use povidone iodine 10%, **group B** we use hypertonic saline solution and **group C** we use alcohol as ascolicidal agent. After patient take general anesthesia we open the patients through sub costal incision, open abdomen through alayers then we reach the cyst we surround the cyst by gauze socked with povidone iodine 10% or socked with hypertonic saline or alcohol according to the type of scolicidal agents that we used, we used these three agents randomly, then through 18 guage needle aspirate 10 cc from hydatid fluid and reinject 10 cc from one types of ascolicidal agents that we used, (povidone iodine 10%, hypertonic saline or alcohol), we wait for 20 minutes, then we did a small opening in the cyst gently and aspirate the contents by sucker, the cavity we obliterated by omentum. Any complicated case either infected or communication with biliary tree we excluded from our study, we take only un complicated cases. we put sub hepatic drain and closed the abdomen in layers, after discharging the patient we start to follow him **5 years** by US & CT scan checking for recurrence in the liver or in the abdominal cavity due to leakage of hydatid fluid, and for liver function test monthly for six months.

Results

There is a lowers recurrent cases through 5 years follow up with povidone iodine 10% only 5 patients (12.5%).. but with hypertonic saline 12 patients (30%) and 11 patients with alcohol (27.5%). There is increase in liver enzymes SGOT & SGPT in group A 8 patients (20%) between 60 and 65 IU, in GROUP B 11 patients (27.5%) and in group C 15 patients (37.5). Increase level of total serum bilirubin in group A in 2 patients (5%), in group B 3 patients (7.5%) and in group C 5 patients (12.5%). In group A there is 2 patient (5%) got post operative

collections [sub phrenic ,sub hepatic and intra cystic abscesses] while in group B 3 patients(7.5%) and in group C 2 patients also (5%). About wound infection in groupA 5patients (12.5%)while in group B 7 patients (17.5%) and in group C 8patients(20%).

Discussion

Hydatid disease is a common disease especially in our country and in our city because our people are in contact with the definitive host of the parasite.Surgical treatment carry high percentage of recurrence if we not use a highly effective scolicial agent and may convert patient who have single liver hydatid cyst to patient with multiple untreatable cysts due to leakage of contents during aspiration or evacuation of cyst. So our study aimed to this point and we did study on three types of scolicial agents to see which one more effective against the scolices and have less adverse effects.We obtain better results as ascolicidal agentwith povidone iodine 10%, and have milder effect on surrounding structure and intra abdominal organs especially we use gauzes socked with povidone iodine 10% around liver, and have milder effect on liver cells and less incidence of post operative collections and wound infections.

Conclusion

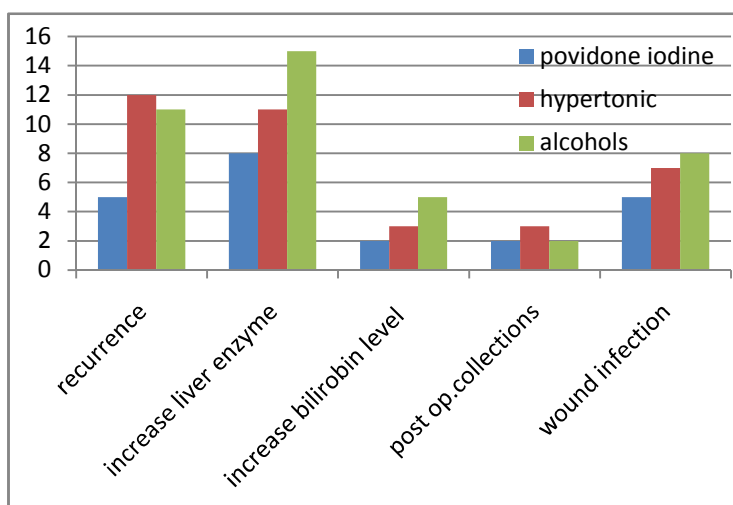
Povidone iodine hasbetter effect as a scolicial effect because lower recurrence rate during 5 years post operative follow up ,little post operative complication ,mild direct effect on the liver cell during six months follow up postoperatively according to the liver function tests results as compare with other scolicial agents, so we advice use povidone iodine 10% in surgical operation for hydatid cyst as ascolicidal because it highly effective against the scolices, little intra or post operative effects on the liver cells , cheap and widely available.

Distribution according to the sex of patients

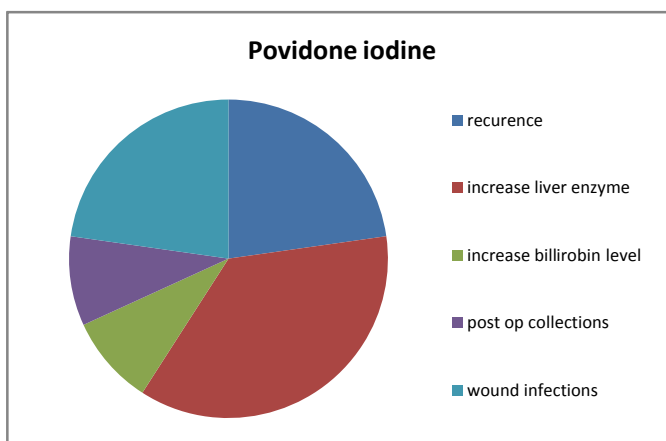
Patients no.	Femal	Male
120 patients	70 patients 58.3%	50 patients 41.7%

Percentage of the complications that occur with uses of different scolicidal agents

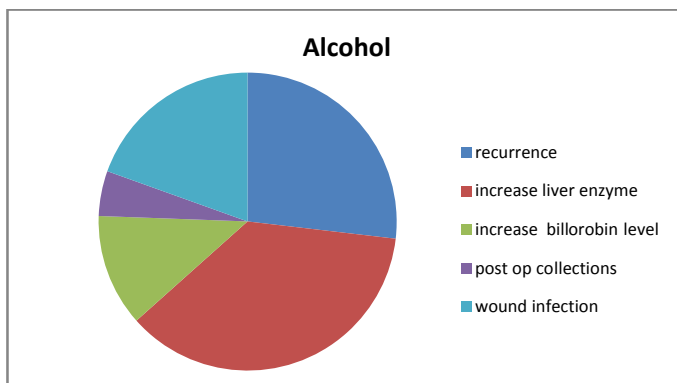
Complications	Povidone iodine 10%	Hypertonic saline solutions	Alcohol
Recurrence rate	5 patients 12.5%	12 patients 30%	11 patients 27.5%
Increase level of SGOT & SGPT	8 patients 20%	11 patient 27.5%	15 patients 37.5%
Increase serum bilirubin level	2 patients (2-3 mg) 5%	3 patients (2mg) 7.5%	5 patients (2.5-3mg) 12.5%
Post op. collections	2 patients 5%	3 patients 7.5%	2 patients 5%
Wound infection	5 patients 12.5%	7 patients 17.5%	8 patients 20%



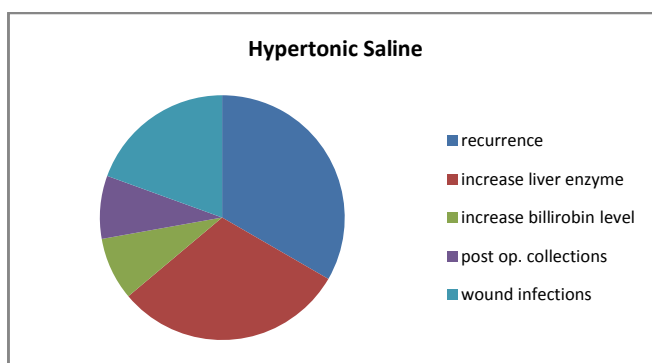
Number of complications according to the scolicidal agents



Percentage of the complications that occurred with uses of povidone iodine 10%



Percentage of the complications occurred with uses of alcohol



Percentage of complications that occurred with uses OF hypertonic saline solution

References

- 1- Berger SA, Marr JS. Human Parasitic Diseases Sourcebook. Jones and Bartlett Publishers: Sudbury, Massachusetts, 2006.
- 2- Tappe, Dennis, August Stich, and Matthias Frosch. "Emergence of Polycystic Neotropical Echinococcosis." Emerging Infectious Disease 14.2 (2008): 292-97. Web. 21 Febru. Echinococcosis. 2006. Web. 5 February 2010. <<http://www.stanford.edu/group/parasites/ParaSites2006/Echinococcus/index.html>>.
- 3- Budke, Christine M., Peter Deplazes, and Paul R. Torgerson. "Global Socioeconomic Impact of Cystic Echinococcosis." Emerging Infectious Disease (2006). Web. 15 February 2010.

- 4- CDC. "Parasites and Health: Echinococcosis." DPDx. 20 July 2009. CDC, Web. 5 February 2010. < <http://www.dpd.cdc.gov/DPDx/html/Echinococcosis.htm>>.
- 5- Sréter, Tamás, Zoltán Széll, Zsuzsa Egyed, and István Varga. "Echinococcus multilocularis: an Emerging Pathogen in Hungary and Central Eastern Europe." *Emerging Infectious Disease* (2003). Web. 20 February 2010
- 6- John, David T. and William A. Petri. *Markell and Voge's Medical Parasitology*. 9th ed. St. Louis, MI: Saunders Elsevier, 2006. 224-231. Print.
- 7- Mandell, Gerald L. Mandell, Douglas, and Bennett's *Principles and Practice of Infectious Diseases*. 7th ed. Philadelphia, PA: Elsevier Inc., 2010. Ch. 290. Print.
- 8- CDC. "Parasite Image Library: Echinococcosis." DPDx. CDC, Web. 20 February 2010. <[http:// www. dpd. cdc. Gov /dpdx /HTML/ImageLibrary /Echinococcosis_il.htm](http://www.dpd.cdc.gov/dpdx/HTML/ImageLibrary/Echinococcosis_il.htm)>.
- 9- Eckert, Johannes, and Peter Deplazes. "Biological, Epidemiological, and Clinical Aspects of Echinococcosis, a Zoonosis of Increasing Concern." *Clinical Microbiology Reviews* 17.1 (2004): 107-135. Web. 5 February 2010. <[http://cmr.asm.org/cgi/content/full/17/1/107#The %20 Parasite%20and%20Its%20Life%20Cycle](http://cmr.asm.org/cgi/content/full/17/1/107#The%20Parasite%20and%20Its%20Life%20Cycle)>.
- 10- Kemp, Charles, and Amy Roberts. "Infectious Diseases: Echinococcosis (Hydatid Disease)." *Wiley InterScience Logo Journal of the American Academy of Nurse Practitioners* 13.8 (2001): 346-47. Web. 21 February 2010.
- 11- Sréter, Tamás, Zoltán Széll, Zsuzsa Egyed, and István Varga. "Echinococcus multilocularis: an Emerging Pathogen in Hungary and Central Eastern Europe." *Emerging Infectious Disease* (2003). Web. 20 February 2010
- 12- Macpherson, Calum N.L., Ruth Milner, and . "Performance Characteristics and Quality Control of Community Based Ultrasound Surveys for Cystic and Alveolar Echinococcosis." *Acta Tropica* 85. (2003): 203-09. Web. 24 February 2010.

- 13-Knapp, Jenny, et al. "Echinococcus vogeli Infection in a Hunter, French Guiana." *Emerging Infectious Disease* 15.12 (2009). Web. 24 February 2010.
- 14-Canda, M. Serefettin, Merih Guray, Tulay Canda, and Huseyin Astarcioglu. "The Pathology of Echinococcosis and the Current Echinococcosis Problem in Western Turkey." *Turk J Med Sci* 33. (2003): 369-374. Web. 5 February 2010. < <http://journals.tubitak.gov.tr/medical/issues/sag-03-33-6/sag-33-6-5-0209-8.pdf>>.
- 15- Bitton, M, et al. "Anaphylactic Shock After Traumatic Rupture of a Splenic Echinococcal Cyst." *Harefuah* 122.4 (1992): 226-28. Web. 24 February 2010.
- 16- CDC. "The Medical Letter (Drugs for Parasitic Infections)." *DPDx*. 20 July 2009. CDC, Web. 25 February 2010. <http://www.dpd.cdc.gov/dpdx/hTML/PDF_Files/MedLetter/TapewormInfection.pdf>.
- 17- Park, Kyung-Hwa, Sook-In Jung, Hee Chang Jang, and Jong-Hee Shin. "First Successful Puncture, Aspiration, Injection, and Re-Aspiration of Hydatid Cyst in the Liver Presenting with Anaphylactic Shock in Korea." *Yonsei Med J* 50.5 (2009): 717-20. Web. 24 February 2010.
- 18-Sharma, Deborshi, et al. "Laparoscopy for Liver Hydatid Disease: Where Do We Stand Today?" *Surgical Laparoscopy, Endoscopy & Percutaneous Techniques* 19.6 (2009): 419-23. Web. 23 February 2010.
- 19- Craig, Philip S., et al. "Prevention and Control of Cystic Echinococcosis." *Lancet Infectious Disease* 7.6 (2007). Web. 24 February 2010.
- 20-Primary Alveolar Echinococcosis ." *Vaccine* 27.52 (2009): 7339-7345. Web. 25 February 2010.
- 21-united state pharmacopeia
- 22-U.S.patent 2,739,922
- 23- Walter Sneader in *Drug Discovery: A History*, p 68. New York: John Wiley & Sons, 2005
- 24-W.Fleischer and K.Reimer: Povidone-iodine in antisepsis — State of the art, *Dermatology*, 195(Suppl 2) 3–9 (1997)

25-R.Niedner: Cytotoxicity and sensitization of povidone-iodine and other frequently used anti-infective agents, *Dermatology*, 195(Suppl 2) 89–92 (1997)

26-Das SK, Saha SK, Das A, Halder AK, Banerjee SN, Chakraborty M (September 2008). "A study of comparison of efficacy and safety of talc and povidone iodine for pleurodesis of malignant pleural effusions". *J Indian Med Assoc* 106 (9): 589–90, 592. PMID19552086.

27-Formulation and Clinical Evaluation of Povidone-Iodine Ophthalmic Drop.

28-Simmons, Trevor; Lee, S.-H.; Park, T.-J.; Hashim, D.P.; Ajayan, P.M.; Linhardt, R.J. (2009). "Antiseptic Single Wall Carbon Nanotube Bandages". *Carbon* 47 (6): 1561–1564. doi:10.1016/j.carbon.2009.02.005. [http:// www.owl.net.rice.edu/~rv4/Ajayan / CARBON5200.pdf](http://www.owl.net.rice.edu/~rv4/Ajayan / CARBON5200.pdf).

29-Simmons, Trevor; Hashim, D; Vajtai, R; Ajayan, PM (2007). "Large Area-Aligned Arrays from Direct Deposition of Single-Wall Carbon Nanotubes". *J. Am. Chem. Soc.* 129 (33): 10088–10089. doi:10.1021/ja073745e. PMID17663555. <http://pubs.acs.org/cgi-bin /article.cgi/jacsat/2007/129/i33/html/ja073745e.html>.