

APPENDICAL MUCOCELE

*Muayad A. Al.khafaji.

**Taghreed S. Al.Quizwini

الخلاصة:-

ان الكيس المخاطي للزائدة الدودية هو توسع كيسي في الزائدة نتيجة تجمع المادة المخاطية في تجويفها، وهو اما بسيط ناتجاً عن التهاب الزائدة الدودية الناتج بدوره من انسداد بوابة الزائدة بمادة ليفية أو معقد مصحوب بورم غُدِّي حميد او خبيث في بوابة الزائدة ، وهي حالة نادرة يمكن اكتشافها في 0.1 % - 0.4 % من حالات استئصال الزائدة الدودية . لقد تم تسجيل هذه الحالة التي ظهرت سريرياً وبفحص الأمواج فوق الصوتية مشابهة لحالة التواء كيس المبيض الأيمن

Abstract

Appendiceal mucocele is cystic dilation of the vermiform appendix from accumulation of mucoid substance within the lumen. It is either simple which develops after appendicitis if the lumen became obstructed by fibrosis or one associated with cystadenoma or cystadenocarcinoma. It is a rare condition encountered in only 0.1 - 0.4% of all appendicectomies. We reported a case that presented to agynaecologist with a picture simulating ovarian cyst torsion and we briefly reviewed the literature.

Introduction:

Appendiceal mucocele is a rare lesion of the vermiform appendix, characterized by gross enlargement of the appendix form accumulation of mucoid substance within the lumen. It is a rare condition, encountered in only 0.1-0.4% of all Appendicectomies with a female predominance and an Average age at the time of diagnosis over 50 years (1). We report this case to highlight this rare and unusual condition as it presented essentially as a gynecological problem.

Case report

A 38 years old lady presented with 2 days history of lower abdominal pain. The latter was of sudden onset, stabbing in character, fluctuating in its intensity, aggravated by lying supine, relieved by leaning forward, and accompanied with anorexia and frequent micturition.

* FRCS FACS Al.Diwaniya Teaching Hospital

** CABOG Pediatric and Maternity Teaching Hospital in Diwaniya

✚ On examination, there was tachycardia, mild fever, with presence of a tender mass in the right iliac fossa overlaid by mild muscle guarding. Both tenderness and guarding limited the identification of other characteristics of the mass. Investigations showed leukocytosis and ultrasound imaging revealed the presence of right ovarian cyst of 8.4×6.1cm, thin walled, with signs of internal bleeding Fig.(1).

✚ After appropriate and rapid pre-operative preparation, the patient underwent laparotomy through Pfannenstiel incision, the problem was found to be a cystic vermiform appendix with signs of inflammation upon the serosa and peri-cystic adhesions toward the posterior abdominal wall and the urinary bladder. The cyst was sharply and bluntly dissected away from the surroundings, appendectomy was done and the wound was closed in layers the patient was discharged in the next day, and was seen after 7 days for removal of the stitches and month later without any complication. The cyst was sent for histopathological examination and the latter revealed an inflammatory mucocele of the appendix without malignant changes Fig.(2) and(3).

Discussion:

Mucocele of the appendix may be simple or one associated with an adenoma (Cystadenoma) or carcinoma (cystadenocarcinoma).

*A simple mucocele can develop after appendicitis if the lumen became obstructed by fibrosis. The epithelium distal to the obstruction continues to secrete mucous forming a thin walled grossly dilated appendix, which is often symptomless.

* Mucocele may become infected to form an empyema of the appendix or may rupture to form one type of pseudomyxoma peritonei. (2).

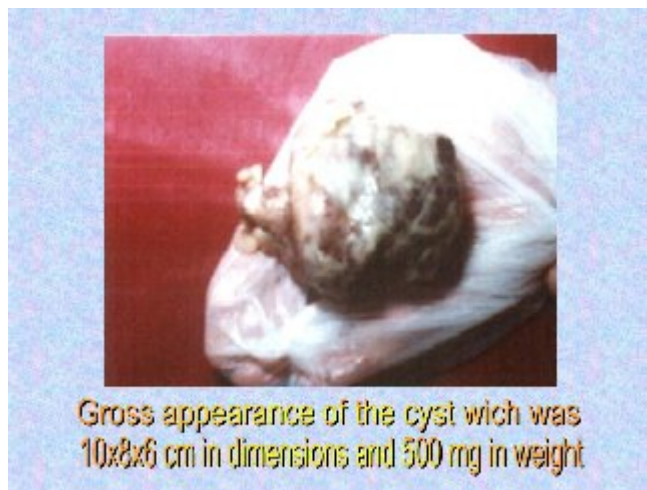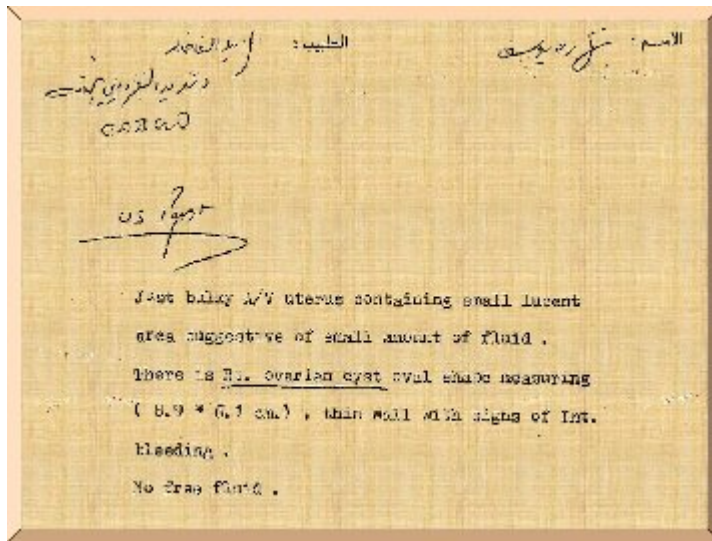
* It is uncommon condition and pre-operative diagnosis is rare. Abdominal ultrasound and CT scan of the abdomen may suggest the diagnosis, however the diagnosis is often an incidental finding. A frozen section examination should be performed in all patients, while the abdomen is open, because it may be impossible to predict the underlying pathology merely by inspecting the serosal surface of a dilated appendix. If a simple retentional cyst is uncovered, without atypia, appendectomy should be curative, if cystadenoma or cystadenocarcinoma of the appendix are found, more extended resection was necessary.(1). Our case presented with a picture simulating ovarian cyst torsion.

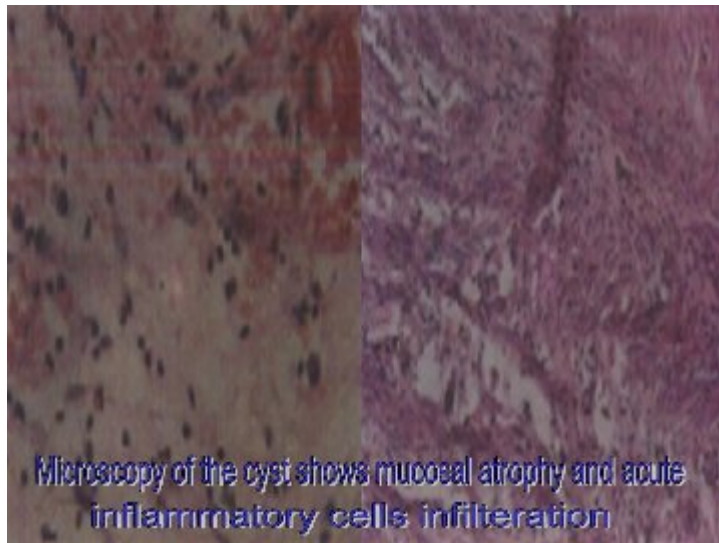
*On reviewing the literature, we found case reports similar to ours, and the presentation was either ovarian cyst torsion, or an abdominal pain

with change in bowel habit, or it was an incidental finding in the diagnostic work-up or in operations for other problems. (1),(3),(4).

*Laparoscopy was found to have an important rule both in the diagnosis and treatment of the condition (4).

*We present the case because of its rarity and its diagnostic difficulty. As a conclusion mucocele of the appendix is a rare disease, difficult to be diagnosed pre-operatively without the aid of laparoscope. An appendectomy is an adequate treatment for benign disease. If malignant disease is demonstrated, a right hemicolectomy should be performed.





References

1. Martinez et al mucocele of the veriform appendix, Rev. Gastro enteral- Mex.(1996) Oct-Dec; 61(4):366-70.
2. Roy AJ Spence, Patrick CH Watt, James M Sloan. Pathology for Surgeons, 2nd edition, (1994) pp.123.
- 3.Emmi-s *et al* Appendiceal mucocele. Minerva- chi. (1998) Oct; 53(10): 807-10.
- 4.Huary-cc; Lo-Lk;koh-Lw, pelviscopic removal of an appendiceal mucocele. J. Am. Assoc. Gynecol –Laparosc. (1994) Feb; 1(2): 174-6.