

Anatomical, Histological and Histochemical Architecture of pancreases in Early Hatched Goose (Anser anser)

Department of Anatomy and Histology -College of Veterinary Medicine Al-Qadisiyah University.

Kew word: Anatomical, Histological, Hatched Goose, Pancreases

Hassaneensharoot1980@yahoo.com

Abstract

The present work includes anatomical, histological and histochemical study of the pancreas in early hatched Goose (Anser anser). The current study was performed on ten early-hatched goose ageing from 5-10 days clinically healthy. The animals were anaesthetized by the ether after which they were carefully dissected and examined. Anatomical study shown pancreas it is a vital lobulated organ, pale pinkish in color, located on the right side of the abdominal cavity between the descending and ascending duodenal loops closely covered by mesentery pancreatic duodenal ligament and its consist of dorsal, ventral, third and splenic lobe. Histologically parenchyma of gland consisted of exocrine and endocrine parts was located in the meshwork of reticular fibres. Exocrine part was arranged in form of serous tubuloacinar glands that occupied a larger area of pancreas. The islands of langerhans consisted of various shapes and sizes of alpha, beta cell and mixed islets were not observed in the early hatched goose pancreas.

Introduction

Goose are waterfowl birds belonging to the tribe Anserini of the family Anatidea (1). These species of birds are from within important domestic birds which featuring by high resistance disease when it breeding in different environmental conditions and also considered friends of farmers compare with the other type of the birds because high fatty liver production in the world (2, 3), and play important role for the controlling the harmful pests of crops (4).

Accessory organs of digestive system includes (liver and pancreases), the pancreas of birds is the largest accessory gland connected with alimentary tract; it consists of exocrine and endocrine compartments (5, 6). The exocrine part secretion of many essential enzymes and many electrolytes released in digestive system (7, 8). While the endocrine part of pancreas consists of large and small islets (Langerhans islets) (9). The islets are named as alpha, beta and mixed islets according to their cellular composition, these islets responsible for released regulated hormone like insulins into blood vessels (10, 11, 12).

Many differences in the structure, location, distribution of the islets and structure of ducts between pancreases of birds and other species of animals (13). The present study was conducted to investigate the structure of pancreases in early hatched goose (Anser anser) to provide base line information.

Material and Methods

The Experimental Animals

The experiment was includes ten early hatched goose ageing from 5-10 days. They were immediately transferred to the veterinary anatomy laboratory in al-qadisiyah university. The animals were anaesthetized by the ether after which they were carefully dissected through mid-ventral incision from the inguinal region to the mandibular symphysis after that anatomographic study beginning which including (weight, length) of pancreas lobes and recorded.

Specimens for histological study were collected immediately after gross examination. The specimens were fixed in 10% formalin for about 24 hours. The samples preserved in 70% ethyl alcohol dehydrated in graded series of alcohol, cleared in xylene and embedded in paraffin wax as usual. Sections of 4–6 μ thickness were mounted on clean glass, slides and stained with the haematoxylin and Eosin (H&E) for general structure and PAS stains to study the histochemical features of the pancreases (14, 15).

Results

Gross study

The anatomical studies that appear the pancreas of early hatched goose it is a vital lobulated organ, pale pinkish in color, located on the right side of the abdominal cavity between the descending and ascending duodenal loops closely covered by mesentery pancreatic duodenal ligament fig (1). The lobes of pancreas were very short and not full the space between the two limbs of duodenum. Its consist of dorsal, ventral, third and splenic lobe fig (2, 3). The mean weight of pancreas is (3.721 ± 0.06) gm table (1). The mean weights of the dorsal, ventral, splenic and third lobes are (2.085 ± 0.02) , (1.576 ± 0.02) , (0.033 ± 0.01) , (0.027 ± 0.02) gm respectively table (1). While the mean length of the dorsal lobe is (2.33 ± 0.05) cm, the ventral lobe is (2.388 ± 0.03) cm, splenic lobe (1.13 ± 0.03) cm, and third lobe (1.02 ± 0.02) cm, respectively table (1).

Histological study appear the pancreas was covered by a thin connective tissue capsule, which consisted of collagenous, elastic and reticular fibers and was lined by mesothelium. Extend from the capsule septa divide the gland into lobules (Fig4). Blood, lymph vessels, nerves and excretory ducts run within the connective tissue septa.

The parenchyma of gland consisted of exocrine and endocrine parts was located in the meshwork of reticular fibres (Fig.5). Exocrine part was arranged in form of serous tubuloacinar glands that occupied a larger area of pancreas and these tubuloacinar glands consist mainly of mutable number of acinar cells which take the form pyramidal or tall columnar in shape having basophilic base and many apical acidophilic granules (Fig. 6). Some of centro acinar cells without granules were observed in the lumen of the acinus as the beginning cells of the intercalated ducts.

Langerhans island is composed of different shapes and sizes of alpha and beta cells either mixed cells do not notice in the pancreas early hatching geese. Alpha islets bigger than beta does not have a distinctive border with the exocrine part while the beta islets were arising from surrounding secretory acini by delicate collagenous fibers; also, there were few fibers within islets tissue (Fig. 7).

Intercalated ducts and interlobular ducts lined by thin layer of simple to stratified columnar epithelium and surrounded by connective tissue. In addition to this, the smooth muscle surrounding both the main pancreatic duct and interlobular ducts. Externally to these smooth muscle fibers, there were connective tissues of the tunica adventitia.

(Table 1) showed the pographic measurements including weight and length of pancreas lobes, n=10, M± SE)

Anatomical traits	Mean ± S.D
Pancreas weight	3.721± 0.06
Dorsal lobe weight	2.085± 0.02
Ventral lobe weight	1.576± 0.02
Third lobe weight	0.027± 0.02
Splenic lobe weight	0.033± 0.01
Length of dorsal lobe	2.33 ± 0.05
Length of ventral lobe	2.388± 0.03
Length of splenic lobe	1.13±0.03
Length of third lobe	1.02± 0.02

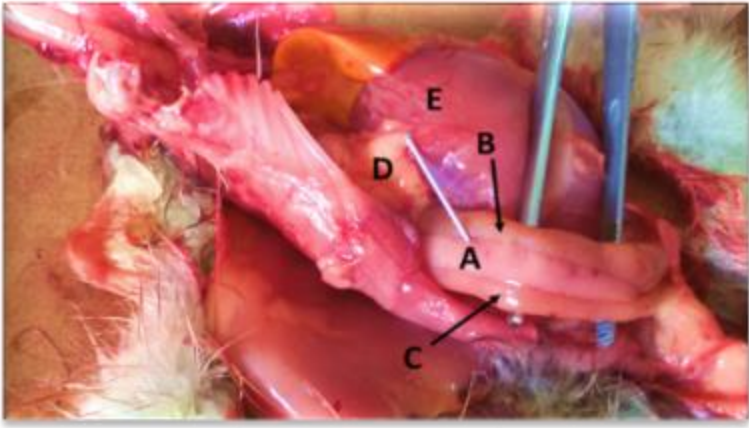
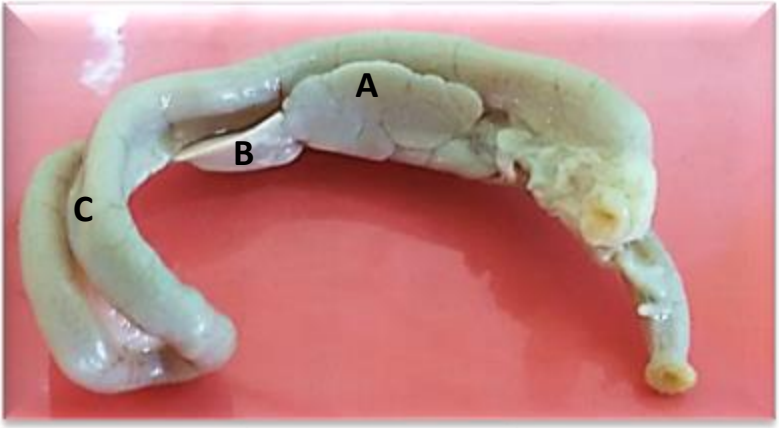


Fig (1) Photograph section ventral view anatomical position.

**A- Ventral lobe of pancreas, B-Proximal lobe of duodenum
C- Distal lobe of duodenum, D- Mesentery pancreatic duodenal ligament, E- Gizzard**



(2) Photograph section anatomical position, shape and color of pancreas

**A- Ventral lobe of pancreas, B- Splenic lobe,
C- Lobes of duodenum**

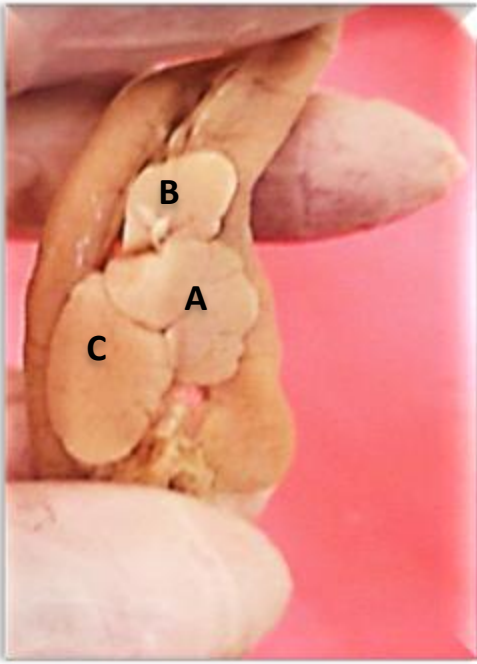


Fig. (3) Photograph anatomical section, lobulation of pancreas

A- Ventral lobe of pancreas, B- Splenic lobe, C-Third lobe

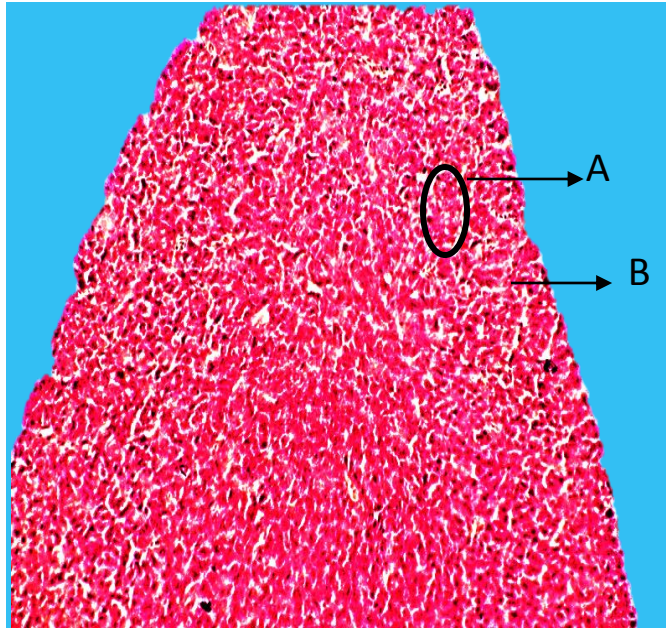


Fig. (4) Photomicroscope illustrate (H&E X40)

A- Lobules, B- Septa

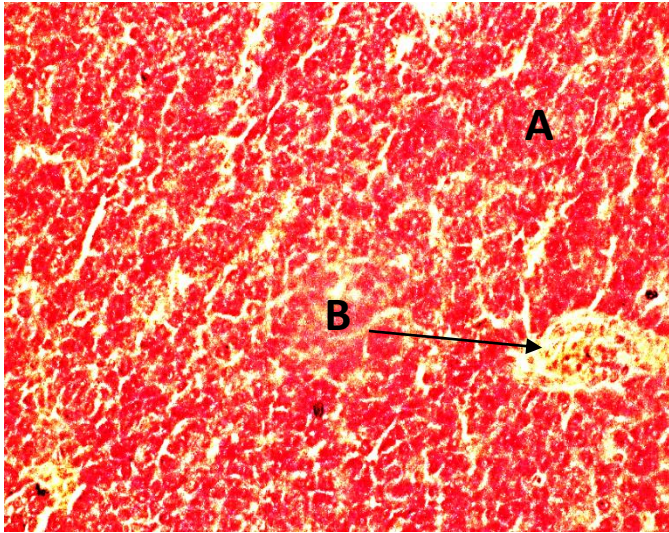


Fig. (5) Photomicroscope illustrate (PAS X20)

A- Exocrine part, B- The islands of langerhans

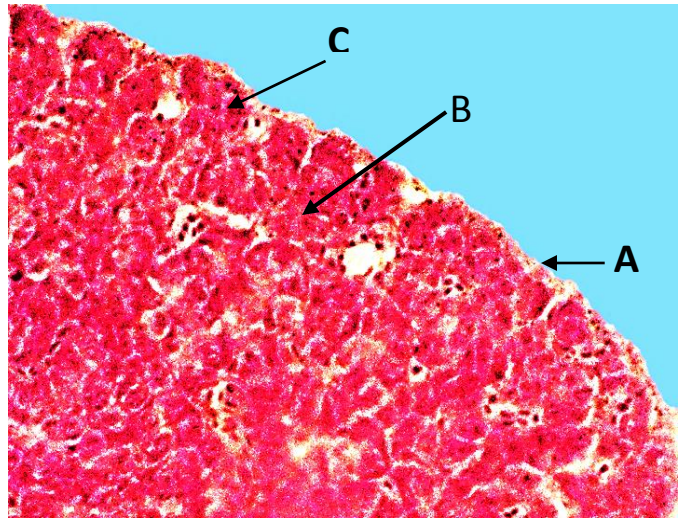


Fig. (6) Photomicroscope illustrate (H&E, X20)

A- Thin connective tissue capsule, B- centro acinar cells C- acinar cells

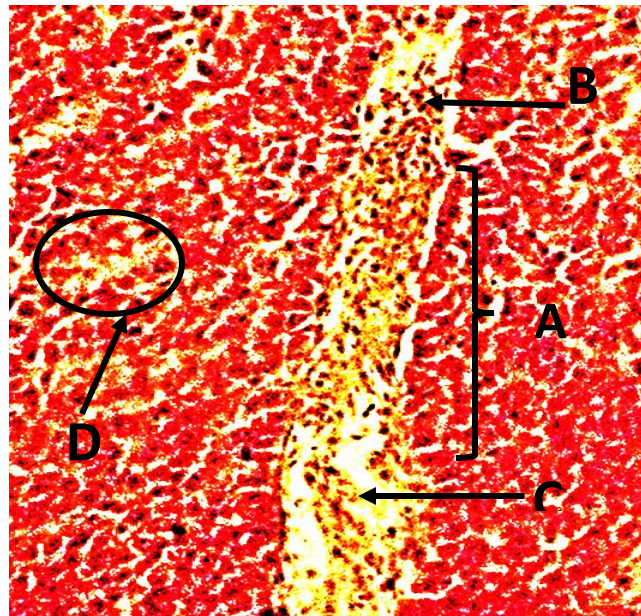


Fig. (7) Photomicroscope illustrate (PAS, X10)

A. Alpha islets, B. alpha cell, C- reticular fiber, D- Beta islet

Discussion

The anatomical studies demonstrates pancreas of early hatched goose it is a vital lobulated organ consist of four lobes located between the descending and the ascending duodenal loops and not full the space between the two limbs of duodenum, this finding is in agreement with the result of (16) , (17) and (18) but disagreement with the (19), who said that the lobes of pancreas were very short and have a gap between the duodenal limbs, also disagreement with the (20) who reported the pancreas of ducks has two lobes and the dorsal lobe is divided into three distinct segments.

The histological study observed exocrine part consist of tubuloacinar glands that occupied larger area from the parenchyma of pancreas; the present observations are consistence with those observations of (19), (21) and (22) we are found that the exocrine portion was composed of acini and ducts.

Also histological study demonstrate the islands of langerhans consisted of alpha or beta cell while mixed islets were not observed; these data disagreement with results of (23) and (24) were demonstrated islands of langerhans containing alpha, beta and delta cells.

The result of this study showed the main excretory ducts were lined by simple to stratified columnar epithelium, this result agreed with the (21) in duck. These ducts have inner longitudinal and outer circular muscle layers surrounded by the externally connective tissue and nerve fibers enter the parenchyma of glands along connective tissues, this results enhanced with (25) in duck.

Reference

- 1- Gulmez, N., Kocamis, H., and Aslan, S. et al.,** (2004): Immunocytochemical distribution of cells containing insulin, glucagon and somatostatin in the goose (*Anser anser*) pancreas. *Turk. J. Vet. Anim. Sci.* 28, 403-407.
- 2- Mourot, J., Guy, G., Lagarrigue, s., Peiniau, P., and Hermier, D.,** (2000): Role of hepatic lipogenesis in the susceptibility to fatty liver in the goose (*Anser anser*). *Comp. Biochem. Physiol part B: Biochem. Mol. Biol.* 126, 81-87.
- 3- Shafey, A.,** (2006): Some comparative anatomical studies on the stomach, intestine and liver in .ducks, chicken and pigeon. Ph.D. thesis. Benha University
- 4- IUCN,** 2007. 2007. *IUCN red list of threatened species.* www.iucnredlist.org>. (downloaded on June, 07, 2008)
- 5- Kim, A., Miller, K., Kilimnik, G., Wojcik, P., and Hara, M.,** (2009): Islet architecture: A comparative study. *Islets*, 1, 129-136.
- 6- Gussekloo, S.,** (2006): Feeding structures in birds. In, feeding in domestic vertebrates: from structure to behaviour. Edn V. Bels. Wallingford, UK, Combridge
- 7- Banks, W.,** (1993): Applied veterinary histology. Williams & Wilkins, Baltimore. 195-197.
- 8- Motta, M.P., Macchiarelli, G., Nottolas, A., and Correr, .,** (1997): Histology of the exocrine pancreas. *Microsc. Res. Tech.* 37, 384-398.
- 9- Nascimento, A.A., Sales, A., Cardo, T.R.D., Penhero, N.L. and Mendes, R.M.M.,** (2007): Immunocytochemical study of the distribution of endocrine cells in the Pancreas of the Brazilian sparrow species. *Braz. J. Biol.*, 67(4):735-740
- 10- Bayrakdar, A., Yaman, M., Atalar, O., Gencer Tarakci, B., and Ceribasi, S.,** (2011): Distribution of neuropeptides in endocrine and exocrine pancreas of long-legged buzzard (*Buteo rufinus*): An immunohistochemical study. *Regul Pept.* 166, 121-127, 2011.

- 11- Simsek, N., Bayraktaroglu, AG. and Altunay, H.,** (2009): Localization of insulin immunopositive cells and histochemical structure of the pancreas in falcons (*Falco anaumanni*). *Ankara Univ Vet Fak Derg*, 56, 241-247.
- 12-Steiner, DJ., Kim, A.,and Miller, K.,** (2010): Pancreatic islet plasticity: Interspecies comparison of islet architecture and composition. *Islets*, 2, 135-145.
- 13- Gulmez, N .,** (2003):Are gland present in Goose pancreatic Ducts? A light microscope study. *Jop.J.pancreas (Online)*, 4(3): 125_128.
- 14- Luna, L. G.,** (1968): Manul of histological staining methods of armed forces institute of pathology.three edition .New York, U.S.A. pp: 39-110.
- 15- Kiernan, A. J.,** (2003): Theory and practice in histology and histochemical methods.Oxford: Pergamon Press.35-6.
- 16 - AL-Hathry, S .A.,** (2012):Histological study of Alpha cells,Beta cells and Delta cells on pancreas of Abu- gura. *J.Coll.Edu. .Univ.Thi-Qar.,* 2(2):16-21.
- 17- Khalid, K., Kadhim,I., Zuki A. B. Z ., Noordin,M. M., Babjee,M.A. and Zamri-Saad, M.,**(2010) .Morphological study of pancreatic duct in red jungle Fowl. *African Journal. Of Biotechnology* Vol. 9 (42), pp: 7209-7215.
- 18- SIMSEK, N., and ALABAY, B.,**(2008) : Light and electron microscopic examinations of the pancreas in quails (*Coturnix coturnix japonica*). *Revue Méd. Vét.,* 159, 4, 198-206.
- 19- Al-Agele, R., and Mohammed, F.,** (2012): Architecture Morphology and Histological Investigations of Pancreas in Golden Eagles (*Aquila Chrysaetos*). *Al-Anbar J. Vet. Sci.,* Vol.: 5 No. (2), 2012.
- 20. Mclish, R. D., and Eglitis, J. A.,** (1969): Distribution of the A and B cells and of the islet langerhans in duck pancreas. *Ohio. J. Sci.,* 69:285-293.
- 21- Das, A., Das, R.K.,and Parida, S.,** (2003): Histomorphological study on pancreas of duck (*Anas boscas*). *Indian J. Anim. Sci.* 73 (6): 598-599.
- 22 - Gencer, B. T., Yaman, M., and Bayrakdar, A.,** (2007): Immunohistochemical study on the endocrine cells in the pancreas of the Ostrich (*strohtio camellus*). *J.Anim.Vet. Adu.* 6:693-696.
- 23- Mensah-Brown, E.P.K., Bailey, T.A., Pallot, D.J. and Garner, A.,** (2004): Peptidergic hormones and neuropeptides and aminergic neurotransmitters of the pancreatic islets of the Houbara bustar (*Chlamydotis undulate*). *J. Anat.,* 196: 233-241.

24- Tarakcy, G.B., Yaman, M., Bayrakdar A. and Atlar, O., (2005): Immunohistochemical detection of Gonadotropin -releasing hormone (GnRH) in porcupine (*Hystri cristatax*) pancreas. J. Anim.Vet., 8: 747-74

25- Wang, B. G., Liang, H. Y. and Jie, Z., (2009): Duck pancreatic acinar cell as a unique model for independent cholinergic stimulation-secretion coupling. Cell Mol. Neurobiol., 29: 747-756.