

Effects of aqueous extract of *catechin* tea on some parameters of sperms and histopathological changes in testis of mice treated with Methotrexate (MTX)

Abbas Fadhil Daham and Haithem Auda Mohammed Al-Hilfi

Department of Surgery and Theriogenology, College of Veterinary Medicine,
University of Qadisiia

Abstract:

Methotrexate (MTX) is commonly used for the treatment of certain cancers including but not limited to leukemia, Hodgkin's disease and head and neck cancers and causes reproductive damage in mice. The aim of this research, is to study the effects of *catechin* aqueous extract on some parameters of sperms and histopathological changes in testis of mice treated with methotrexate. Thirty-two adult albino male mice were divided into four groups, (8 mice in each group) First group was (negative control) received normal saline intraperitoneally, while second group was treated with extract of *catechin* as positive control. The third group was treated with methotrexate (50 µg/kg). The fourth group was treated with methotrexate (50 µg/kg) also (ip) and extract of *catechin* 6g/kg for 21 days. The results showed significant (P<0.05) decrease in sperms motility , increased percentage of dead sperms and abnormalities of sperms in mice treated with MTX, there was significant (P<0.05) decrease in diameters of seminiferous tubules, primary spermatocytes and spermatids, increased interstitial spaces as compared with control, while in the second group result showed significant (P<0.05) increase in sperms motility , decreased percentage of dead and abnormalities of sperms and significant (P<0.05) increase in diameters of seminiferous tubules, primary spermatocytes and spermatids and decrease interstitial spaces compared with first and third groups.

تأثير مستخلص الشاي الأخضر المائي على بعض معايير النطف والتغيرات النسيجية
الامراضية لخصى الفئران المعاملة بعقار الميثوتركسيت

عباس فاضل دحام هيثم عودة محمد الحلفي

فرع الجراحة والتوليد ، كلية الطب البيطري ، جامعة القادسية

الخلاصة:

إن الاستخدام الشائع لعقار الميثوتركسيت هو لعلاج الأمراض السرطانية ، الهدف من هذا البحث هو دراسة تأثير المستخلص المائي للشاي الأخضر على بعض معايير النطف والتغيرات النسيجية المرضية لخصى الفئران المعاملة بالميثوتركسيت، قسم 32 ذكر ناضج من الفئران البيض إلى أربع مجاميع كل مجموعة تحتوي على 8 ذكور. تم إعطاء المجموعة الأولى (السيطرة السالبة) المحلول الملحي

الفسيلوجي في الخلب البريتوني ، بينما عوملت المجموعة الثانية (السيطرة الموجبة) بمستخلص الشاي الأخضر والمجموعة الثالثة بعقار الميثوتركسيت بجرعة 50 مايكرو غرام/كغم لمدة 21 يوما عن طريق الخلب البريتوني وأما المجموعة الرابعة فعوملت بعقار الميثوتركسيت بجرعة 50 مايكرو غرام/كغم عن طريق الخلب البريتوني وعولجت بالمستخلص المائي لنبات الشاي الأخضر لمدة 21 يوما. أظهرت النتائج انخفاضا معنويا في حيوية النطف ، وزيادة معنوية في نسب النطف الميئة والمشوهة وكذلك انخفاضا معنويا في أقطار النبيبات المنوية ، وخلايا النطف الأولية والنطف ، وزيادة في المسافات البينية للنبيبات المنوية لخصى الذكور المعاملة بالميثوتركسيت مقارنة مع مجموعة السيطرة السالبة، بينما أظهرت النتائج زيادة معنوية في حيوية النطف ، وانخفاضا معنويا في نسب النطف الميئة والمشوهة وكذلك انخفاضا معنويا في أقطار النبيبات المنوية ، وخلايا النطف الأولية والنطف ، ونقصانا في المسافات البينية للنبيبات المنوية لخصى الذكور في الفران المعالجة بالمستخلص المائي للشاي الأخضر مقارنة مع المجموعة الأولى والثالثة.

Introduction:

Catechins are polyphenolic plant metabolites that constitute about 25% of the dry weight of fresh tea leaf (1). The exact mechanism of action of green tea polyphenols remain obscure ,but it is known that these substances possess antioxidative capacity derived from their ability scavenge reactive oxygen species (ROS)and trap hydroxyl and peroxy radicals (2). ROS have a negative effect on sperm parameters. The sperm plasma membrane is very sensitive to the effect of ROS since it contains abundant unsaturated fatty acids. These unsaturated fatty acids create fluidity which is necessary for sperm motility and membrane fusion events such as the acrosome reaction and sperm-egg interaction. However, the unsaturated nature of these molecules predisposes them to ROS attack and ongoing lipid peroxidation throughout the sperm plasma membrane(3). An increase in the seminal ROS level has been reported in 40% of infertile men (4). Medical research has uncovered evidence that

catechins are beneficial for the good health of humans as well as plants. In laboratory tests, the catechins present in tea leaves have been shown to inhibit the growth of cancer cells in addition to this, they are able to prevent the activity of free radicals, the molecules which cause cellular damage that can lead to cancer(5). Condensed tannins from the bark contain gallic acid, (+) gallic acid, (-) epicatechin, (+) catechin and epigallocatechin, of which gallic acid, (-) epicatechin and catechin (are primarily responsible for inhibiting the generation of chemiluminescence by activated human polymorphonuclear neutrophil (PMN), indicating that these compounds inhibit oxidative burst of PMN during inflammation(6).

Oxidative stress is known to play a major role in the etiology of the defective sperm function via mechanisms involving the induction of peroxidative damage to the plasma membrane, a subsequent reduction of sperm motility and

decline in cell quality which results in insufficient numbers of viable spermatozoa and fertility(7). Multiple pharmacological effects of flavonoids have been reported, including vascular protection, anti-inflammatory, antitumor and anti-hypertension activities. Flavonoids also possess free radical-scavenging abilities, and their anti-radical property is directed toward $\cdot\text{OH}$ and O_2^- , which are highly reactive oxygen species implicated in the initiation of lipid peroxidation(8). Antioxidants protect cells and tissues against free radical which caused oxidative damage and injury. Green tea's antioxidant effects seem to be dependent upon the polyphenol (Catechin) fraction. Several epidemiological and in vitro studies suggest that Catechins have beneficial effects on human health, serving to protect against congestive heart failure, cancer, myoglobinuric acute renal failure, reduce the incidence of myocardial ischemia and the risk of ischemic heart disease(9). (-)-catechin might be potent neuroprotectants(10).

Clinically, Methotrexate is used alone or with other agents to treat some types of cancers, to treat severe psoriasis, and rheumatoid arthritis. Methotrexate is a cytotoxic agent, and in the work place, should be considered a potential occupational reproductive hazard, harmful to the fetus, and a potential human carcinogen. Based on clinical use, possible target organs may include the bone marrow, gastrointestinal

system, central nervous system, cardiovascular system, lungs, liver, kidney, skin, gonads, and the fetus (11). Methotrexate may cause primary infertility. This phenomenon may be the result of an effect on the hypothalamic-pituitary-gonadal axis or a direct toxic effect on the gonads(3). Methotrexate is a mild immunosuppressant that also exhibits anti-inflammatory activity. Methotrexate is commonly used for the treatment of certain cancers including but not limited to leukemia, Hodgkin's disease and head and neck cancers. In these illnesses, methotrexate is used in very large doses so that it interferes with the reproduction of the cancer cells. Methotrexate is used in much smaller doses for the treatment of rheumatoid arthritis, Crohn's disease and psoriasis (12).

The drug MTX inhibits DNA replication by binding to the enzyme dihydrofolate reductase, thus preventing the synthesis of purines, thymidilate, and glycine, leading to eventual cell death (13). Methotrexate is known to be teratogenic in women, but few data are available on the effects of methotrexate on male reproductive capability. Studies in animals have shown altered spermatogenesis, cytotoxicity and degeneration of spermatocytes, Sertoli cells, and Leydig cells(14,15). The aims of this work is to study the effects of catechin extract on some parameters of sperms and some histopatho-

logical changes on mice testes treated with methotrexate.

Materials and methods:

Plant material

Catechin leaf was purchased from the local market. The leafs were cleaned and finely powdered by using a coffee grinder. Fifty grams of the seed powder were extracted for three hours in 250 ml of the water using the soxhlet apparatus and the source of heating was a warm water bath (45°C). The obtained seed extract solution was then evaporated at 45°C using a rotary evaporator, and the resultant crude extract was frozen at -20°C until use to prepare the required doses and concentrations (15) the extract was mixed with normal saline (1% w/v) and intraperitoneally injected in the male mice at dose 6g/kg body weight.

Animals and treatment :

Thirty two adult albino male mice (30-36 gm) were purchased from Biotechnology Research Center and maintained on a 14:10-hour light dark cycle in the animal house, control and treated mice were provided with food and water *ad libitum*. One week after arrival, males were randomly divided into four groups, containing 8 mice in each group, first group negative control intraperitoneally received normal saline. Second group treated with *catechin* as a positive control group While the third group was treated with methotrexate in dose 50 µg/kg, for 35 days administration

intraperitoneally (ip). And the fourth group was treated (ip) with methotrexate in dose 50 µg/kg, and extract of tea and *catechin* tea in dose 6g/kg for 35 days. Animals in each group were sacrificed by cervical dislocation. Testes fixed with Bouin fluid (BDH Inc, Toronto, Canada). Spermatozoa were obtained from the two tails of epididymides by mincing in 500 µl TCM-199, and maintained at 37°C in 5% CO₂ incubator and measured the percentages of motility, dead and abnormalities of spermatozoa.

Histological Examinations:

The perfuse-fixed testes placed in Bouin fluid overnight, and processed for routine paraffin embedding. The testes were cut into 5-µm sections. Three serial sections per testes were mounted on slides, deparaffinized, rehydrated, and stained with hematoxyline - eosin stain. Sections of the testes were examined by light microscopy seminiferous tubules, interstitial spaces, primary spermatocytes and spermatids diameters were assessed in each testes using a previously calibrated Micrometers (Ocular micrometer, Stage micrometer).

The diameter of 25 seminiferous tubules was measured in 5 fields (5 seminiferous tubules per field). In similar manner diameter of primary spermatocytes, spermatids, leydig cells were measured in 5 fields and the mean value of each was calculated. The interstitial space observed between seminiferous

tubules measured by using the ocular micrometer.

Microscopical examination:

Spermatozoa were assessed according to WHO laboratory manual (16) for viability, percentage dead/live spermatozoa, motility and abnormalities.

Statistical analysis

Statistical analysis was performed to compare two different groups by using ANOVA-test. Statistical significance was determined at $P < 0.05$ (17).

Results and discussion:

Methotrexate is a well-known anti-cancer agent used for the treatment of malignant and non-malignant conditions. In recent years, large number of reports has

been published on potential gonadal damage. In this study the results showed significant decreased of motility, and significant increase in percentage of dead sperms and abnormalities of sperms (Figure.1), in the groups treated with MTX compared with negative control group which showed normal sperms (Figure.2) and (table 1). While there is significant increase of motility, and significant decrease in percentage of dead sperms and abnormalities of sperms (Figure.1) in the group treated with catechin extract (positive control) and the group treated with MTX+ catechin (the fourth group) compared with negative control (the first group) and the group treated with MTX (the third group).

Table 1: Percentage of sperms motility, dead sperms, sperm abnormalities in treated and control groups.

Groups	Motility of sperms (%) (mean±SD)	Dead sperms (%) (mean±SD)	Abnormalities of sperms (%) (mean±SD)
Negative Control	A 75±6.43	A 22.41±3.33	AB 16.73±4.00
Positive control	B 85±4.22	B 17.57±2.61	B 12.42±3.63
Treated with 50 µg of MTX	C 60±7.12	C 30.46±4.89	C 29.40±5.02
Treated with 50 µg of MTX + catechin tea extract	AB 80±6.40	A 23.78±5.03	A 17.56±4.83

Differences A, B are significant ($P < 0.05$) to comparison rows

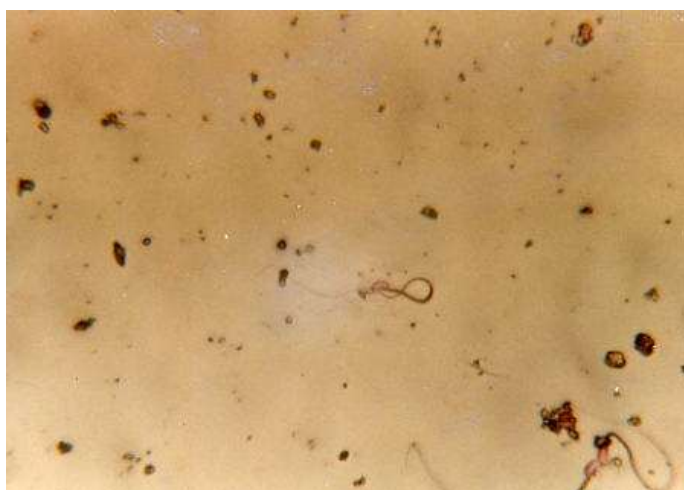

Figure 1: Showed abnormal sperms treated with MTX from treated groups (E X40)

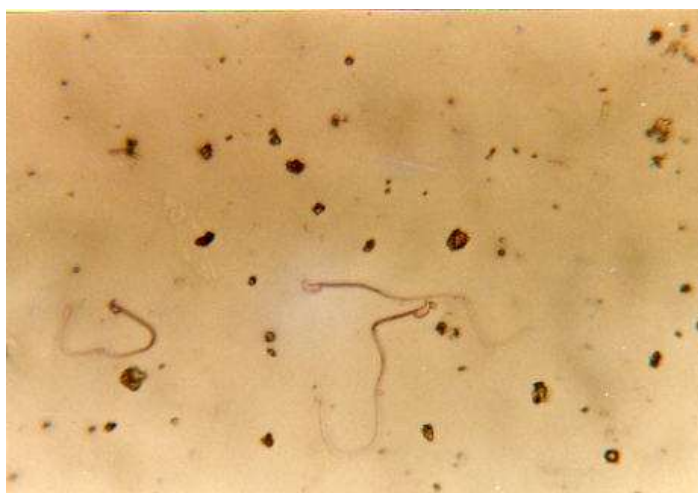

Figure 2: Showed normal sperms treated with normal saline from control group(E X40)

Administration of MTX is known to cause reproductive damage, including decreased epididymal and testicular weights, and reduced epididymal sperm counts and fertility(18). Histopathology of the testis is characterized by vacuolization of Sertoli cells, and sloughing of elongating spermatids and spermatocytes when damage is severe (19). A corresponding decrease in the number of microtubules in Sertoli cells after MTX treatment has been observed

using electron microscopy and immunohistological techniques (20). MTX treatment caused abnormal sperms morphology. The male reproductive function is under hormonal control ,spermatogenic process is under control of follicular stimulating hormone (FSH) and testosterone (21),while the formation of type A spermatogonia and conversion of primary spermatocyte into secondary spermatocyte (Meiosis I) are dependent on testosterone and the final step of

maturation of spermatids are dependent on FSH (22), so the abnormal sperm morphology may reflect an abnormal intratesticular maturation as a result of drug treatment(23), also the drug induce an alteration in androgen secretion that usually produce changes in the reproductive system ,such changes might include the production of abnormal sperms (24),also any effect on spermatogenesis lead to production of abnormal sperms(25). The decreasing in the abnormalities of sperms (head and tail) after treatment with plant extract occur when the sperms occur in the spermatogonia stage and before mitotic division which represent a source of sperms , and this will be agreement with AL-Rubia , (25) and AL-Rubia , (26) in which this extract do not contain any mutagenic agents , Wyrobek and Bruce , (27) pointed that these mutagenic agent can induce the abnormalities in sperms head and tail while non-mutagenic agent do not induce these abnormalities in addition to catechin ability in antioxidant protection against sperm damage (7 ,9). This test represent a more sensitive test for detection the mutagenic compounds .Or the decreasing in the sperms head and tail abnormalities may be returned to that these extracts have protective effectives in germ stem cells (spermatogonia) which act as a source of all sperms (28).Catechin may be used as antioxidant for reducing sperm abnormality and improving semen

quality in boar semen(7). This protection of Catechin was demonstrated by the induction of the antioxidant enzymes systems to increase the disposal of overproduction reactive free oxygen radicals (9) .

The results showed significant decrease in diameters of seminiferous tubules (Table 2, Fig.4) , primary spermatocytes, spermatids (Table 3) and increase in interstitial space (Table 2; Fig.4) when treated with MTX compared with negative control group (Fig.3) Which is due to antimitoic activity of the drug, The diameter of Leydig cells (Table 3) in the present study did not reveal any alteration after MTX administration with respect to controls.(Fig.5).While the results of mice treated with catechin extract (positive control) showed significant increased in diameters of seminiferous tubules (Table 2), primary spermatocytes, spermatids (Table 3) and decrease in interstitial space (Table 2) where compared with first and third groups.

Methotrexate, an immunosuppressive drug used to treat cancer, psoriasis, and rheumatic diseases, it is a folic acid antagonist that binds to the enzyme dihydrofolate reductase. This inhibits synthesis of thymidylate, serine, and methionine, which disrupts synthesis of DNA, RNA, and protein and leads to cell death (29).

In the present study, the size of cellular contents of seminiferous tubules were altered significantly,

that may be because primary spermatocytes and spermatids failed to replicate DNA due to inhibition of an essential enzyme dihydrofolate reductase required for normal DNA synthesis. Therefore, it can be concluded that these qualitative and quantitative changes in male gonads may alter the reproductive performance of animals, if not reversible in nature. However,

further study is required at ultra-structural and molecular level to explore the mechanism of action of Methotrexate (30). Improved results after treated with catechin may be due to the antioxidant property of catechin antioxidative capacity derived from their ability scavenge reactive oxygen species (ROS) and trap hydroxyl and peroxy radicals (2, 9).

Table 2: Diameter of seminiferous tubules and interstitial space in both treated and control groups.

Groups	Diameter of seminiferous tubules (μm) (mean \pm SD)	Interstitial space (μm) (mean \pm SD)
Negative Control	A 218.61 \pm 10.12	AB 21.40 \pm 3.07
Positive control	B 234.70 \pm 14.02	B 17.83 \pm 2.24
Treated with 50 μg of MTX	C 174.66 \pm 18.63	C 44.56 \pm 4.83
Treated with 50 μg of MTX + catechin tea extract	A 211.65 \pm 11.23	A 23.42 \pm 3.89

Differences A, B are significant ($P < 0.05$) to compression rows

Table 3: Diameter of primary spermatocytes, spermatids and leydig cells in treated and control groups.

Groups	Primary spermatocytes (μm) (mean \pm SD)	Spermatids (μm) (mean \pm SD)	Leydig cells (μm) (mean \pm SD)
Negative Control	A 4.96 \pm 0.92	A 4.02 \pm 1.02	A 4.30 \pm 0.91
Positive control	B 6.01 \pm 0.78	A 4.91 \pm 0.92	B 5.03 \pm 1.04
Treated with 50 μg of MTX	C 3.40 \pm 0.93	B 2.04 \pm 0.78	C 3.22 \pm 0.87
Treated with 50 μg of MTX + catechin tea extract	A 5.01 \pm 0.84	A 3.94 \pm 0.54	A 4.24 \pm 0.62

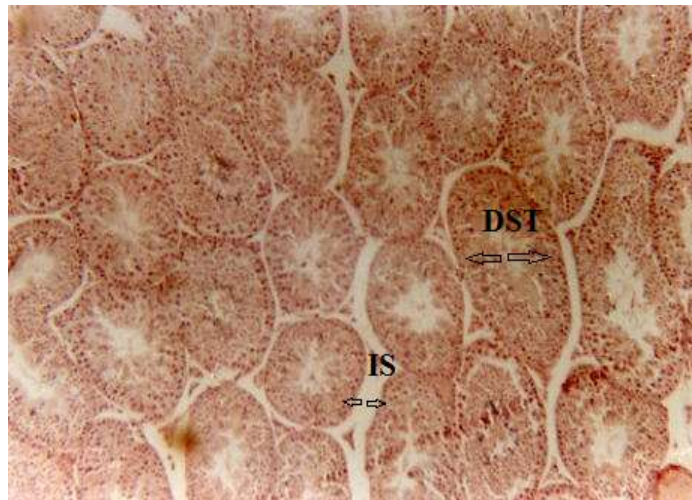


Figure 3:Photomicrograph of testes of mice (control group) showing normal structure of proximal seminiferous tubules. (DST- Diameter of Seminiferous tubules, IS- Interstitial space) (H and E X 10).

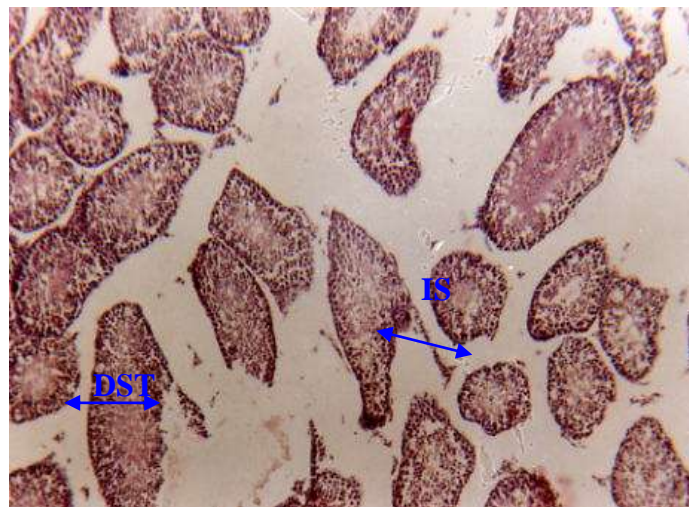


Figure 4:Photomicrograph of testes of mice (treated group) showing decrease in diameter of middle seminiferous tubules (DST) and increase of interstitial space (IS) (H and E X 10).

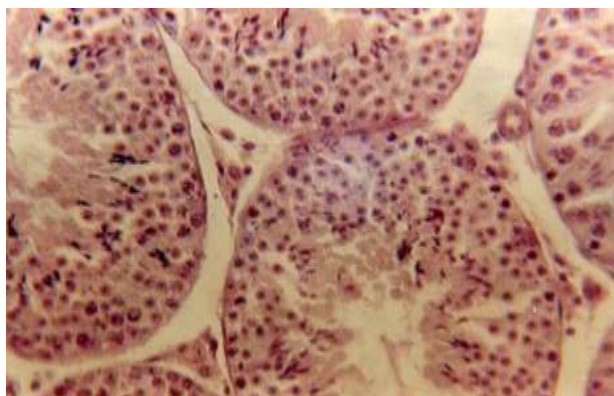


Figure 5:Photomicrograph of testes of mice (control group) showing normal structure of Leydig cells (LSC). (H & E X 40)

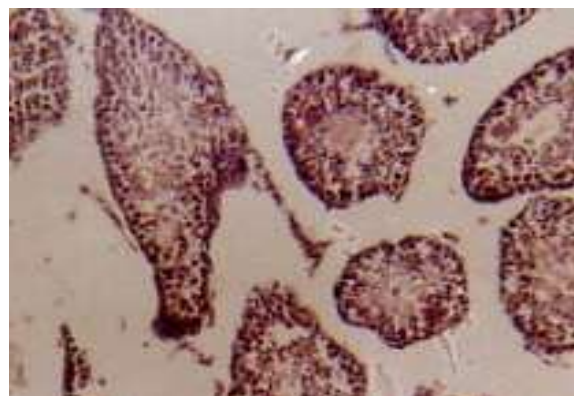


Figure 6:Photomicrograph of testes of mice (treated group) showing the heterogeneous population of Leydig cells with alterations (ALSC) in morphological features. (H & E X 40)

References:

1. Chandra, A . K . , ,Sinha ,S . ,and Choudhury ,S. R. 2010. Thyroxin induced stress and its possible prevention by catechin . *Indi. J. Experiment. Biol.* 48: 559-565.
2. Sato, K . Sukoda ,K ., Tanigaki ,R . Tagima ,H . Makabayadi , A . Yoshimura ,Y . and Hasoi , Y . 2010 . Green tea extracts attenuate doxorubicin- induced spermatogenic disorders in conjunction with higher telomerase activity in mice *J. Assiss. Reprod. Genet.*
- 3.Lewis SE, Sterling ES, Young IS, Thompson W.1997. Comparison of individual antioxidants of sperm and seminal plasma in fertile and infertile men. *Fertil. Steril.*; 67: 142-147.cited by Olayemi,F.O.2010.
4. Olayemi,F.O.2010.Areview on some causes of male infertility. *Afric. J. Bioech.*; 9 (20): 2834-2842.
5. Lioyd , E . 2010. What are catechins . Lindsay D. Conjecture Corporation.
6. Biswas ,K . Chattobadhyay , I . , Banerjee , K . and Bandyopadhyay , U . 2002 . Biological activities and medicinal properties of neem (*Azadirachta indica*) . *Current Sci.*; 82 (11).
7. Boonsorn, T., Kongbuntad ,W., Narkkong, N. and Aengwanich,W. 2010.effects of catechin addition to extender on sperm quality and lipid peroxidation in boar semen.Americ.-Euras. *J. Agric. &Environ.Sci.*;7 (3) :283-288.
8. Nagata , H ., Takekoshi , S . Takagi , T . Honma , T . and Wtanabe , K . 1999 . Antioxidative action of flavonoid , quercetin and catechin, mediated by the activation of glutathione peroxidase .*Tokai J. Exp. Clin . Med .* ; 24 (1) : 1-11.

9. AbdElDayem , S . , Foda , F . Helal , M . and Zaazaa , A . 2010 . The role of catechin against doxorubicin- induced cardiotoxicity in Ehrlich Ascites Carcinoma cells (EAC) bearing mice .*J. Americ . Sci .*
10. Li,G., Min,B., Zheng, C. ,Lee, J. , Oh, S., Ahn, K. and Lee, H. 2005. Neuroprotective and free radical scavenging activities of phenolic compounds from *Hovenia dulcis*. *Arch. Pharm. Res.*; 28(7):804-809.
11. Hospira Inc. Material safety data sheet. 2009. Global Occupational Toxicology.
12. Chabner BA, Ryan DP, Ares LP, Carbonero RG, Calabresi P. 2002. Antineoplastic agent. Goodman and Gilman's the pharmacological basis of therapeutics. 10th edition. *New york .*; 1399-404.
13. Donehower, R. C., C. E. Meyers, and B. A. Chabner. 1979. New developments on the mechanism of action of antineoplastic drugs. *Life Sci.*; 25:1-14.cited by Kleinberger, et al.1986.
14. Saxena AK , Dhungel S , Bhattacharya S et al. 2004. Effect of chronic low dose of methotrexate on cellular proliferation during spermatogenesis in rats. *Arch Androl .* ; 50 : 33 – 5 .
15. Shrestha S , Dhungel S , Saxena AK et al. 2007. Effect of methotrexate (MTX) administration on spermatogenesis: an experimental on animal model . *Nepal Med. Coll. J.*; 9 : 230 – 3 .
16. WHO Laboratory manual for the examination of human semen and sperm – cervical mucus interaction. 1992. Third Edition. Cambridge University press.
17. Al-Mohammed, N.T.; Al-Rawi, K.M.; Younis, M.A. and Al-Morani, W.K. (1986). Principle of Statistics. J. Al-Mousl University (in Arabic).
18. Saxena AK, Dhungel S, Bhattacharya S, Jha CB, Srivastava AK. 2004.Effect of chronic low dose of methotrexate on cellular proliferation during spermatogenesis in rat. *Arch Androl*; 50: 33-5.
19. Sussman A, Leonard JM. 1980.Psoriasis, Methotrexate and oligospermia. *Arch dermatol* ; 116: 215-7.
20. Koehler M, Waldherr R, Ludwig R, Heinrich U, Brandeis WE. 1986.Effects of methotrexate on rabbit testes. Part 1: Morphological changes. *Pediatr Hematol Oncol*; 3: 325-34.
21. Ganong, W.F. 1991. Review of medical physiology .Connecticut: *Appleton and lauge* ; 401:94-95.
22. Acosta, A.; Ochninger, S.;Morshed ,M; Swanson , R.; Scott ; R.; and Irianni ,F. 1988 . Assisted reproduction in the diagnosis and treatment of the male factor . *Obstet and Gynecol Surrey* ; 44:1-17.

23. Tesarik , J. ; Bault , A; and Testart , J. 1992. Effect of pentoxifylline on sperm movement characteristics in normospermic and asthenozoospermic specimens , *Hum . Rep .* , 7:1257 – 1263.
24. Arab, Y.M.; AL-Flaugy , S.N. ; and Karmasha , F.N. 1989 . Anatomy and physiology , Ministry of High Education and Scientific Research , Baghdad University , AL-Hekma house .
25. AL-Rubaie, A.H.M. 1999. The effect of garlic extract on the inhibiting of mutagenic action of zinc phosphide and gamma ray. In albino mice .Ph.D. Thesis ,College of Science, University of Babylon.
26. AL-Rubaie, F.A.A. 2000. A study of the mutagenic and anti mutagenic ability of some Iraqi medicinal plants in albino mice. M.Sc. Thesis ,College of Education, (IBn-ALhatham), University of Baghdad .
27. Wyrobek, A.J.; and Bruce , W.R. 1975. Chemical induction of sperm abnormalities in mice. *Proc. Natl. Acad. Sci. U.S.A.*, 72:4425-4429.
- 28- Ben Arush MW, Solt I, Lightman A, Linn S, Kuten A. 2000. Male gonadal function in survivors of childhood Hodgkin and non-Hodgkin lymphoma. *Pediatr Hematol Oncol.*;17:239-45.
29. Grunnet E, Nyfors A, Hansen KB. 1977. Studies of human semen in topical corticosteroid-treated and in methotrexate-treated psoriatics. *Dermatologica*; 154:78-84.
30. Meenl Kumar, Ravindar Samarth, Madhu Kumar, Senthamil R. Selvn, Begraj Saharan and Ashok Kumr. 2007. Protective effect of adhatoda vasci nees against radiation-induced damage at cellular, biochemical and chromosomal levels in swiss lbino mice. *Oxford.J.*; 4:343-350.