

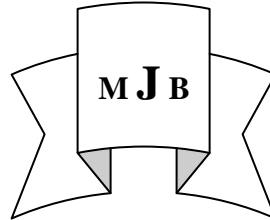
Incidental Meniscal Findings on Knee MRI in Al-Najaf City

Nada R. Alharis^a

Amjaad Majeed Hameed^b

^a College of Medicine, University of Kufa, Kufa, Iraq.

^b College of Medicine, Al-Qadisiya University, Dewania. Iraq.



Abstract

Background Magnetic resonance imaging (MRI) of the knee is often performed in patients who have knee symptoms of unclear cause. When meniscal tears are found, it is commonly assumed that the symptoms are related to these. However there is a paucity of data regarding the prevalence of meniscal damage in general population and the association of meniscus tears with the knee symptoms.

Object to evaluate the prevalence of meniscal tear on MRI scans in the knees of asymptomatic patients.

Patients and Methods We performed MRI examinations on 80 asymptomatic patients (38 females and 42 males), who were 35-60 years and ambulatory. We assessed the integrity of the menisci in the right knee joint.

Results The prevalence of meniscal tears in the Rt.knee joints as detected on MRI was 28.8%. Damage to the medial meniscus was more common than to the lateral meniscus 69.5%. The prevalence of meniscal damage increased with increasing age in both sexes.

Conclusions On MRI examination of the knee joint, many people without knee pain have meniscal signal changes. Clinical correlation is essential to determine the importance of these signal abnormalities on magnetic resonance images especially in subjects older than 50 years, a significant number of meniscal tears must be expected. This shows the potential danger of the use of MRI alone as a basis for the determination of surgical intervention.

الرنين المغناطيسي لمفصل الركبة عند أناس غير مصابين بآلام الركبة

العلاقة بين آلام الركبة والتغيرات التي تطرأ على شكل الغضاريف الهلالية (الانسيه والوحشية) علاقة مثيرة للجدل والخلاف، تبرز أهميتها عند المرضى الذين يحتاجون إلى تدخل جراحي، فكان الهدف من الدراسة هو بيان مدى انتشار هذه التغيرات عند أناس لا يعانون من آلام الركبة.

أجريت الدراسة في قسم الرنين المغناطيسي في م.الزهراء (ع) التعليمي في النجف الاشرف للفترة من اذار ٢٠٠٩ إلى حزيران ٢٠١١ وقد تم فحص ٨٠ شخص (٣٨ انثى ٤٢ ذكر) تراوحت أعمارهم بين ٣٥ و ٦٠ سنة.

أظهرت الدراسة أن ٢١% غضاريف طبيعية تماماً بينما ٢٨.٨% غير طبيعية وعلى مستويات مختلفة.

إن إيجادات مثل هذه التغيرات في شكل الغضروف عند المرضى الذين يشكون آلام الركبة كثيراً ما تكون صدفة متزامنة وليس سبباً رئيسياً لآلام الركبة مقارنة نتائج فحص الرنين المغناطيسي مع أحواله السريرية ضروريا للوصول إلى طرق ناجعة للعلاج.

Introduction

The menisci are two semilunar fibrocartilagenous discs located between the medial and lateral articular surfaces of the femur and tibia in each knee. Their key function are the transfer of weight and absorption of shock during dynamic movements of

the knee, thus protecting the cartilage in the joints [1-3].

A meniscal tear is a frequent orthopedic diagnosis and arthroscopic partial meniscectomy is the most frequent surgical procedure for high grade tears in patients 45 year of age or older. People in whom this procedure has been performed are at increased risk of knee

osteoarthritis ;which is one of the most common causes of musculoskeletal disability in developed countries.[4-6].

MRI of the knee is often performed in patients who have knee symptoms of unclear cause. When meniscal tears are found, it is commonly assumed that the symptoms are attributed to these. However there is a paucity of data regarding the prevalence of meniscal damage in the general population and the association of meniscal tear with knee symptoms and with radiographic evidence of osteoarthritis.[4-6].

MRI of the knee is widely used to diagnose damage to the menisci and clinicians often use the findings as a factor in determining whether a patient should undergo an arthroscopic meniscectomy[7]. Arthroscopy is considered the gold standard for the diagnosis of traumatic intra-articular knee lesions, however it is an invasive procedure that requires hospitalization and anesthesia ,thus presenting all the potential complications of a surgical procedure .In the past decades the diagnosis of meniscal lesion was limited to the clinical examination and standard radiographic evaluation. Over a long period of time arthrography had been used to augment the evaluation of ligamentous or meniscal conditions.[7,8].

The clinical examination often failed to produce exact results and false diagnosis rates between 40-85%. The clinical examination produced less true positive results compared to the MRI, the rate of true negative results was higher in MRI compared to the clinical diagnosis, false negative results could be found frequently in clinical diagnosis compared to the MRI [8-10].

Since its introduction in 1980s ,MRI has gained popularity as a diagnostic tool for musculoskeletal disorders .Many surgeons believe that MRI is an accurate, non invasive method to diagnose knee injuries and give

sufficient information to support decision for conservative treatment and save patient from unnecessary arthroscopy ,however there is a paucity of epidemiologic data on the prevalence of meniscal tears in the general population making it difficult to interpret the diagnostic information provided by MRI among persons who have symptoms that are possibly attributed to tears[11-14].

Schurz et al compare the results of the MRI with arthroscopic findings and found that the accuracy ,specificity ,sensitivity ,positive and negative predictive values are higher in MRI results than in the group of the clinical examination ,these results indicate that MRI is necessary to complete an exact clinical diagnosis in meniscus tear ,but surgery should only follow an MRI when positive clinical symptoms have been exactly identified.[15].

MRI is the most commonly used imaging modality in the evaluation of the knee joint and has an acceptable accuracy in the detection of meniscal and anterior cruciate ligament injuries. On the other hand, in case of coexistence of more than one knee pathology, decreased rates of accuracy of MRI have been reported.

Simultaneous injury to several supporting structures is relatively common in the knee ,for example in a study by Duncan et al of 317 skiers with anterior cruciate ligament tears,122 (38%) had concomitant medial collateral ligament injury while 50% of the patients also had meniscal tear[16].

Meniscus tears in knees with ligament injuries deserve special attention because the combination of meniscal and ligament tears frequently changes management and prognosis [17]. Posterior and peripheral lateral meniscal tears are far more common in knees with an anterior cruciate ligament tear.

Physicians interpreting MRI studies should be aware of these association

when an anterior cruciate ligament tear is detected on MRI study ,special attention should be paid to the posterior horn of lateral meniscus where a subtle peripheral tear may be present [18].

For many people active in sports ,injuries to the knee cause more problems than injuries to any other joint ,there is a high incidence of positive MRI findings in asymptomatic knees which can lead to arthroscopic surgery after a minor injury[15].

MRI is a valuable tool in evaluation of the knee ,it is often the test of choice for diagnosing or confirming derangements of the articular cartilage ,ligaments and tendons injuries ,meniscal tears ,joint effusions, bone marrow edema and cysts. The abnormalities seen on MRI are not always clinically significant ,which has encouraged clinicians to use MRI to support clinical examination findings rather than as the sole tool to diagnose injury[19].

Aim of the Study

to evaluate the prevalence of meniscal tear on MRI in asymptomatic persons.

Patients and Methods

This is a prospective study conducted through the period from March 2009 to June 2011 on 80 asymptomatic (no history of knee joint pain), patients (38 female and 42 male who were 40-60

years old) were referred to MRI unite at Al-zahraa Teaching Hospital in Najaf to perform examination other than that of the knee joint (e.g. : brain ,abdomen), their permission was taken for doing magnetic resonance imaging of the knee joint for research purposes.

All patients were questioned about history of swelling, mechanical symptoms, and instability. Each patient included in the study demonstrated painless full range of motion, no joint effusion ,no ligamentous instability.

We exclude unambulatory patients and patient with rheumatoid arthritis or terminal cancer.

MRI examination at Al-zahraa Teaching Hospital with 0.2 Tesla imagers/ Siemens medical system / the studies consisted of four spine echo sequences : a coronal localizer , a sagittal T2 (with and without fat suppression –SPIR) and T1 weighted images , technical specifications included a slice thickness of 3-4 mm. for sagittal and axial sequences and by using surface coil

We regarded an increased meniscal signals as indicative of a meniscal tear when it communicated with the inferior ,superior or free edges of the meniscal surface (or more than one of those) on at least two consecutive images (or for a radial tear if it was visible on both the coronal and sagittal images.

A standardized grading of the meniscal tear was used [15,20], ranging from I to IV (table 1).

Table 1 classification of meniscus tear by MRI

Grade	Signal intensity of the tear
I	Globular intensity, not adjacent to either articular surfaces.
II	Linear signal within the meniscus.
III	Linear signal that extends to either the superior or inferior articular surfaces.
IV	Meniscus fragmentation.

Results

In the 80 asymptomatic people who underwent MRI of the knee joint,

23 patients (28.8%) have abnormal meniscal signal intensity (table 2).

Table 2 Prevalence abnormal meniscal signal intensity on MRI scans in 80 asymptomatic subjects.

MR Finding	Subject no. (%)
Normal menisci	57 (71.2%)
Abnormal menisci	23 (28.8%)

Among those 23 patients, damage to the medial meniscus 69.5%(16 patients)

was more common than damage to the lateral meniscus 30.5(7 patients).

Table 3 Number of subjects with meniscus tears according to the grade and location of tear.

	Grade I no.(%)	Grade II no.(%)	Grade III no.(%)	Grade IV no.(%)
Medial meniscus	8(10%)	6(7.5%)	1(1.25%)	1(1.25%)
Lateral meniscus	4(5%)	3(3.75)	0	0

The posterior horn of the medial meniscus showed a significantly higher prevalence of degeneration than other parts of the meniscus ($P<01$). High grade signal changes are seen more in oldest age group.

Discussion

It is often difficult to state the diagnosis of meniscal tear only based on a clinical examination alone [21], and many patients nowadays already request an MRI evaluation. Prior to the widespread access and use of MRI arthroscopy had been advocated as a valuable diagnostic tool [22-24]. Newman et al recommended a conservative treatment for 4-6wks when unclear meniscal symptoms are present, but today many patients find such a delay unacceptable [25]. Various studies can be found in the literatures which compare the accuracy, specificity and sensitivity of MRI under standardized conditions and discuss the cost effectiveness of the MRI [26]. Regardless of the cost factor, the

number of ordered MRI investigations rises continuously year by year.

There is a high incidence of positive MRI findings in asymptomatic knees which can lead to arthroscopic surgery after a minor injury [27].

Boden et al showed that 16% of asymptomatic patients who underwent MRI showed meniscal abnormalities consistent with a meniscal tear, the incidence rising with the patient age [8]. In our study the prevalence of meniscal tear on 80 asymptomatic patients was 28.8%. Our results is in agreement to a study done by Kornick et al who studied 64 asymptomatic volunteers and reported that 25% of asymptomatic volunteers in the 2nd-8th decade of life had meniscus signal abnormalities which increased sharply with age [28]. The posterior horn of the medial meniscus had significantly higher prevalence of abnormalities, they conclude that there is a baseline prevalence of meniscus signal in the a symptomatic population.

In 1994 La Prade et al studied a group of 54 asymptomatic subjects with an

average age of 28.5 years, their prevalence of meniscus tear was 5.6% they conclude that clinicians should match clinical signs and symptoms with MRI before instituting surgical treatment [28]. The difference between our results and their results may be related to selection of patients, their number and their lifestyles (table 4). Lifestyle is an important entity regarding the presence of meniscal signals, Ludman did an MRI study on 24 knees of asymptomatic competitive collegiate gymnasts ages 18-24. The experimentally group of gymnasts had significantly different distribution of grade III intrameniscal signal changes, preferentially involving the lateral meniscus. Knowledge of these MRI appearance is important when evaluating the lateral menisci within this group of athletes to prevent unnecessary treatment or intervention [29].

Starting in the 3rd decade, there is an age dependent degeneration of the meniscus on the MRI, yet these patients are clinically asymptomatic.

It has not been shown that these MRI changes will become clinically symptomatic torn menisci. Runners and Joggers often can have a positive MRI yet be clinically asymptomatic [30].

In the 4th and 5th decades, patients frequently have a positive MRI of the meniscus, especially if there are existing degenerative changes due to old trauma, obesity, varus or valgus alignment of the knee and aging [30].

A study done by Gelb et al in 1996 comparing MRI and arthroscopy for their clinical value and cost-

effectiveness in 72 patients that group stated "we conclude that MRI is overused in the evaluation of knee disorders and is not a cost effective method for evaluating knee injuries when compared with a skilled examiners. Clinical assessment equals or surpasses the MRI in accuracy [31]. The current study showed high prevalence of meniscal signals in older age group in both sexes, this is comparable to Jerosch et al results who studied 82 asymptomatic patients and conclude that subjects older than 50 years presented with a significant number of meniscus tear. They make the statement that "this study shows the potential danger of the use of MRI alone as a basis of determination of surgical intervention [32].

We would prefer to have MRI reports describe meniscus changes by using the term "signal changes 1,2 and 3" rather than describing them as "tears".

A "tears" is a clinical pathological diagnosis.

At time, when the radiologist uses the term "tear" the patient is labeled with a diagnosis that may not be clinically correct.

Surgical results of arthroscopic meniscectomy are considerably different for a "traumatic tear" versus a "degenerative tear". Morrey at the Mayo clinic wrote an article on osteoarthritis and stated "arthroscopic treatment in degenerative joint disease is effective about 50-60% of the time and found that results of arthroscopic surgery on a "degenerative meniscus" are variable and at time, disappointing [30].

Table 4 Correlation between the results of the present study and other's studies.

Study	Total subject no.	Normal subject no.(%)	Abnormal no. (%)
Present study	80	57(71.2%)	23 (28.8%)
Kornick et al ⁽¹⁰⁾	64	48(75%)	16(25%)
LaPrade et al ⁽²⁹⁾	54	51(94.4%)	3(5.6%)
Boden et al ⁽⁸⁾	74	62(84%)	12 (16%)

Conclusion

On MRI examination of the knee joint , many people without knee pain has meniscal signal changes . Clinical correlation is essential to determine the importance of these signal abnormalities on magnetic resonance images especially in subjects older than 50 years , a significant number of meniscal tears” signal changes” must be expected .This shows the potential danger of the use of MRI alone as a basis for the determination of surgical intervention.

Recommendation

Further similar study is recommended by using more sensitive MRI with 0.2 Tesla imagers/ medical system

References

- 1-Brian E.Walczak,Patrick C. McCulloch, Richard W.Kang, Anthony Zelanzy,Fred Tedeschi,Brian J.Cole. abnormal findings on Knee MRI in asymptomatic NBA players . J Knee Surg. 2008; 21: 27-33.
- 2-Simon S.Boks, Dammis Vroegindewij, Sita M.A.Bierma-Zeinstra .MRI of the knee in asymptomatic adolescent swimmers:a controlled study, Br.J. Sports.Med.April 3,2011 .
- 3- Ricardo B.Soder ,Juliana D.Simoes,Janine B.Soder . MRI of the knee joint in asymptomatic adolescent soccer players :a controlled study ; AJR 2011; 196:W61-W65.
- 4-England M,Lohmander LS. Risk factors for symptomatic knee osteoarthritis fifteen to twenty-two years after meniscectomy. Arthritis Rheum 2004;50:2811-2819.
- 5-Laurence RC, Felson DT, Helmick CG. Estimates of the prevalence of arthritis and other rheumatic conditions in the united states. Arthritis Rheum 2008;58:26-35.
- 6-Lopez AD,Mathers CD, Ezzati M, Jamison DT, Murray CJ. Global and regional burden of disease and risk factors ,2001:systemic analysis of population health data .Lancet 2006;367: 1747-1757.
- 7-Martin E, Ali G, Daniel G, David J, Piran A. Incidental meniscal findings on knee MRI in middle aged and elderly persons. NEJM 2008; 359(11): 1108-1115.
- 8- Boden SD,Davis DO, dina TS,Patronas NJ,Wiesel SW. A prospective and blinded investigation of MRI of the knee ,abnormal findings in asymptomatic subjects .Clin Orthop. 1992;282:177-185.
- 9-Disler DG,Rechet MP,McCauley TR. MRI of articular cartilage .Skeletal Radiol.2000;29:367-377.
- 10-Kornick J, Trefelner E,McCarthy S, Lange R. Meniscal abnormalities in asymptomatic population at MR imaging. Radiology ,1990;177:463-465.
- 11-Steinbruck K, WiehmannJK, Examination of the knee joint.the value of clinical findings in arthroscopic control .Z Orthop 1988;126:289-295 .

- 12- Miller GK, A prospective study comparing the accuracy of the clinical diagnosis of meniscus tear with MRI and its effect on clinical outcome , Arthroscopy 1996;12:406-413.
- 13- Serhat A., Ersan A., Ihsan A., Kemal E. Knee joint examination by MRI : The correlation of pathology ,age , and sex .North Am J Med Sci 2010;2: 202-204.
- 14- Nikolaou VS, Chronopoulos E., Savvidou C. MRI efficacy in diagnosing internal lesions of the knee : a retrospective analysis . J Trauma Manag Outcomes 2008 ; 2:4.
- 15- Schurz M, Erdoes J.T., Petras N. The value of clinical examination and MRI versus intraoperative findings in the diagnosis of meniscal tear . SCRIPTA MEDICA (BRNO)-81(1) :3-12 April 2008.
- 16- Duncan JB., Hunter R, Prunell M. Meniscal injuries associated with acute anterior cruciate ligament tears in alpine skiers. Am J Sports Med 1995; 23:170-172.
- 17- Vincken PWJ, Ter Braak BPM, Arian R. Effectiveness of MRI in selection of patients for arthroscopy of the knee .Radiology 2002;233: 739-746.
- 18- Resnick D. Diagnosis of bone and joint disorders .In: Resnick D, eds. Diagnosis of bone and joint disorders .Philadelphia ,Pa: Saunders, 1995; 3135-3156.
- 19- Sher JS, Uribe JW, Posada A, Murphy BJ, Zlatkin MB. Abnormal findings on MRI of asymptomatic shoulder .J Bone Joint Surg Am. 1995;77:10-15.
- 20- Quinn SF, Brown TF. Meniscal tears diagnosed with MRI versus arthroscopy :how reliable as standard is arthroscopy? Radiology 1991;181:183.
- 21- Kozlowski B, Majewski A. Diagnostic errors in meniscus lesions. Beiter Orthop Traumatol 1982; 29(1): 11-16.
- 22- Suman RK, Stothe IG, Illingworth G. Diagnostic arthroscopy of the knee in children . J Bone Joint Surg Br. 1984; 66:535-540.
- 23- Matelic TM, Arnosson DD, Boyad DW Jr. Acute hemoarthrosis of the knee in children .Am J Sports Med. 1991 .
- 24- Ziv I, Carroll NC. The role of arthroscopy in children .J Pediatr Orthop. 1982; 2: 243-7.
- 25- Newman AP, Danials AU, Burks RT. Principles and decision making in meniscal surgery .Arthroscopy 1993;9:33-51.
- 26- Raunest J, Oberle K, Loehnert J, Hoetzing H. The clinical value of MRI in the evaluation of meniscal disorders . J Bone Joint Surg Am 1991 ; 73: 11-16.
- 27- Muellner T. The diagnosis of meniscal tears in athletes .Am J Sports Medicine 1997;25:7-12.
- 28- LaPrade RF, Burnett QM, Veenstra MA. The prevalence of abnormal MRI findings in asymptomatic knee with correlation of MRI to arthroscopic findings in symptomatic knees. Am J Sports Med. 22(6):739-745, Nov 1994.
- 29- Ludman CN, Hough DO . Silent meniscal abnormalities in athletes ;MRI of asymptomatic competitive gymnasts. Br J Sports Med 33(6):414-416.
- 30- Gary NG., Harvey S., Donald J. False positive MRI of the knee: a literature review study . Wisconsin Med J 2002;101,1: 35-38.
- 31- Gelb HJ, Glasgow SG, Sepaga AA. MRI of knee disorders .Clinical value and cost effectiveness in a sports medicine practice .Am J Sports Med. 24(1): 99-103, Jan 1996.
- 32- Jerosch J, Hoffstetter I, Reer R, Assheuer J. Age related MRI morphology of the menisci in asymptomatic individuals .Arch Northup Trauma Surg. 115(3-4):199-202, 1996.