Effect of Ethanolic extract green tea (*Camellia sinesis*) on lipid profile, growth performance and some carcass characteristics of local female rabbits

Shaymaa Kadhim Noor Alzamili
Physiology Department, Veterinary Medicine University of AL-Qadisiyah
Shaymaa.ALZamili@qu.edu.iq

Abstract

The present study was carried out on (40) female local rabbits the average weight (2.800± 250gm) the rabbits were divided into two equal groups. The first group was a control group contain 20 rabbits which oral administration with distilled water only for two weeks . The second group treated with Ethanolic extract of green tea contain 20 rabbits with dose 150mg/kgbw for two weeks. The study was aimed to determined the effect of ethanolic extract green tea(*Camellia sinesis*)on some blood parameters level of Total cholesterol, Triglyceride, low density lipoprotein, High Density Lipoprotein, Very low Density Lipoprotein, the oral administration of green tea extract physiological and histological results the levels of total cholesterol and low density lipoprotein recorded a significant decrase ($p \leq 0.05$)when compared with control group. The levels of Triglyceride, High Density Lipoprotein and Very low Density Lipoprotein did not record significant increments in comparison with control group. The results presented that the body weights showed significant decrements ($p<0.05$) when compared with the control group. The weights of livers of treated group enlisted a significant decrement($p< 0.05$) while the weight of kidneys did not record any significant changes as compared with the control group.

The histopathological results showed presence of hepatic architecture which were obvious for hepatic cells around the central vein, dilation of hepatic sinusoids with proliferation of the endothelial cells which lining the sinusoids with vaculation of the hepatic cells and hyperplasia which were simple in the bilary ducts inside the hepatic tissue.The hepatic cells showed in some slides proliferation and had prominent and clear nuclei with cytoplasm and some hepatic cells presented had two nuclei; These changes were clear and positive when compared with the livers of the control group which appeared with normal tissue, whereas the hepatic cells arranged in radiated shape around the central vein.

Keywords: green tea, lipid profile, growth performance, carcass characteristics, rabbits.

تأثير المستخلص الكحولي للشاي الأخضر (*Camellia sinesis*) على الصورة الدهنية والكفاءة الوزنية وبعض معايير الجسم في اناث الارانب المحلية

شيماء كاظم نورالزاملي
فرع الفسلجة والأدوية،كلية الطب البيطري،جامعة القادسية

الخلاصة

اجريت الدراسة على (40) من اناث الارانب المحلية تراوحت معدل أوزانها (2.800± 250)غم وقسمت بالتساوي الى مجموعتين. المجموعة الاولى مجموعة سيطرة ضمت 20 ارنب من الاناث جرعت بالماء المقطر فقط لفترة اسبوعين ، المجموعة الثانية مجموعة المعاملة بالمستخلص الكحولي للشاي الاخضر ضمت 20 ارنب جرعت بجرعة 150 ملغم / كغم من وزن الجسم ولمدة اسبوعين .

اظهرت النتائج بان مستوى الكولستيرول الكلي (TC) و البروتين الدهني الواطئ الكثافة (LDL) قد سجل انخفاضا معنويا ($P\leq0.05$) مقارنة مع مجموعة السيطرة . بينما مستوى الكليسيريدات الثلاثية (TG) والبروتين الدهني العالي الكثافة(HDL) و البروتين الدهني الواطئ الكثافة جداً(VLDL) لم يسجل زيادة معنوية مقارنة مع مجموعة السيطرة .

اما بالنسبة لاوزان الجسم فقد اظهرت النتائج انخفاضا معنويا ($P<0.05$) مقارنة مع مجموعة السيطرة . اوزان الاكباد فقد سجلت انخفاضا معنويا ($P<0.05$) بينما اوزان الكلى لم تسجل تغيرا معنويا مقارنة مع مجموعة السيطرة .

اظهرت النتائج النسيجية وجود شكل هندسي شعاعي واضح للخلايا الكبدية حول الوريد المركزي ، توسع للجيبانيات الكبدية Sinusoids مع تكاثر للخلايا البطانية المسطحة للجيبانيات مع تفج ي للخلايا الكبدية وفرط تنسج بسيط للقنوات الصفراوية داخل النسيج الكبدي .الخلايا الكبدية تظهر في بعض المقاطع متكاثرة وذات انوية واضحة وبارزة وهيولي ح مضي وفي بعض الخلايا الكبدية تظهر حاوية على نواتين نتيجة الانقسام السريع للخلايا. وهذه التغيرات هي تغيرات ايجابية واضحة اذا ما قورنت باكباد حيوانات السيطرة ، التي اظهرت نسيج طبيعي حيث تظهر الخلايا الكبدية مرتبة بشكل شعاعي حول الوريد المركزي .

Introduction

Medical herbal plants play a key role in the health care, about 80% of the world population relies on the use of traditional medicine which is predominantly based on plant material (1) . The herbal compounds have become increasingly popular,because they are regarded harmless. Herbal medicines are complex mixtures of different compounds which usually act as a synergistic effect to give their full beneficial effect(2).Tea, one of the most popular beverages consumed world wide by man, has received a great deal of attention regarding its possible contribution in prevention of many diseases(3) include the prevention of cancer(4) and cardiovascular disease(5).The anti-inflammatory effect(6) anti-arthritis(7)antibacterial effect(8)antiangiogenic effect(9) antioxidation(10) antiviral effect(11) neuroprotection(12).The effects of green tea an health promotion are mainly attributed to its polyphenol content (13).The chemical composition of green tea is complex,there are 15% of 20 % dry weight is protein,including 1% to 4% of dry weight enzymes and amino acids as well as 5% to 7% of dry weight carbohydrates besides that there are lipids such as linoleic and α –linolenic acids,sterols, vitamins (C,E,B),xanthenes as caffeine and theophylline, pigments as chloroplyll and carotenoids, volatile compounds as aldehydes minerals and traceelements(14).

Green tea extracts contain a number of component including Catechins , Saponins and Flavonoids and it has been demonstrated that catchens can reduce cellular oxidation (15)and cholesterol absorption(16), green tea has been reported to reduce body weight,body mass & body fat(17)and serum cholesterol level (18) , in additional , (19) found that green tea consumption reduce the blood

glucose as well as total cholesterol and body fat level. The extracts of green tea are more stable than pure epigallo catechin gallate which considers as one of the major constuents of green tea due to presence of other antioxidant compounds in the extracts(10). Green tea exerts have beneficial effects on body weight and composition , excessive visceral fat is specificicallly associated with metabolic activities , emerging data suggests that regular consumption of green tea may increase energy expenditure & reduce body fatness (20,21). The liver is incharge of maintaining the body metabolism homeostasis(22) and the kidneys are the main part of the excretory system as they regulate homeostasis by excretion of waste products of metabodism (23).The liver weight and lipid contents found by (24)when comparaed between the low fat diet for mice, feeding the high fat diet resulted in significant increase in liver TG content and when tea catechins fed to mice were significantly lower than that in high fat fed mice. Plasma creatinine and levels of blood urea nitrogen were found to be reduced by administration of green tea(25,26) mentioned that diabetic rats drenched with green tea appeared a significant reduction in creatinine level,while the blood urea statistically did not charge, The action of anti-platelet cohesion of catechin enables the kidney malfunctions coming from diabetes to return to normal state,(27).

The present study aimed to determine the effects of green tea ethanolic extract on lipid profile , growth performance and carcass characteristics of local female rabbits .

Material and Method

Green tea leaves were purchased from a local market & stored in dry atmosphere . Green tea Ethanolic extract prepared by 50gm of these leaves for powdering in electrical grinder, then made by method of Harborne (28). The powder of green tea was mixed with 70 % ethanol(1:10 w/v) for one day .suspension were filtered through guze and Whatman filter paper No.1 ,the remainder was extracted again to obtain large amount of active compoundes of these leaves, the final extract was dried in 45 c and stored in 4 C.

40 local female rabbits were treated in accordance to the principles of lab animal care and were conditioned at room temperature at a natural photoperiod for 2 weeks before experiment execution. A commercial balanced diet and tap water adlibitum were provided, The animals were randomly divided into two groups (20 animals in each group)

Group 1 (control group) received distilled water as sole drinking source . Group 2 (treatment group) received ethanolic extract of green tea (GT)(1.5% w/v)of beginning of experiment and lasted two weeks.

Both groups subjected to weighing body weight before and after experiment and evaluate lipid profile include Total Cholesterol (TC) , Triglyceride (TG) , High Density Lipoprotein (HDL), Low Density Lipoprotein (LDL) , and Very Low Lipoprotein (VLDL)as well as weighing kidney and liver after scarification under light anesthesia (diethyl ether) 1 day after the end of the treatment .

The blood samples from each rabbit were collected before and after treatment from the ear vein. Serum was separated by putting the tubes in centrifuge at 3000 rpm for 15 min at 37C, serum samples were stored at 4 C until biochemical tests were performed (29) .

Histopathological examination was carried out according to Drury and Wallington (30). The liver tissues were taken from all rabbit groups after scarification . They collected and fixed in 10 % neutral buffered formalin, dehydrated in ascending grades of ethanol alcohols, cleared in xylol , casted, blocked , cut at 2-5 Mm thickness & stained using the routine pathological technique that used by (31).

Data were expressed as the mean ±SE . the statistical significance was carried out using one – way analysis of variance test statistical soft were pakage (32) A possibility of P value ($p<0.05$) was considered as significant differences between mean.

Results

Administration ethanolic extract of green tea extract to the female rabbits as shown in table 1 significantly decreased (P<0.05) the TC levels in post treated rabbits(P<0.05) with green tea when compared with control group. Treatment with green tea of TG ,HDL and VLDL levels did not recorded significant variance, while the inhibitory effect of green tea extract on LDL was statistically significant decrease(P<0.05). Post administration ethanolic extract of green tea to female rabbits evaluated the affection on weight recorded a significant reduction(P<0.05) in body weight when compared with control group , as well as the liver weight was still significantly lower than the normal one(P<0.05). It was also observed that, post administration ethanolic extract of green tea recorded a non significant reduction in the weight of kidney as compared with non treated group as described in table(2) .

Table 1- Effect of ethanolic extract green tea oral admenstration 150mg/kg B.W on lipid profile (mg/dl) in local female rabbit for two weeks.

Groups	TC	TG	HDL	LDL	VLDL
Control	**67.0 A ±0.955**	**245. 7 A ±2.133**	**20.8 A ±0.67**	**14.5 A ±1.744**	**41.75 A ±0.418**
Treatment	**58.0 B ±0.34**	**259.0 A ±2.42**	**19.02 A ±0.21**	**7.44 B ±0.701**	**38.8 A ±0.253**

Different letters mean significant variances(p≤0.05)

Table 2 – effect of ethanolic extract green tea oral administration 150 mg/kg B.W on body, liver, kidney weights in local female rabbits for 2 weeks.

Groups	Body weight	Liver	Kidney
Control	**170A ±3.53**	**9.258A ±0.408**	**0.427A ±0.017**
Treatment	**127B ±2.56**	**7.425B ±0.238**	**0.401A ±0.004**

Different letters means significant variances(p≤0.05)

Histopathological changes

The liver of local female rabbit which treated with ethanolic extract of green tea showed in(Fig. 1) Presence of normal hepatic architecture with dilation of sinusoids, vacuolated hepatocytes. Also there is mild hyperplasia of bile ducts within the hepatic tissue.

Fig. (2)demonstrated there is radially arrangement of hepatocytes which showed normal hexagonal shaped, Dilation of sinusoids and proliferation of flat endothelial cells which lining these sinusoids of treated group.

Fig.(3) showed there is normal radially arrangement of hepatocytes around normal rounded central veins for treated group.

Fig. (4) clarified there is normal radially arrangement of hepatocytes around the central vein. The hepatocytes showed vacuolated with normal, central, and prominent nuclei and acidophilic cytoplasm. Some hepatocytes showed proliferating and binucleated cells. There is proliferation of flat endothelial cells which lining the central veins and sinusoids for treated group.

There is central vein with few radially arranged cords of hepatocytes. There is dilation of sinusoids, large numbers of hepatocytes showed proliferating, binucleated and small in size (Fig.5). While fig.(6) (the control group) reveal there is normal and small bile ducts which lining with columnar epithelium. Also radially arrangement of hepatic cords around the central veins.

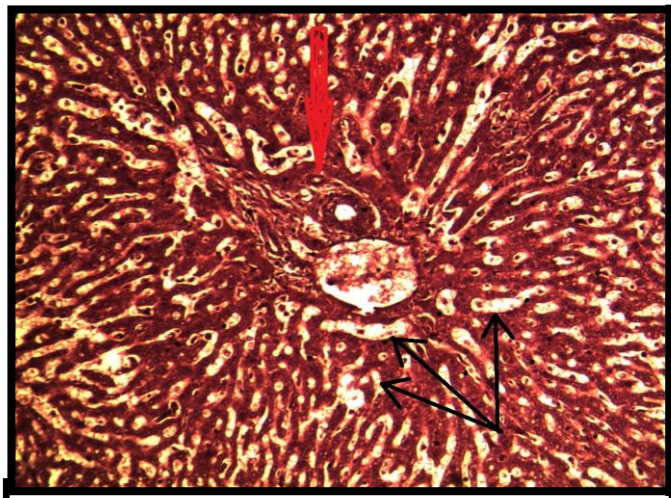

Fig. (1): Presence of normal hepatic architecture,which characterized by radially arrangement of hepatocytes around the central vein. Dilation of sinusoids(thin arraws)and normal, vacuolated hepatocytes. Also there is mild hyperplasia of bile ducts within the hepatic tissue(red arrow). (50X) H&E.

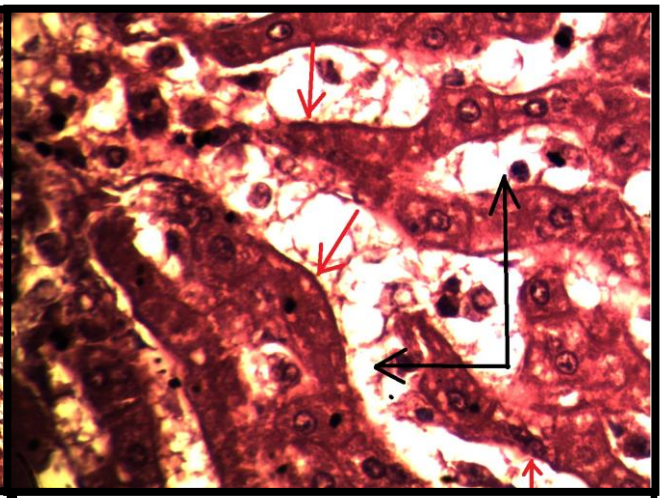

Fig. (2): Higher magnification, there is radially arrangement of hepatocytes which showed normal hexagonal shaped, Dilation of sinusoids(thin arrows) and proliferation of flat endothelial cells which lining these sinusoids(red arrows). (200X) H&E.

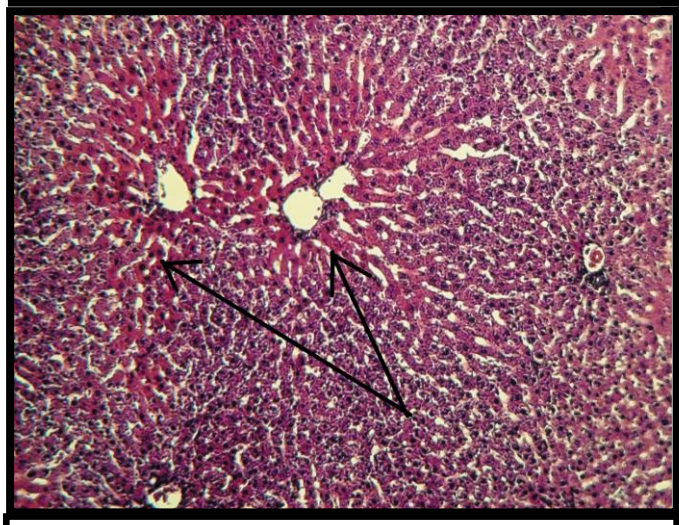

Fig. (3): There is normal radially arrangement of hepatocytes around normal rounded central veins(thin arrows). (50X) H&E.

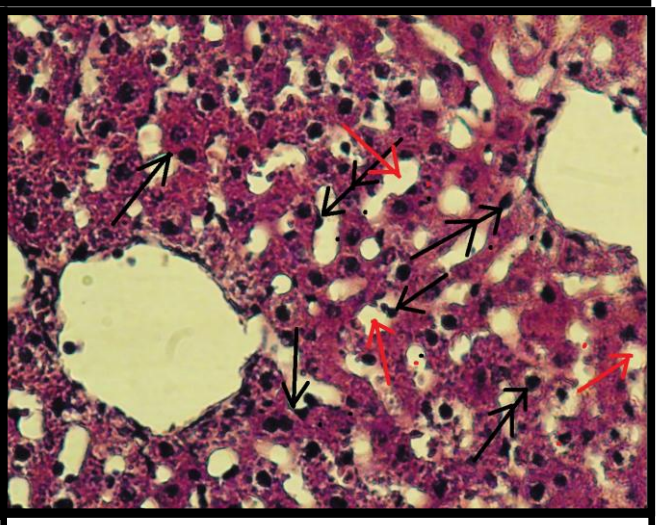

Fig.(4):Higher magnification. There is normal radially arrangement of hepatocytes around the central vein. The hepatocytes showed vacuolated(red arrows)with normal, central, and prominent nuclei and acidophilic cytoplasm. Some hepatocytes showed proliferating and binucleated cells(thin arrows). There is proliferation of flat endothelial cells which lining the central veins and sinusoids(two head arrows).(200X) H&E.

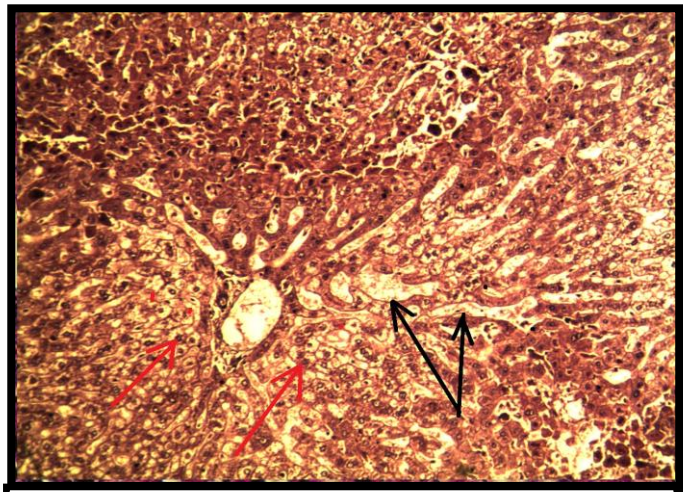

Fig. (5):Control group show there is central vein with few radially arranged cords of hepatocytes(thin arrows). There is dilation of sinusoids, large numbers of hepatocytes showed proliferating, binucleated and small in size(red arrows).(50X) H&E.

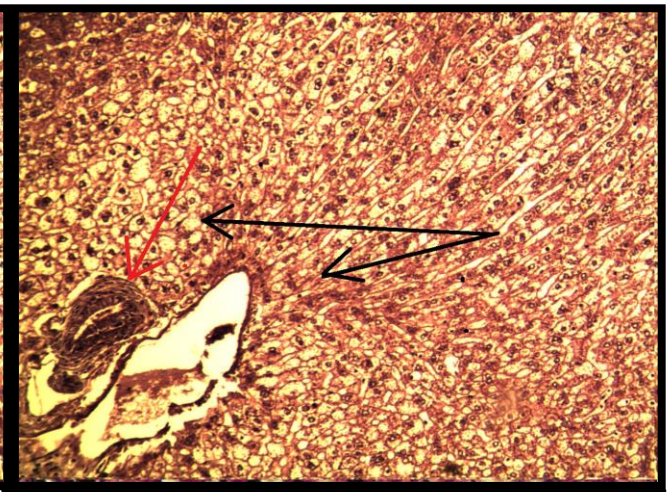

Fig. (6): Control group show there is normal and small bile ducts which lining with columnar epithelium(red arrow). Also radially arrangement of hepatic cords around the central veins(thin arrows).(50X) H&E.

Discussion :-

Laboratory studies show the health effects ethanolic extract of green tea, as the human clinical evidence is still limited, future research needs to define the actual magnitude of health benefits, establishes the safe range of tea consumption associated with these benefits, and elucidates the mechanisms of action.(33). The present results clearly demonstrated that body weight & fat accumulation in rabbit were remarkably reduce by adding ethanolic extract of green tea when compare with control group and this accord with (34 , 35) who suggested an important role for catechins in promoting weight loss, the finding a positive effect ethanolic extract of green tea on weight loss in agreement with results of (20) which show that green tea stimulate 24h energy expenditure and fat oxidation .This effect is attributed to the tea catechins, the latter have been shown to inhibit catchol o-methyl transferase, The enzyme that degrades noradrenaline. Body weight in 150mg/kg BW tea extracts in beverage to rabbit is significantly lowered ($P< 0.05$)this indicating that the antiobesity effect of tea catechins can was attributed solely to the decrease in energy intake, rather, some additional mechanisms leading to energy expenditure may be involved in the anti-obesity effect of tea catechins, these findings suggesting that tea catechins potentially activate B- oxidation of fatty acid in the liver may indicate on underlying mechanism of the beneficial effects of tea catechins (36). Our results revealed that the liver weight was decreased significantly($P< 0.05$) in the treated group when compared with control group, this agreed with (37) who find that green tea decrease liver TC as well as associate with reduction macrophage-mediated oxidation of LDL, reduce uptake of oxidized LDL by macrophages, reduce oxidative state of LDL and reduce LDL aggregation,all of these effects lead to a reduced cellular cholesterol accumulation and foam cell formation (38).

Study showed there is no significant ($P> 0.05$)changes in the weight of kidney before and after treatment and this may be due to the beneficial effect of green tea on renal histochemical parameters and prevent the accumulation of glycogen in the kidney tubules, likewise, the present study agreed with (38**)** who suggested that green tea minimizes the development of glomerular and tubulointerstitial injuries. This study has found that the administration of green tea water infusion as

drinking water to rabbit result in improvement of renal function determined by weighing its weight before & after treatment and this agree with(39)who reports that Flavonoids and catechins have to improve kidney function and these may interprete the results are obtained in this study.

Green tea exerts a variety of beneficial metabolic effects and these lead to decrease levels of TC and LDL and this agreed with(40,41) and this due to reductions in oxidative status and LDL oxidation, and amelioration of lipid metabolism, and the catechin is extracted from green tea decreases the LDL fraction (42). Furthermore, (43,44) suggest that green tea may decrease intestinal absorption of lipids. Where as the TG, HDL and VLDL did not register any significant effect before and after treatment and find that green tea and its extract normalize plasma triglycerides as well as paraoxonase (PON1)is an antioxidant enzyme that protects lipoproteins against oxidative modification, green tea may directly increase serum paraoxonase activity because antioxidant molecules such as flavonoids are shown to preserve paraoxonase activity. (45) emphysize that saponins, flavonoids, phenolic compounds and glycosides have hypolipidaemic and hypocholesterolemic effect, therefore it may be concluded that the hypolipidemic effect is produced by the green tea extract may be due to the presence of flavonoids, saponins and glycosides. The present study showed dilatation of sinusoids and vaculated hepatocytes large numbers of hepatocytes showed proliferation binucleated and small in size and this concomitant with (46) who found that liver treated with green tea extracts showed hepatic necrosis with some areas of relatively preserved hepatic parenchyma demonstrating centrovenular necrosis and bridging necrosis, as well as (47) explained the nuclear degeneration of liver cells treated with green tea extract as a result of inhibition of dihydrofolate reductase enzyme that interferes with the synthesis of DNA.

References

1. Willow J, Liu H(2010).Introduction to Traditional Herbal Medicines and their Study. John Wiley & Sons, Inc., Hoboken, NJ, USA : 1–26.

2. Raederstorff DG, Schlachter MF, Elste V, Weber P(2003). Effect of EGCG on lipid absorption and plasma lipid levels in rats. J Nutr Biochem. 14:326-332.

3. Raymond Cooper, James Morré D and Dorothy Morré M(2005). Medicinal Benefits of Green Tea: Part I.Review of Noncancer Health Benefits. The Journal of Alternative and Complementary Medicine. 11(4): 639-652.

4. Kavanagh KT, Hafer LJ, Kim DW, Mann KK, Sherr DH, Rogers AE,Sonenshein GE(2001). Green tea extracts decrease carcinogen-induced mammary tumor burden in rats and rate of breast cancer cell proliferation in culture. J Cell Biochem. 82:387-398.

5. Sueoka N, Suganuma M, Sueoka E, Okabe S, Matsuyama S, Imai K,Nakachi K, Fujiki H(2001). A new function of green tea: prevention of lifestylerelated diseases. Ann N Y Acad Sci.928:274-280.

6. Dona M, Dell'Aica I, Calabrese F, Benelli R, Morini M, Albini A, Garbisa S(2003).Neutrophil restraint by green tea: inhibition of inflammation, associated angiogenesis, and pulmonary fibrosis. J Immunol 2003, 170:4335-4341.

7. Haqqi TM, Anthony DD, Gupta S, Ahmad N, Lee MS, Kumar GK, Mukhtar H(1999).Prevention of collagen-induced arthritis in mice by a polyphenolic fraction from green tea. Proc Natl Acad Sci USA. 96:4524-4529.

8. Sudano Roccaro A, Blanco AR, Giuliano F, Rusciano D, Enea V(2004).Epigallocatechin-gallate enhances the activity of tetracycline in staphylococci by inhibiting its efflux from bacterial cells. Antimicrob Agents Chemother. 48:1968-1973.

9. Sartippour MR, Shao ZM, Heber D, Beatty P, Zhang L, Liu C, Ellis L, Liu W,Go VL, Brooks MN(2002). Green tea inhibits vascular endothelial growth factor (VEGF) induction in human breast cancer cells. J Nutr .132:2307-2311.

10. Osada K, Takahashi M, Hoshina S, Nakamura M, Nakamura S, Sugano M(2001) Teacatechins inhibit cholesterol oxidation accompanying oxidation of low density lipoprotein in vitro. Comp Biochem Physiol Part C Toxicol Pharmacol.128:153-164.

11. Weber JM, Ruzindana-Umunyana A, Imbeault L, Sircar S(2003). Inhibition of adenovirus infection and adenain by green tea catechins. Antiviral Res.58:167-173.

12. Weinreb O, Mandel S, Amit T, Youdim MBH(2004). Neurological mechanisms of green tea polyphenols in Alzheimer's and Parkinson's diseases. J Nutr Biochem. 15:506-516.

13. Naghma K, Hasan M(2007).Tea polyphenols for health promotion. Life Sciences. 81:519-533.

14. Cabrera C, Artacho R, Gimenez R.(2006). Beneficial effects of green tea – areview. J Am Coll Nutr. 25:79–99.

15. Hara Y, (2001). Antioxidative Action of tea Polyphenols: Green tea. In Hara Y. (ed.): New York, Dekker, 26-40.

16. Kobayashi Y, Suzuki M and Satsu H (2000). Green tea polyphenols inhibit the sodium dependent glucose transporter of intestinal epithelial cells by a competitive mechanism. J agric Food Chem 48: 618-623.

17. Tsuchida T, Itakura H and Nakamura H (2002). Reduction of body fat in humans by long-term ingestion of catechins. Progress Med. 22: 2189-2203.

18. Ahmida M H and Abuzogaya M H(2009). The Effects of Oral Administration of Green Tea and Ginger Extracts on Serum and Hepatic Lipid Content in Rats Fed a Hyperlipidemic Diet. Journal of Applied Sciences Research. 5(10): 1709-1713.

19. Babu P V A, Sabitha K E, Srinivasan P and Shyamaladevi C S (2007). Green tea attenuates diabetes induced Maillard-type fluorescence and collagen cross-linking in the heart of streptozotocin diabetic rats. Pharmacological Research. 55:433-440.

20. Dulloo A G, Duret C, Rohrer D, Girardier L, Mensi N, Fathi M, Chantre P and Vandermander J(1999). Efficacy of a green tea extract rich in catechin polyphenols and caffeine in increasing 24-h energy expenditure and fat oxidation in humans. Am. J. Clin. Nutr. 70: 1040–1045.

21. Westerterp-Plantenga M (2006). Metabolic effects of spices, teas, and caffeine. Physiol. Behav. 89: 85–91.

22. Patra RC, Swarup D, Dwivedi SK(2001). Antioxidant effects of alpha-tocopherol, ascorbic acid and l-methionine on lead induced oxidative stress to the liver, kidney and brain in rats. Toxicology.162:81–8.

23. Perrin NESS, Torbjo¨ rnsdotter TB, Jaremko GA and Berg UB(2006). The course of diabetic glomerulopathy in patients with type I diabetes: A 6-year follow-up with serial biopsies Kidney International.69: 699–705.

24. Murase, A, Nagasawa J, Suzuki T, Hase and Tokimitsu I(2002) “Beneficial effects of tea catechins on diet-induced obesity: stimulation of lipid catabolism in the liver,” International Journal of Obesity. 26, 11: 1459–1464.

25. Sabu MC, Smitha K, and Kuttan R (2002). Anti-diabetic activity of green tea polyphenols and their role in reducing oxidative stress in experimental diabetes. J. Ethnopharmacol. 83: 109-116.

26. Clark TA, Heyliger CE, Edel AL, Goel DP, and Pierce GN(2004). Codelivery of a Tea Extract Prevents Morbidity and Mortality Associated With Oral Vanadate Therapy in Streptozotocin-Induced Diabetic Rats. Metabolism, l 53: (9)1145-1151.

27. Kwag OG, Kim SO, Choi JH, Rhee IK, Choi MS and Rhee SJ (2001). Vitamin E improves microsomal Phospholipase A2 activity and the arachidonic acid cascade in kidney of diabetic rats. J. Nutr. 131: 1297-1301.

28. Harborne J B(1984). Phytochemical Methods: A Guide to Modern Techniques of plant Analysis. Chapman and Hall, London, UK: 1-34.

29. Venkatesan R, Nagarajan P,Rajaretnam R S and Majumdar S S(2006). Hematologic and Serum Biochemical Values in Aged Female Bonnet macaques (*Macaca radiata*) anesthetized with Ketamine Hydrochloride. J. Amer. Assoc. Lab.Anim. Sci., 45 (2): 45 - 48.

30. Drury R A and Wallington E A(1980).Carleton's Histological Techniques,5ed.,In: Oxford University Press, London, New York, Toronto, 241–242.

31. James Anderson (2011).An Introduction to Routine and Special Staining.Leica Biosystems, Wetzlar, Germany .

32. Duncan R C, Knapp R G and Miller M C(1983). "Introdutory Biostatistics of health science". Wileg Medical publication, John Wiley and sons, Lendon, 1161-179.

33. Sabu M Chacko, Priya T Thambi, Ramadasan Kuttan and Ikuo Nishigaki(2010). Beneficial effects of green tea: A literature review.Chinese Medicine, 5:13.

34. Raymond Cooper, James Morré D and Dorothy Morré M(2005). Medicinal Benefits of Green Tea: Part I.Review of Noncancer Health Benefits. The Journal of Alternative and Complementary Medicine. 11(4): 639-652.

35. Waleed M Renno, Suad Abdeen, Mousa Alkhalaf and Sami Asfar(2008).Effect of green tea on kidney tubules of diabetic rats. British Journal of Nutrition. 100: 652–659

36. Murase T, Nagasawa A, Suzuki J, Hase T and Tokimitsu I(2002). Beneficial effects of tea catechins on diet-induced obesity: stimulation of lipid catabolism in the liver. International Journal of Obesity & Related Metabolic Disorders. 26 : 1459–1464

37. Ahmida M H and Abuzogaya M H(2009). The Effects of Oral Administration of Green Tea and Ginger Extracts on Serum and Hepatic Lipid Content in Rats Fed a Hyperlipidemic Diet. Journal of Applied Sciences Research. 5(10): 1709-1713.

38. Sung I K and Sang K N(2007). Green Tea as Inhibitor of the Intestinal Absorption of Lipids: Potential Mechanism for its Lipid-Lowering Effect.J. Nutr. Biochem., 18: 179-183.

39. Renno W M, Abdeen S, Alkhalaf M and Asfar S.(2008).Effect of green tea on kidney tubules of diabetic rats. British Journal of Nutrition,100(03):652-659.

40. Abd-Elraheim A Elshater, Muhammad M A Salman, Mahrous M A Moussa (2008). Effect of green tea consumption on level of glucose, lipid profile and kidney functions in alloxan induced-diabetic rats.Egypt. Acad. J. biolog. Sci., 1(2): 125 - 134 .

41. Alexopoulos N, Vlachopoulos C and Stefanadis C(2010).Role of green tea in reduction of cardiovascular risk factors. Nutrition and Dietary Supplements.2: 85–95.

42. Zdunczyk Z, Frejnagel S, Wroblewska M, Juskiewicz J, Oszmianski J and Estrella I (2002). Biological activity of polyphenol extracts from different plant sources. Food Research International 35: 183-186.

43. Raederstorff DG, Schlachter MF, Elste V and Weber P(2003). Effect of EGCG on lipid absorption and plasma lipid levels in rats. J. Nutr. Biochem. 14: 326-332.

44. Aviram M, Rosenblat M, Gaitini D, Nitecki S, Hoffman A, Dornfeld L and et al.(2004). Pomegranate juice consumption for 3 years by patients with carotid artery stenosis reduces common carotid intima-media thickness, blood pressure and LDL oxidation. Clin. Nutr. 23:423-433.

45. Rupasinghe H P, Jackson C J, Poysa V, DiBerado C, Bewely J D, and Jenkinson J(2003). Soasapogenol A and B distribution in Soybean (Glycine Max L. Merr) in relation to seed physiology, genetic variability and growing location. J. Agric. Food Chem. 51: 5888-5894.

46. Molinari M1, Watt KD, Kruszyna T, Nelson R, Walsh M, Huang WY, Nashan B and Peltekian K. (2006). Acute liver failure induced by green tea extracts: case report and review of the literature. Liver Transpl. Dec;12(12):1892-5.

47. Junqueira LC, Carneiro J and Kelly RO(1995). Basic Histology, Appleton and Lange Medical Publication, San Mateo, California, 8ed.320.