

 <p>ISSN NO. 2320-5407</p>	<p>Journal Homepage: - www.journalijar.com</p> <p>INTERNATIONAL JOURNAL OF ADVANCED RESEARCH (IJAR)</p> <p>Article DOI: 10.21474/IJAR01/1985 DOI URL: http://dx.doi.org/10.21474/IJAR01/1985</p>	 <p>INTERNATIONAL JOURNAL OF ADVANCED RESEARCH (IJAR) ISSN 2320-5407</p> <p>Journal homepage: http://www.journalijar.com Journal DOI: 10.21474/IJAR01</p>
---	---	---

RESEARCH ARTICLE

The study of the Toxic Effects of Ochratoxin A the purified from fungus *Aspergillus niger* in vivo of White rats and Evaluating the Ability of the Bio-lotion Floramil in the Reduction of Its Toxicity.

Nada Ahmed Fairouz¹ and Abdul Ameer Sameer².

1. Dept. of Biology, College of sciences, Al-Qadissiyah University.
2. A research paper Extracted from Master Thesis for the First Researcher.

Manuscript Info

Manuscript History

Received: 15 September 2016
Final Accepted: 24 October 2016
Published: October 2016

Key words:-

Ochratoxin A , *Aspergillus niger*, bio-lotion Floramil.

Abstract

The study has the selection of isolates of *A.niger* fungus and examining their ability to produce the Ochratoxin A and defining the toxic effects on some of the anatomic properties of the males of white rat. Moreover assessing the capability of the bio-lotion Floramil in reducing its toxicity , and when testing the ability of isolates of the fungus that is examined to produce the Ochratoxin A by the use of the technology Thin layer Chromatography (TLC) shows that seven isolates producing this toxin out of 20 isolates and the most productive was the isolate *A.niger*16, also the technology (PCR) that the selected isolates (AN3,An6,An7,AN9,AN10,AN16, AN,19) *A.niger* DNA has contained the gene (PKS).

The results of the histological study for the animal of the white rat that is treated with the Ochratoxin A where the tissue sections that have been taken from the liver shown the existence of pathological effects like a sever congestion in the tissues of the liver and loss of the radiative arrangement of the liver cells and an expansion in the liver pockets and breeding of the kupffer cells , while the kidney has been affected by the Ochratoxin A and the effect is represented in atrophy of the glomeruli and an expansion of the renal tubule twisted with (Degredation) and alienation in the cells of lining the renal tubules twisted , and the intestine emerges in it a damage of the villi with a (Desequamation)with infiltration of inflammatory cells specially (Macrophage),There was an a role for the bio-lotion of the bacteria *Pseudomonas fluorescens* in protecting the organs of the males of the white rat that is treated with OchratoxinA with the bio lotion floramil from the toxic effects of the Ochratoxin A with the existence of slight changes of the tissue in the organs of the rats treated with it.

As for the influence of the bio-lotion in the tissues of the liver , kidney and the intestine, the results of test have shown and the laboratory diagnosis for the tissue sections for the mentioned organs that there is no occurrence of change of pathological tissue in the treatment of the bio-lotion floramil only and it is the symmetry of the tissue sections of the comparison treatment that referred to no pathological changes.

Corresponding Author:- Nada Ahmed Fairouz

Address:- Dept. of Biology, College of sciences, Al-Qadissiyah University.

Introduction:-

The pollution of foods and feedstuff is one of the problems that threatens many of the developing countries that lacks the circumstances of the good food storing and can be considered as a very big source of an anxiety what push these countries to provide a healthy sources of food to achieve their food security(Makun et al.;2010) and these corpses are exposed to the infection with many of the fungus because it contain a high percent of carbohydrates that usually starts in the field and develops during storing what causes its contamination with fungus toxicities which may reach to the man or animal while having these grains in shape of food products or foodstuff and what causes the occurrence of symptoms sometimes acute toxicity that has a quick effects in the biological systems of man and animal, or a chronic toxicity as a result of long run of exposure to the little dosages of those toxicities , that leads to the emergence of many diseases like cancer and Nephro-or hrpato toxicity as well as disencouragement the immunosuppression(Smith et.al.1995;Henry and Cole ,1993).The actual problem is that there are some fungus that causes pathological cases that the fungus was not the reason behind it but the metabolic outputs for that fungus and specially the secondary metabolic outputs that is known as Mycotoxins in the buddy of the human being that is responsible for diseases symptoms that appears on the patient(Gallagher,2003) and these injuries can be the most dangerous than the previous cases where it is hard to find the guaranteed ways to reduce it (Prescott et al.,2001).

The Material and the methods of Work:-

Use in this research the bio-lotion (Floramil) that is basically compound of the bacteria of Pseudomonas fluorescens that is carrying the calcium carbonates , in addition to the fungus A.niger that is isolated from the foodstuff, and the diagnosed basically beside it is being diagnosed by the technology of PCR.

Examining the ability of the isolates of the fungus A.niger on producing Ochratoxin A

Developing the Isolates of the Fungus A.niger.

It has been creating Petri dishes contain the medium (PDA) where isolate the fungus tablets A.niger with an average diameter 5 ml. planted at a rate of three repeaters for each isolate and put these tablets in the petri dishes centers then incubated at a temperature of 30C° for a period of ten days. .

Extracting Ochratoxin A

Extract the Ochratoxin A according to Macdonald and others (1999)

Identifying The Ochratoxin A

The technology of the Thin Layer chromatography (TLC) to detect the fungus isolates A.niger that are able to produce Ochratoxin A(OTA) and according to (Sobolev and Dorner,2002)

Detecting the Gene that is responsible for Producing Ochratoxin A for the fungus A.niger

The PRC has been tested by the use of (A-1360 Ochratoxin PKS gene) to detect about the gene that is responsible for producing Ochratoxin A.

Extracting and Multiplication The DNA

Extract the DNA from the examined fungus by the use of the kit (EZ-10 Spin column fungal Genomic DNA mini-Preps Kit), mixture reaction of PCR has been prepared by the use of (Accupower PCR PreMIX) that is supplied by the Korean company of Bioneer (1.5µL Forward primer and 1.5µL Reverse primer), Then the components of the reaction mixture PCR that was mentioned in the above table in special tubes size 0.2ml after testing the PCR (ACCUpower @PCR Premix) that containing the rest of the components of the reaction PCR, then all tubes has been transferred to the apparatus Vortex centrifuge (Exispin) at the speed 3000 rpm for the period of three minutes then it was put in the apparatus PCR Thermocycler as in the below:

PCR Step	Repeat cycle	Temperature	Time
Initial denaturation	1	95C	5min
Denaturation	30	95C	5sec.
Annealing		58C	30sec
Extension		72C	1 min
Final extension	1	72C	5min
Hold	-	4C	Forever

Table 1:- Represents the beginner that is used in this study with the nucleotide sequence and the output of the test PCR:

Primer	Sequence		Amplicon
Ochratoxin	F	CCCAGTTCGGTTTTGCACTG	307bp
	R	GCCCGTCAGTAACATGGGAA	

Gel electrophoresis:-

Electrophoresis Deportation has been done by the use of Agrose gel by the percent of 1% as well reading the result of reaction PCR product analysis as follow:

1 gm of Agarose has been melted in 100ml of the solution of (TBE buffer) buffer with concentration 1X and the mixture is heated for 5 minutes , the jell was left to chill at the temperature of 50c and after 3µl of Ethidium Bromide and it was mixed well with the gel .The Agarose jell has been poured in the tray frame , after that was left to solidify in the room temperature for the period of 15 minutes and then comb from the gel carefully after that the samples of the output of the test(PCR Product was uploaded and put in gel wholes .And after the completion of the uploading process the Agarose gel was submerged by the use of the solution TBE Buffer by the concentration of 1X and closing up the cover of deportation and after that the apparatus was started by the use of the current 100 volt and Am.80 for an hour and after the deportation process was finished the agarose gel that contained output of the PCR was tested by the use ultra vile light source to identify the output with the measuring unit .After that the product was photographed by the use of a digital camera to observe DNA straps.

The Study of the toxic Effects of the Ochratoxin A invivo of the White rats.

One isolate was selected from the producing isolates of the Ochratoxin A and was developed on PDA environment.

Extracting the Ochratoxin A

After the end of incubation for the plates that were used to grow the fungus A. niger that is of 100 plates .The OchratoxinA was extracted in the same way that was followed in the item of the detecting the Toxin OTA.

Purification and Separating the Ochratoxin A:-

The technology of purifying the Thin Layers Chromatography(TLC) in the process of purifying and separating ochratoxinA in shape of streak on the layers of TLC and on the area of 2cm from the lower edge and after the ending of the deportation of the location of the existence of the toxin on the layers TLC by the use of the clean and sterelized lancet by the help of the ultra violet source , after that the silica that contains the toxin by the use of acute blade and the silica was gathered in clean , sterilized test tubes, after amount of chloroform was added equal to the amount of silica that exist in the sterelized test tubes and the tubes was shaken well and was put in the centrifuge with a speed 6000 rotates per 10 minutes after that the filtrated was taken and the sludge was left and the sample was concentrated under 45C and so on the process was repeated many times where the amount of 140 mg was obtained of the Ochratoxin A,after all these toxins were melted by the (DMSO) .

Preparing the Lab-Animals:-

12 animals were prepared of the white male rat where it was classified into four groups each group includes three rats.

Applying the Treatments:-

Treatments	Descriptions of Treatments
The treatments of the distilled water	Endosage to the animals into the distilled water (1ml.Kg of the body weight of the animal)
Ochratoxin A(OTA)+ the Floramil Bio-Lotion	Endosag to the animal with the Ochratoxin A (2mg/kg of the body weight of the animal) and the bio-lotion floramil 2gm/kg of the body weight.
Ochratoxin A(OTA)	Endosaging the animals with Ochratoxin A(2mg/Kg ofthe body weightof the animal)
The Bio-lotion floramil	Endosaging the animals with the floramil bio-lotion (2gm/kg of the body weight the animal)

And at the end of the period of the dosing period that counts up to three weeks the animals were left for three days after that the animals were drugged by the chloroform and were scarified and then were incised from the abdominal cavity and putting the and the parts of the liver organ and the kidney ,and intestine were eradicated from the rats and was kept with the formalin substance 10% to study the tissue changes in it.

The Results and The Discussion:-

Examining of the ability of the isolates of the fungus *A.niger* on the production of the Ochratoxin A in the way of The Thin Chromatography layers(TLC)

The results of the chemical diagnosis with the technology of Thin Layers Chromatography (TLC) have shown that 7 isolates out of 20 isolates of the Fungus *A.niger*, was isolated from the feedstuff that were producing for the OchratoxinA with a percent of production of 30% Table (1) as the isolates of the fungus varied in its production for the toxin according to the size of the stain and the intensity of the luminescence under the ultraviolet source and the contrast is attributed to the contrast of the isolates in producing the Ochratoxin A to the inherent ability of the isolate.the results of this study has exceeded many of the studies like what Gherbawy et al(2012) and what they refer to that 25% of the *A.niger* fungus isolates that is isolated from the dates is able to produce the ochratoxinA and with what Ali and Alghazali(2014) mentioned that 24% of the *A.niger* that is isolated from the fruits of the apple and the pears were a producing for OchratoxinA and it exceeded also Ali and others(2015) that referred that 20 % of the isolates of the fungus that also isolated from the dates were producing for the toxin (OTA).

Table 1:- *A.niger* Fungus Isolates the productive and the Nonproductive for the OchratoxinA .

The ability to produce Ochratoxin	The Isolate	Number	The ability to produce Ochratoxin	The Isolate	Number
-	AN11	11	-	AN1	1
-	AN12	12	-	AN2	2
-	AN13	13	++	AN3	3
-	AN14	14	-	AN4	4
-	AN15	15	-	AN5	5
+++	AN16	16	++	AN6	6
-	AN17	17	++	AN7	7
-	AN18	18	-	AN8	8
+++	AN19	19	+	AN9	9
-	AN20	20	+	AN10	10

The Detecting of the ability of the fungus *A.niger* isolates and the Gene that is responsible for the production of Ochratoxin A by the use of the technology of PCR.

The results of the technology of PCR showed the existence of PKS gene that is the gene which is responsible for producing the Ochratoxin A in the fungus *A.niger* by rate of 35% out of the whole tested isolates .The results of this study has exceeded what Alrubay(2012) has reached where it found out that (10%) from the *A.niger* fungus isolates was contained the gene PKS that is responsible for the production of Ochratoxin A and in another study Almosawy(2015) that (66,66 %) of the isolates for the mentioned fungus and the one that is isolated from the blood and the urine of the patients of the kidney failure that contained the gene that is responsible for the Ochratoxin A.

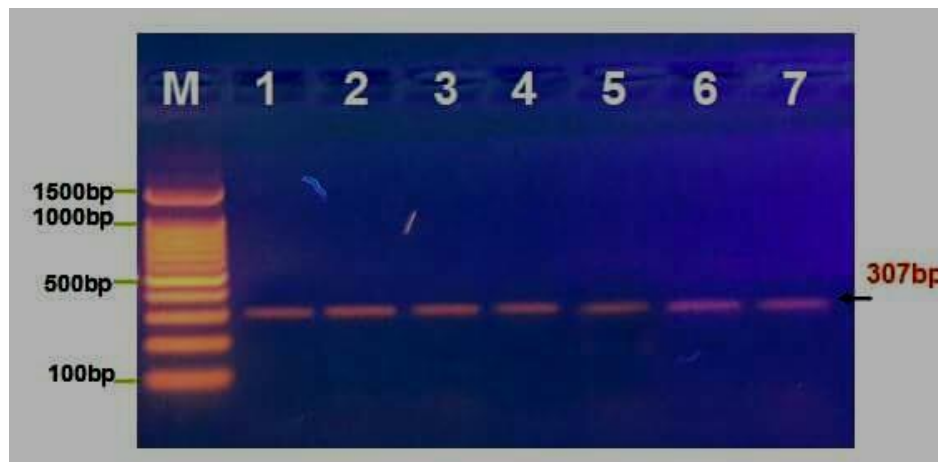


Figure 1:- the Electrophoresis y the use of Agrarose gel that shows the results of the test of the PCR that is concerning the Gene PKS in the isolates of the *A.niger* Fungus where (1500-100bp) M:Marker ,the wholes from 1-7 are the positive isolates for the test with production of 307Bp.

The Histological Study:-

The Toxic Effects for the Ochratoxin in some of the male white Rat

The results of the microscopical test for the tissue sections that was taken from the organs like liver , kidney ,and the intestine for the white male rats that was treated with ochratoxin A with an existence of a severe congestion in the tissues of the liver with loss in the radiation order for the liver cells around the central intravenous the expansion is clear in the hepatic pockets with generation in the kupffer cells .The Bile duct shows hyperplasia with congestion . and the kidney shows a pathological changes in the tissues of the kidney represented the clear atrophy of the renal glomeruli .(Degredation) with alienation clear in the cells lining the renal tubules twisted.An the Intestine shows a damage in the villi with (Desquamation) and generation of the goblet cells can be noted along the villi with infiltration of the inflammatory cells specially (Macrophage).

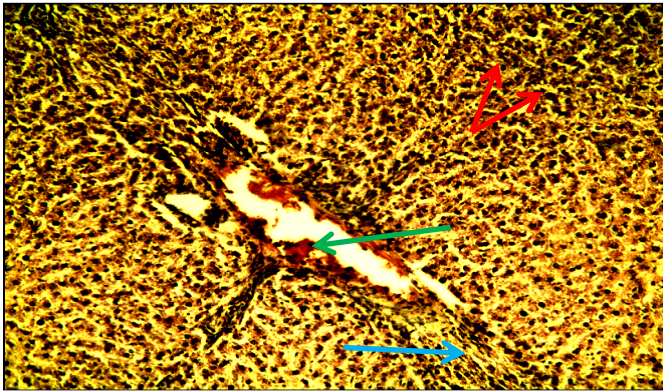


Figure 1:- Section of the liver of the white male rat treated with Ochratoxin A(10XH&R)

- a- Loss of the ranking radiation for the liver with degradation in the hepatic cells (the red)
- b- Severe Congestion can be noted (The Green)
- c- Hyperplasia(the blue) clear in the bile duct.

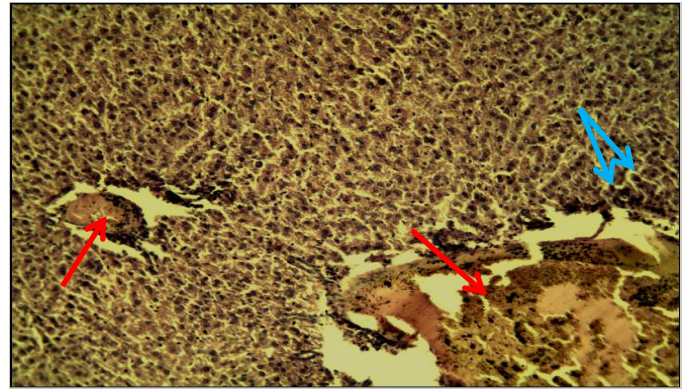


Figure 2:- a Section from the liver of the white male Rat treated with OchratoxinA(10XH&R)

- a-Existence of a severe congestion (The red) in the tissue of the liver with with loss in the radiation order for the liver cells around the central intervenous,
- b-Expantion in the hepatic pockets

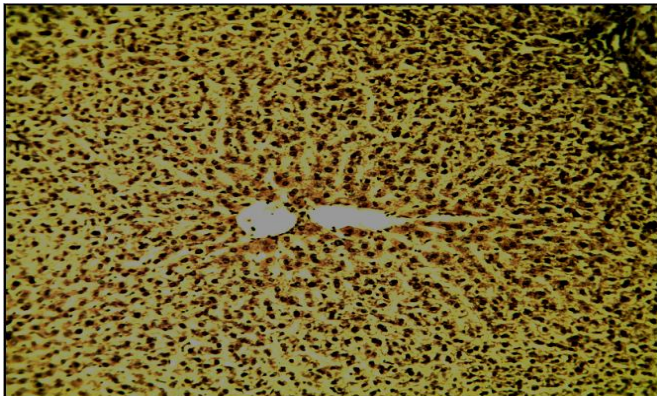


Figure 3:- A section in the white male rat(control),(10X H&E)

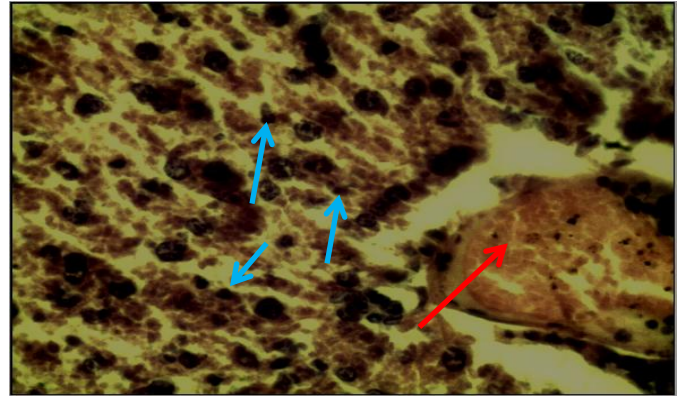


Figure 4:- Section in the liver of the rat that is treated with the ochratoxin A.(40XH&E).

- a-Congestion can be noted clear in the tissue(red)
- b- Generation in the kupffer cells(blue)

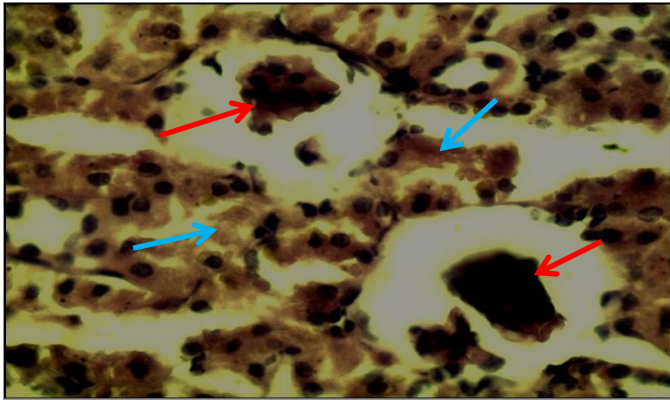


Figure 5:- a section in the kidney of the treated with Ochratoxin A (40X H&E)
a. An existence of atrophy (red) clear in the glomeruli
b. Degradation and alienation clear in the cells that lining the renal tubule twisted (blue)

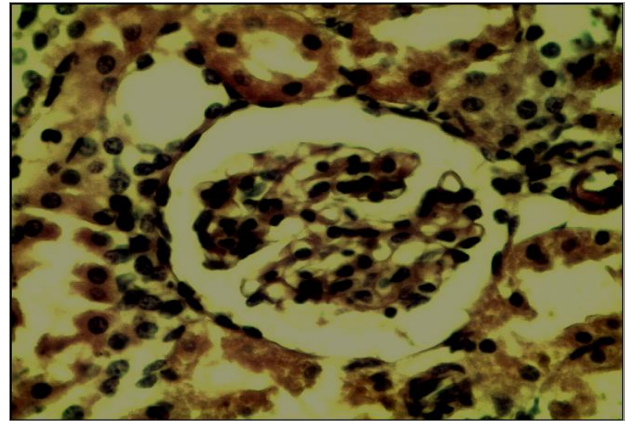


Figure 6:- a section in the kidney of the (control) (40X H&E)

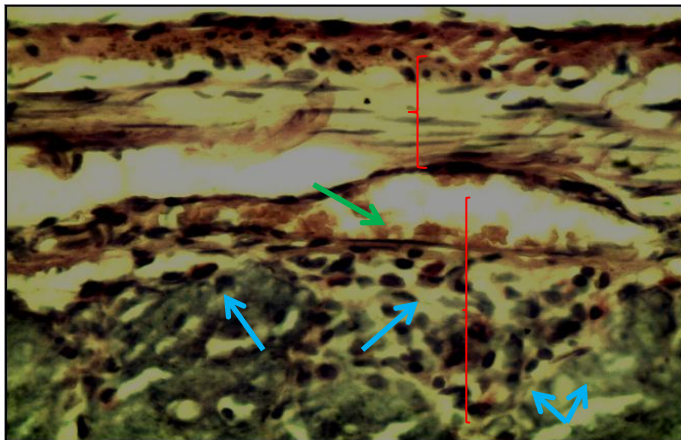


Figure 7:- section from the intestines of the white male rat treated with the ochratoxin A(10XH&E)
a. Existence of clear infiltration of inflammatory cells specially (Macrophage) (The blue)
b. Clear congestion in the sub mucosal layer (the green)

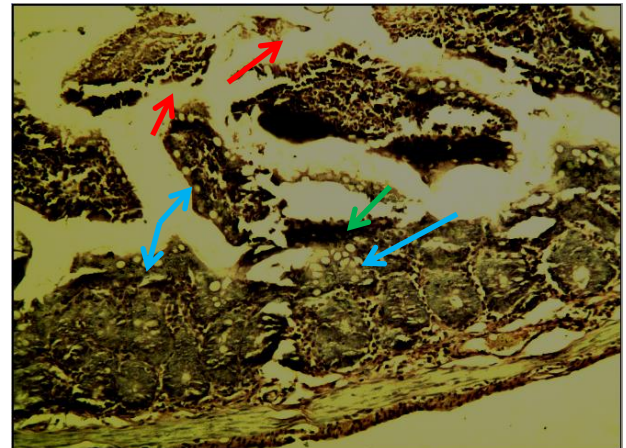


Figure 8:- Section from the intestines of the white rat treated with ochratoxin A (10XH&E)
a. Desquamation (The red)
b. Existence of damage in the villi (the green)
c. Appearance of generation in the goblet cell along the villi (the blue)

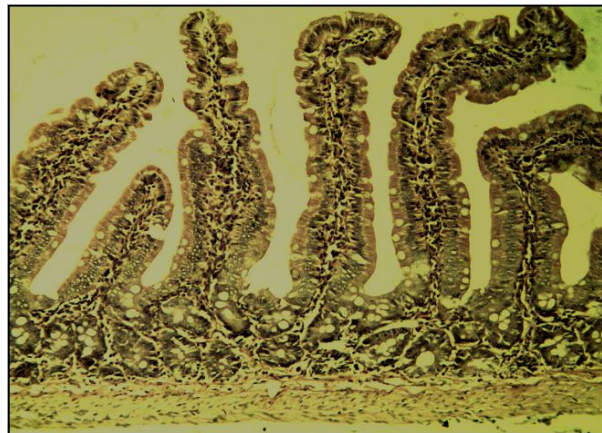

Figure 9:- Cross section of the intestines of the white male rat (control)

The results of this study agree with what Martello (2006) that the toxin of the ochratoxin A causes tissue changes in the liver that leads to cancer .In a local study Alrubay (2007) found out that *Penicillium digitatum* and *penicillium italicum* reason of the vascular congestion in the liver and this can be identified with the result in this study.

On the other hand the WHO(1990) referred the toxin of the ochratoxin A is one of the most important fungal toxins responsible for the chronic nephropathy in the human and animal. and what concerning the effects that happens to human includes damages that reach the liver and kidney and possible leads to cancer of both besides that there is an evidence that it works on destroying the immune system for human.(Martello, 2006) some registered case shown a severe kidney failure after 24 hours as a results of having foods that is polluted with this toxin (Peraica *et al* 1999).

In a study that is conducted by Alghazaly(2014) the ochratoxinA caused a intense influence in the intestines for the white male rats was represented by existence of cytolysis and noted existence for the inflammatory cells in different areas and the same changes happened in the intestines of the animals of the white rats that are treated with ochratoxinA in this study.

In a study that is done by Alrubay(2007) *P. digitatum* and *P. italicum* caused the crash and the necrosis of the villi in some of the areas of the duodenum as well as a congestion in the blood vessels and an existence of inflammatory cells and the sabotagin the mucosa laye.

The Influence of the bio lotion Floramil on the Safety of Some of the Organs of the White Male Rat:-

The results of the Microscopic Diagnosis of the tissue sections that have been taken from the livers of the white rat the existence of natural and central vein with an existence of ranking radiation to the liver cells around it.the liver cells look (Vaculated) with a generation of some of the cells where it is noted the divisive figure in it where some of the liver cells containing the (binucleated hepatocyte) , as for the bile duct look natural and not generated .and for the kidney there is an existence glomeruli that is expanded and rounded and natural .The expansion is simple from the renal tubule twisted with an existence of (Tubular Basophilia) and for the intestine there the villi are natural with tapered endings lining with a vertical cells natural with a generation of the goblecells , and the submucosal layer looks natural with simple atrophy in the muscle layer, serological layer looks weak.

The bio-lotion of the *Pseudomonas fluorescens* played a role in the safety of the organs of the male of the white rats that is treated with the toxin of ochratoxin A with the bio-lotion floramil from the toxic effects of the ochratoxin A with an existence slight tissue changes in the organs of the rats treated with it.

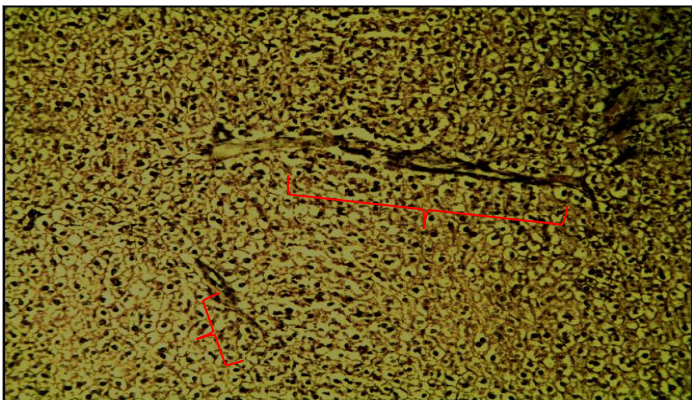


Figure 10:- Section the liver of white rat treated with Ochratoxin A +floramil ,(10XH&E) Ochratoxin A +flora
a. Existence of bile duct and natural in the liver tissue.

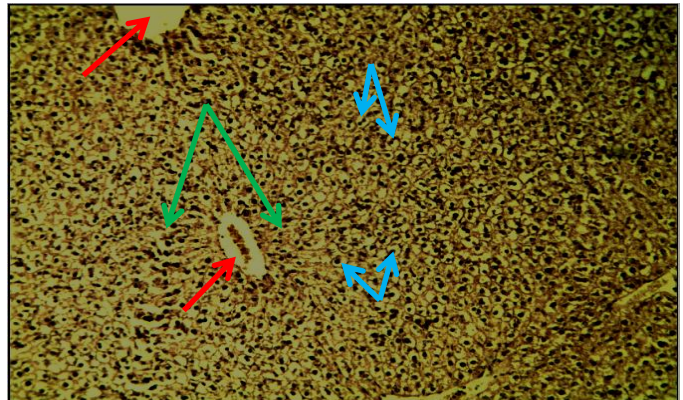


Figure :-11:- section in the liver of the white rat treated with ochratoxin A +Floramil, (H&E10X)
a. Existence of Central and natural vein(The red).
b.Existence of the ranking radiation for the liver cells (the Green)
c. existence of bulgy cells (the blue),(10XH&E)

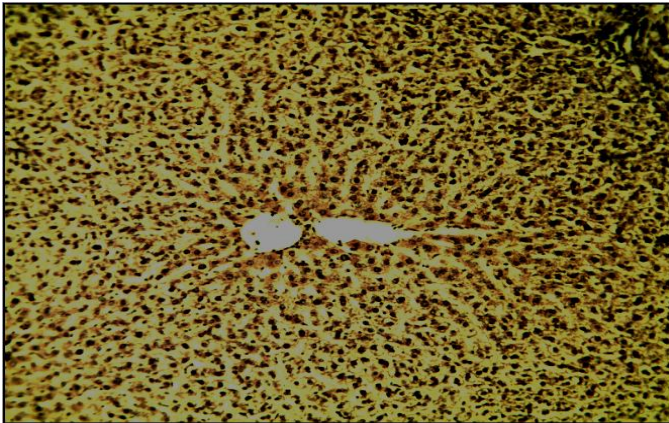


Figure 12:- Section of the liver of the White rat(Control) (10XH&E)

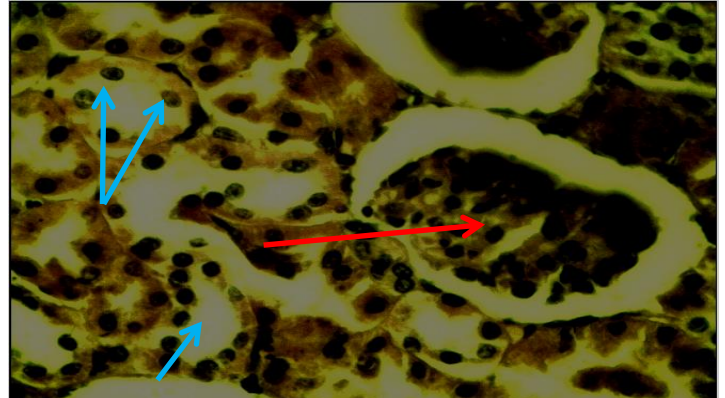


Figure 13:- Cross-Section of the kidney of the white male rat(control) (40X H&E)

- a. The presence of glumeruli expanding natural round(red).
- b. The presence of tubular basophilia(biue) .

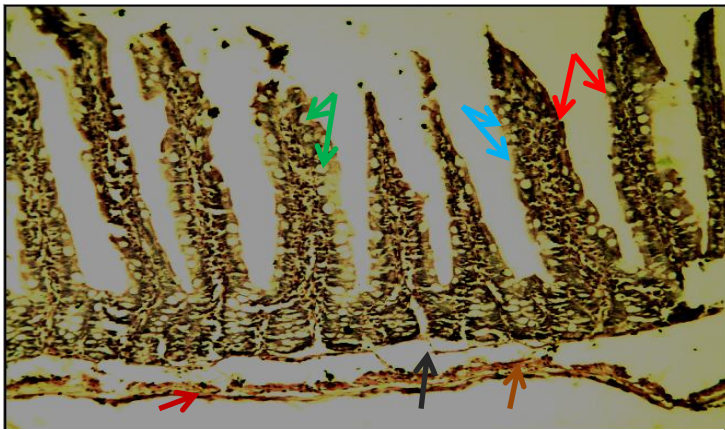


Figure 15:- Section from the intestines of the white rat F+ochratoxinA 10X (H&E)

- a. The villi are normal with tapered endings lined with natural and vertical cells (the red)
- b.Generation in the goblet cells(The blue)
- c.Simple atrophy in the in the muscle layer (the brown)
- d.The sub mucosal layer is natural (the black)

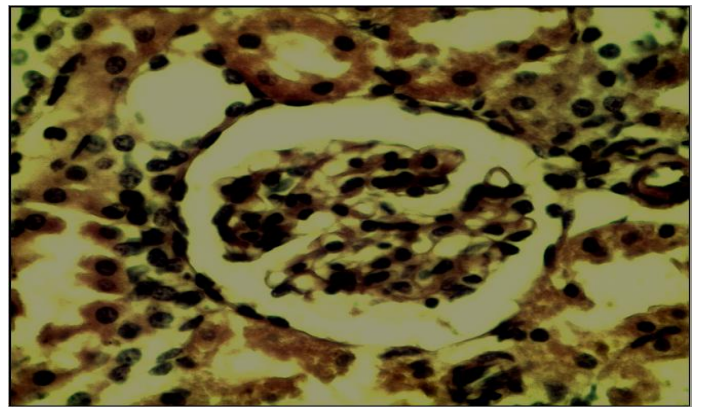


Figure 14:- Cross-Section of the kidney of the white male rat(control) (40X H&E)

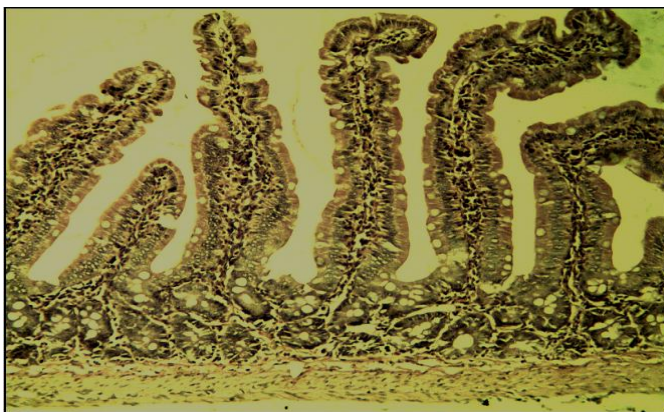


Figure 16:- a section from the intestines of the white rat(control) (10XH&E)

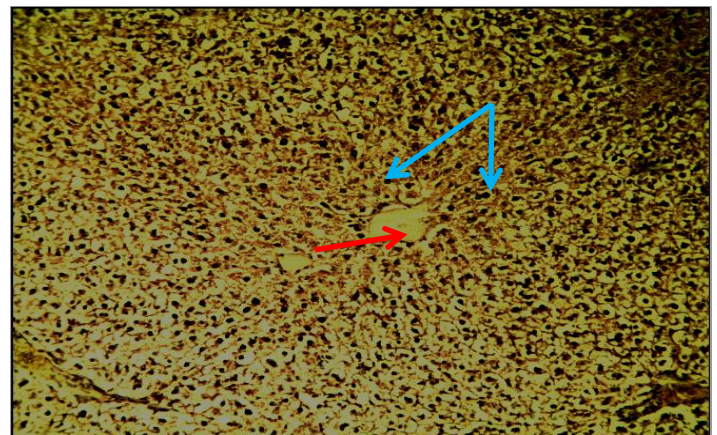


Figure 17:- Section of the white male rat treated with Floraml (10XH&E)

- a .The liver cells are ranked radiationally (the blue)
- b. The existence of the central hepatic vein (the red)

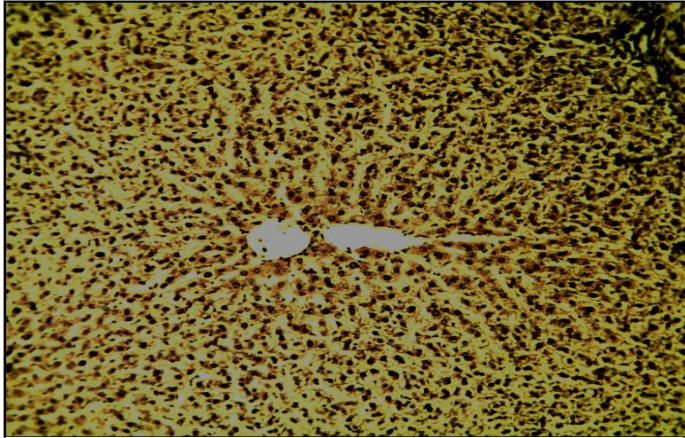


Figure 18:- Section of the white male rat(control) (10XH&E)

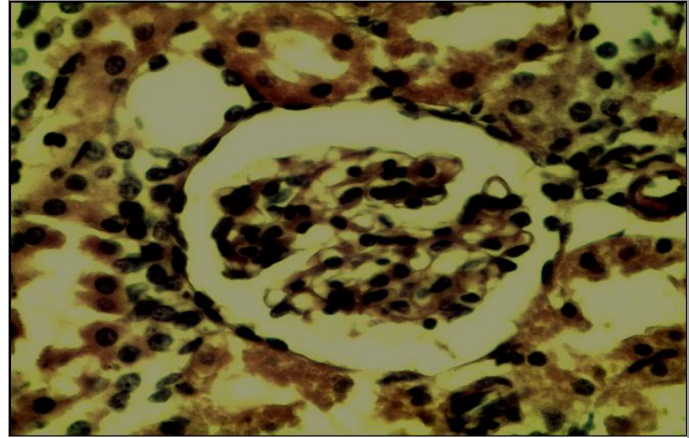


Figure 19:- Cross section of the kidney of the white rat (control) (40X H&E)

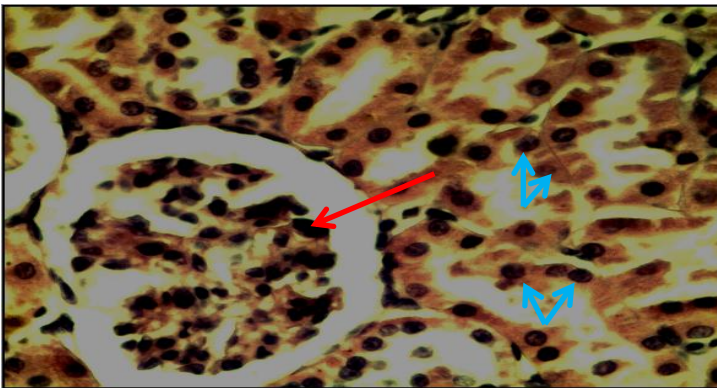


Figure (20) Section of the kidney of the white rat that is treated with floraml(40X H&E)

- a. Natural renal tissue where the glomeruli looks generative and rounded (the red)
- b. The renal tubule twisted look normal and lined with vertical cells that is lowered natural (the blue)

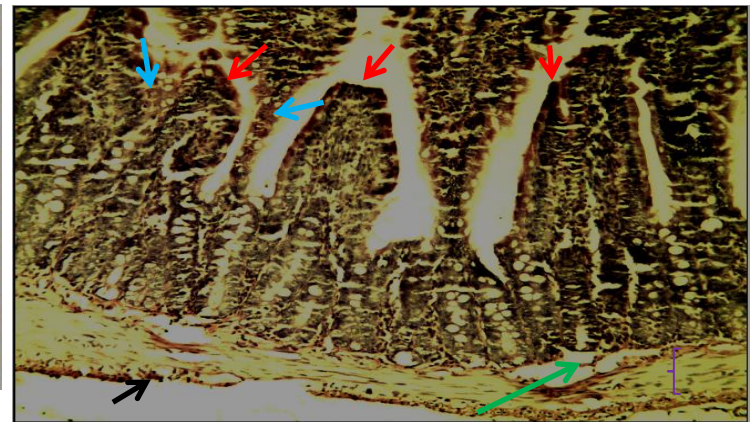


Figure (21) Section of the intenstines of the white rat with floraml (10X H&E)

- a. The existence of the villi elongated and lined with normal and vertical cells (the red)
- b. The existence of the kupffer cells in it (the blue)
- c. The muscle layer sound and generative (the purple)
- e. The serological layer skinny(the black).

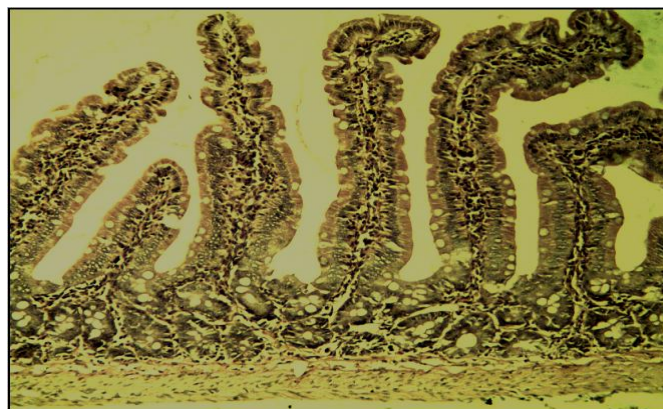

Figure 22:- Cross section of the intestines of the white male rat (control)

The results of this study matches with other studies , whereas the previous studies proved and were conducted on the bio lotions of the bacteria *Bacillus spp* the safety of those bio lotions from the health side where ALashoor(2005) referred in a study that he conducted on the bio lotion *Bacillin* that is manufactured from the vaccine of the Bacteria *B.cereus* tht is loaded on the material of calcium carbonates where this study proved the safety of the bio lotion from the health side through the tissue tests that were conducted on the sections of the liver and spleen for the white rabbits .And in another study that was conducted by Alrubay(2007) the health safety of the bio lotion *Bacitrin AS* that is consisted of the calcium carbonates and the vaccine of the bacteria *B .Circulans* and by giving a dosage for the white male rats from the lotion stuck and after doing the laboratory tests there appear no signs of sickness or dangerousity on the health of the examined animals

Referrences:-

1. **AlGhazaly, Mohammed Talib Badar and Sami Abdulridha Ali.(2014).**The study of the toxic effects of the Ochratoxin A that is Produced from the Isolates of the Fungus *Asperillus niger* the local in some of the chemobiological and histological criteria of the males and femals of the white rat .The Journal of the Kufa University College of Sciences .Approved for publication(4)3 Republic of Iraq.
2. **Alrubay ,Abeer Fawaz Murad.(2012) .**The detecting of the Genes that produce the ochratoxin toxins in the isolates of the fungus *A.niger* and the fungus *A.Flavus*.The journal of The Universitty of Karbala for Pure Sciences-Issue 11, P 35-41.
3. **Almusawy ,Huda Raheem Hashim. (2015).**The study of the relationship of some of the Fungi and their toxins in relation to some of the kidney failure cases that are unknown reasons .PhD Thesis .College of Education The University of Alqadissyah.
4. **Alrubay Abeer Fawaz Murad. (2007).** The toxic effects for the two fungi *Penicillium italicum* and *Penicillium digitatum* in some of the Physiological and the chemobiological and the histological Criteria of the white male white rat and the ability to control both of them in a store.PhD Thesis College of education .Babil University
5. **Alashoor, Ali Jaber Jaim.(2005).** The possibility of producing a bio lotion from the bacteria of *Bacillus Cereus* for the control some of the fungi that causes the Falling of the seedlings.Master Thesis- College of Education- KUfa Universitty.
6. **Bancroft, J. D. and Stevens, A. (1982).** Theory and Practice of Histological technique. Churchill Living stone, New York.pp, 117.
7. **Ghebawy ,A. Y ;H .M . Elhariry and A.S Bahobial.(2012).** Mycobiota And Mycotoxins (Aflatoxins and Ochratoxins) Associated With some Saudi Date Palm Fruits Food Born Pathogens and Disease.9(6): 561-567.
8. **Gallagher, J. C. (2003).** Antifungal pharmmaco therapy for invasive Mould infections .Expopin pharma .cother.4:147.
9. **Hendry, KM.and Cole, EC.(1993).** Areview of mycotoxins in indoor air .Toxicology and Enviromental health .38(2):183-198.
10. **Mac Donald , S . Wilson ,p .; Barnes , K . ; Damant.;Massey ,R .;Mortby ,E .;Shepherd, M.(1999).** Ochratoxin A in dried fruit : method Development and Survey . Food .addit .cntam .16:253.
11. **Makun, H . A.,S. T.Anjorin ,B. Moronfoye ,F.O. Adejo, O .A. Afolabil G.Fagbayibo, B .O .Balogun and A .A. Surajudeen .(2010).** Fungal and Aflatoxin contamination of some human food commodities in Nigeria . African Journal of Food Science ,4 :127 -135.
12. **Martello, N.(2006).** Mycotoxins list (Articals). Biological decontaminat Resource center .United States.pp, 12-45.
13. **Smith , JE ; Solomons ,G .; Lewis , G . and Anderson , JC.(1995).** Natural Toxins . Bio Sci. Biotechnol . 3 (4): 187- 192.
14. **Sobolev , V ,S . and Dorner , J.W.(2002).** Cleanup procedure for Determination of aflatoxin in major agriculture Commodities by liquid Chromatography . j. of Associated of Official Analytical Chemist International .85 : 642-45.
15. **Peterson, D. S.; Hasan, D. E. and Tessier, C. H. (2001).** Aflatoxins in Food. An. Food Contami. 14:23-34.
16. **Perica, M.; Radic, B.; Lucie, A. and Pavlovic, M.(1999).** Toxic effect of mycotoxins in human .Bulletin of The World Health Organization.
17. **WHO, World Health Organization. (1990).** Food Additives Series.