

## Flank analgesia using lumbosacral epidural injection of tramadol alone or tramadol xylazine combination in goats

Q. T. Ali and Th. A. Abid

College of Veterinary Medicine/ University of Al-Qadisiya

### Abstract

The present study aimed to evaluate the effect of the lumbosacral epidural injection of Tramadol alone, or Tramadol and Xylazine combination to induce flank analgesia in male local breed goats. Ten male local breed goats (weighing  $31 \pm 0.47$  kg) were divided randomly into two equal groups. Group 1 (G1) giving tramadol alone (4 mg/kg.), group 2 (G2) giving of Tramadol and Xylazine mixture (Tramadol 4 mg/kg and Xylazine 0.05 mg/kg. B.W.), by lumbosacral epidural technique. (The volume of drugs was completed to 10 ml by adding normal saline). Animals were positioned in dorsal recumbency for two minutes after injection of drugs. Time and degree of analgesia were recorded in the high flank, low flank, and inguinal region, hind limbs, fore limbs, tail and ear. The respiratory rate, heart rate, rectal temperature and ruminal movement before giving the drugs and at each ten minutes after administration of drug till the end of analgesia were also calculated. The lumbosacral epidural injection gave a deep analgesia of high flank region in G1 and G2 for the periods of 110 and 310 minutes respectively, also the analgesia was deep in the low flank in G1 and G2 for the periods 100 and 280 minutes respectively. The inguinal region showed a deep analgesia in G1 and G2 for the periods of 30 and 260 minutes respectively. As well as the hind limbs revealed deep analgesia in G1 and G2 for the periods 20 and 230 minutes respectively, while the forelimbs didn't show any signs of analgesia in G1 whereas the analgesia was deep in G2 for the period of 50 minutes. Deep analgesia of tail was gained in G2 only extending to 180 minutes, while there was no analgesia of tail in G1. No analgesia of ear in G1 while there was deep analgesia in G2 extended for 60 minutes. The heart rate and respiratory rate revealed a significant decrease in G2 compared with G1 which showed a slightly decrease. The rectal temperature decreased in G2 when compared with G1, and the ruminal movement didn't record any changes in both groups of study.

تسكين الخاصرة بالترامادول لوحده أو بخليط من الترامادول والزيبلازين باستخدام الحقن فوق



الجافي القطني العجزي في المعز

قيس ترف علي وثاير عنوان عبد

كلية الطب البيطري/ جامعة القادسية


الخلاصة

استهدفت الدراسة الحالية بيان تأثير الحقن فوق الجافي القطني العجزي بدواء الترامادول 4 ملغم/كغم لوحده، وخليط من الترامادول 4 ملغم/كغم مع الزيبلازين 0.05 ملغم/كغم سوية (على أن تكمل حجم الخلطات الدوائية بالمحلول الملحي الفسلجي إلى 10 مل)، لأحداث التسكين في منطقة الخاصرة في ذكور المعز المحلية. استخدمت في هذه التجربة عشرة من المعز المحلي الذكور وبمعدل وزن  $31 \pm 0.47$  كغم، قسمت المعز إلى مجموعتين متساويتين: المجموعة الأولى G1 مجموعة الترامادول والمجموعة الثانية مجموعة خليط الترامادول والزيبلازين G2. بعد حقن كل مجموعة من الحيوانات بالعقارات المذكورة في منطقة فوق الجافي القطني العجزي. وضع الحيوان على ظهره لمدة دقيقتين بعد حقن العقار. تم تسجيل مدة ودرجة التسكين في أعلى الخاصرة، وفي أسفل الخاصرة،

وفي المنطقة الأربية، والأطراف الخلفية، والأطراف الأمامية، والذيل، والأذن. وتم حساب معدل التنفس، ومعدل ضربات القلب، ودرجة حرارة المستقيم، وحركة الكرش للفترات قبل إعطاء العقار وبعد إعطائه في كل عشرة دقائق لحين انتهاء فترة التسكين. أعطى الحقن فوق الجافي الخلفي للمنطقة القطنية العجزية تسكين عميق لمنطقة أعلى الخصرة للمجموعتين G1 و G2 وللفترات 110 و 310 دقيقة. وكذلك كان التسكين عميقاً في منطقة أسفل الخصرة للمجموعتين G1 و G2 للفترات 100 و 280 دقيقة. في المنطقة الأربية كان التسكين عميقاً في المجاميع G1 و G2 وللفترات 30 و 260 دقيقة. أما في الأطراف الخلفية فكان التسكين عميقاً أيضاً في المجاميع G1 و G2 للفترات 20 و 230 دقيقة. بينما لم تتأثر الأطراف الأمامية بالتسكين في المجموعة G1 بينما كان في المجموعة G2 عميقاً وللفترة 50 دقيقة. تم الحصول على تسكين عميق في المجموعة G2 ممتداً إلى الفترة 180 دقيقة ولم يحدث التسكين في الذيل. لم يحصل التسكين في منطقة الأذن في المجموعة G1 بينما كان التسكين ممتداً في G2 وللفترة 60 دقيقة. حصل انخفاض معنوي في معدل ضربات القلب ومعدل التنفس في المجموعة G2 مقارنة بالمجموعة G1 التي حصل بها انخفاض بسيط، كذلك حصل انخفاض بسيط في درجة حرارة الجسم في المجموعة G2 مقارنة مع المجموعة G1 وأما بالنسبة لحركة الكرش في كلا مجموعتي الدراسة فلم يحصل أي تغيير.

### Introduction

Ruminants are generally not considered good subjects for general anesthesia mainly because of the hazards of regurgitation and inhalation of ruminal contents or saliva into the lungs if the air way is left unprotected. Thus regional anesthesia produced by perineural or epidural injections of anesthetic agents is most frequently employed in these species (1, 2). Surgical procedures in ruminants are usually performed under local or regional anesthesia. Lumbosacral epidural anesthesia is the most common epidural technique used in sheep, goats and, calves, for all procedures caudal to umbilicus (3). Epidural administration of local anesthetics is commonly used for intraoperative anesthesia and postoperative treatment of pain. Tramadol has been used for postoperative analgesia following orthopedic surgery and major gynecologic surgeries in addition to nonsurgical conditions in humans (4). Epidural use of tramadol, has been reported in the horse for evaluation of the analgesic effects of epidural administration (5). It is widely used alone or in combination with other drugs during anesthesia or post operating as analgesic in human and animals to treat acute and severe pain. In human beings, there are many studies on the use of Tramadol to relieve pain postoperatively (6). It is used mainly for relieving of chronic pain, furthermore it seen has local anesthetic effect like lidocaine if giving locally (7). The tramadol produced a longer duration of analgesia than lidocaine alone and lidocaine tramadol combination, and the complete analgesia began more delayed in the tramadol treatment than lidocaine tramadol and lidocaine alone in lambs (8). Xylazine is one of the drugs that are used as a sedative in veterinary practice, it appears to exhibit direct local anesthesia sensory and motor nerve blocking action in addition to its spinal cord alpha2-adrenoceptor-mediated analgesic effects (3). The alpha2-agonists can be absorbed from the epidural space and also it have systemic effects (sedation and cardiopulmonary depression), that are most obvious in the ruminants because of their higher sensitivity to this group of drugs (9). Xylazine has been used alone and/or in combination with adrenalin or with fentanyl to produce epidural block with resultant analgesia of flank region in goats after giving the drugs by sacrococcygeal or lumbosacral epidurals injection (10). Using of tramadol epidurally alone or in combination with xylazine by lumbo-sacral epidural injection in goats is seen scarce in literature for that the study aimed to investigation and comparison of using lumbosacral epidural injection of tramadol alone or in combination with xylazine in produce analgesia of flank region and to study the effect of these drugs



on the vital signs like respiratory rate, heart rate, body temperature, and rumen movement.

### Materials and Methods

The study was conducted on ten healthy adult local breed male goats weighing ( $31 \pm 0.47$  Kg) accommodated in a similar environmental condition. Animals were randomly assigned into two equal groups, and each animal was utilized once only. A triangular area on the back of animal land marking by an transverse imaginary line connecting between the cranial borders of the ilium crosses between the spinous processes of the last two lumber vertebrae cranially, and laterocaudally two oblique imaginary lines passing on the caudal borders of the ilium directing towards the midline and the sacrum, was prepared for aseptic surgery (1). After calculating the dose, the drugs were mixing and diluting with normal saline up to 10 ml volume and administered by lumbosacral epidural injection using spinal needle through the intervertebral lumbosacral space in the depression between the last lumber and first sacral vertebra while the animal in standing position (11). The animal was putting on dorsal recumbency for two minutes immediately after giving the injection to facilitate the distribution of the drugs into the dorsal part of the epidural space, then returning the animal to the standing position. Group 1 (G1) giving 4 mg/kg B.W. of tramadol (T) alone. Group 2 (G2) giving a mixture of tramadol (T) 4 mg/kg B.W. and xylazine (X) 0.05 mg /kg B.W. For each animal, the onset and Presence, duration and degree of analgesia of high flank, low flank, inguinal, hind limbs, fore limbs, tail and ear analgesia were recorded. The respiratory rate (RR), heart rate (HR), rectal temperature (RT), rumen movement (per 5 minutes), and the analgesia were taken before drug administration (time 0) and considered as a control reading for the sequential reading in same animal, then each 10 minutes till the end of flank analgesia. The degree of analgesia were detected by using pinprick and where graded to, no analgesia = 0, mild analgesia = 1, moderate analgesia = 2 and deep analgesia = 3 (12, 13, and 14). Duration of analgesia was the time from the onset of analgesia (when the animal doesn't response to the skin pinprick) to the time when the animal regains sensation. The data obtained were statistically analyzed using ANOVA test to find the significancy at the level of  $p < 0.05$ , between the times before and after drug administration and between the groups (15).

### Results

The degree of high flank analgesia gains a significant deep analgesia at 10 min. after injection of drugs in both groups. In G1, the deep analgesia was extended up to 120 min. time of reading, where it reduced slowly and absent in 180 min. In G2, a significant deep analgesia were extend to 320 min. time of reading, after that reduced slowly to moderate and mild, and ended at 360 min. time of reading. The duration of deep high flank analgesia was taking 110 and 310 min. in G1 and G2 respectively (Fig. 1). The degree of low flank analgesia resembled that of the high flank analgesia, where it becomes significant deep analgesia at 10 min. in all groups. In G1, the deep analgesia in low flank extended to 110 min., after that reduced slowly and disappear at 160 min. In G2 the significant deep analgesia extends between 10-290 min., where it reduced slowly and disappeared at 330 min. time of reading. The duration of deep low flank analgesia was 100 and 280 min. in G1 and G2 respectively (Fig. 2). The degree of inguinal analgesia was gained at 10 min. in G2 while in G1 it was delayed and only become deep analgesia at 30 min. and extends up to 60 min. only, where it reduced slowly and disappeared at 100-130 min. In G2, the deep analgesia started at 10 min. and extends to 270 min., after this time become moderate in 300 min., mild in 310 min. and absent in 320 min. The duration of deep inguinal analgesia was 30 and 260 min. in G1,

and G2 respectively (Fig. 3). The starting of deep hind limb analgesia resembled that of the inguinal analgesia in both groups. In G1 the deep analgesia was extended between 30-50 min. then gradually reduced and ended at 130 min. In G2 a significant deep analgesia started from 10 min. and extends to 240 min., after this time reduced gradually to moderate and mild and ended at 310 min. The duration of deep hind limb analgesia was 20 and 230 min. in G1 and G2 respectively (Fig. 4). In G1 the degree of fore limb analgesia was mild at 10 min. developed to moderate at 20 min. then reduced to mild analgesia at 30 min. and disappear at 40 min. In G2 the deep analgesia was gained between 10-60 min., then reduced gradually till disappeared at 150 min. The duration of deep forelimb analgesia was 50 min. in G2, and not reaches to deep analgesia in G1 (Fig. 5). In G1, the degree of tail analgesia was mild at 10 min. developed to moderate in 20 min. then reduced to mild in 30 min. and disappear at 40 min. In G2 the deep tail analgesia was gained between 10-190 min., then moderate at 200 min., mild at 230-270 min., and scarce at 290 min. The duration of tail analgesia was 180 min. in G2, and no deep analgesia of tail in G1 (Fig. 6). The degree of ear analgesia in G1 was mild analgesia at 10 min. developed to moderate at 20 min. then reduced to mild analgesia in 30 min. and absent at 40 min. In G2 deep ear analgesia was gained between 10-70 min. Then reduced gradually till disappear at 170 min. The duration of ear analgesia was 60 min. in G2, and no deep analgesia of ear in G1 (Fig. 7). The RR in G1 decreased slowly, and reached the least decrease between 120 to 140 min. then raised slowly but not reached to the normal till the end of the experiment. In G2, the RR started to decrease slowly at 10 min. and reached the significant least rate between 120-270 min. ranging between  $(23.8 \pm 1.35)$  to  $(25.2 \pm 0.8)$  breath/min. then increased gradually toward the normal, till the end of the experiment (Fig. 8). The HR in G1 decreased slowly with an irregularity at the first 5 min., where it extended to the least reading at 70 min.  $(84.4 \pm 1.46)$  beats/ min.), then increased gradually to reached the normal range at the end of the experiment. In G2 the HR decreased gradually at the 10 and 15 min., and reached the least reading at 160 min.  $(79 \pm 1)$  beats/ min.) and 200 min.  $(79.4 \pm 0.6)$  beats/min.), after that gradually increased to reached the normal range at the end of experiment (Fig. 9). The rectal temperature decreased in G2 more than G1 (Fig. 10). The rumen movement was normal and not recorded any changes in both groups. There where an adverse effects were seen on animals in G2, like profuse sedation and ataxia extended from 10-60 min., accompanied with frequent urination and excessive salivation.

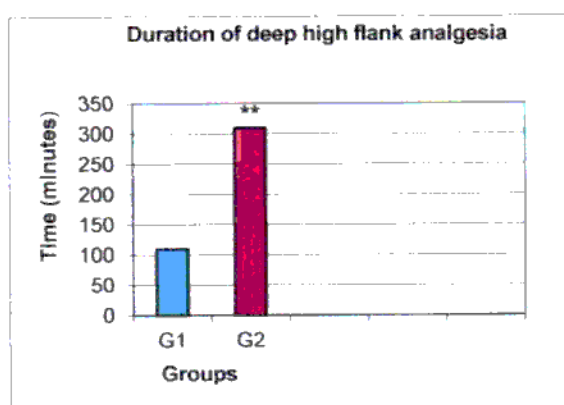


Fig. (1) Duration of deep high flank analgesia in goats after lumbosacral epidural injection with tramadol alone or tramadol xylazine mixture, G1(T) and G2 (TX). See the long deep significant analgesia which extended to  $310 \pm 3.53$  min. in G2 (TX). \*\* denote to significant differences  $p < 0.05$ .

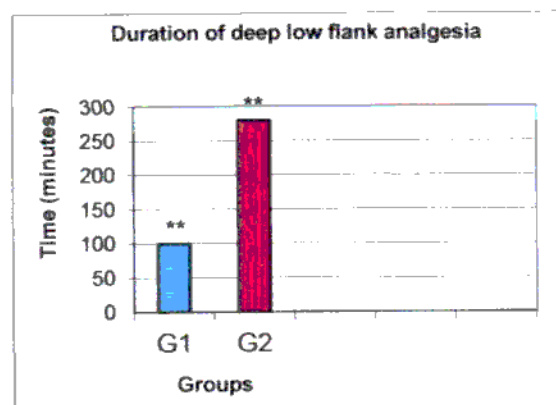



Fig. (2) Duration of deep low flank analgesia in goats after lumbosacral epidural injection with, G1 Tramadol, G2 (Tramadol + Xylazine). See the long deep significant analgesia extended  $(280 \pm 1.77)$  min.) in G2 (TX). \*\* denote to significant differences  $p < 0.05$ .



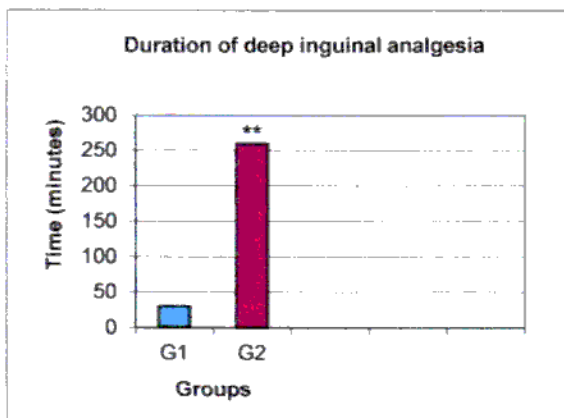


Fig. (3) Duration of deep inguinal analgesia in goats after lumbo- sacral epidural injection with, G1 (Tramadol), G2 (Tramadol + Xylazine). See the long deep significant analgesia extended to 260±5.7 min. in G2 (TX). \*\* denote to significant differences  $p \leq 0.05$ .

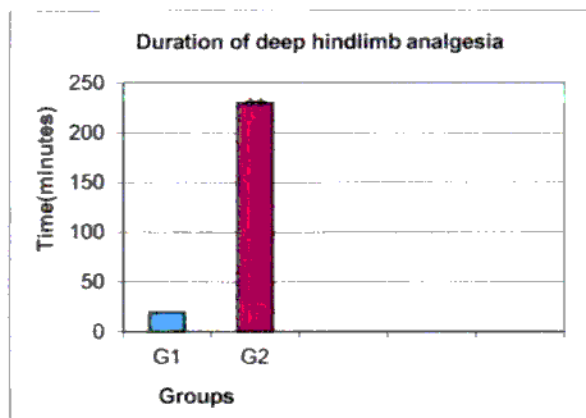


Fig. (4) Duration of hindlimb analgesia in goats after lumbo-sacral epidural injection with, G1 (Tramadol), G2 (Tramadol and Xylazine). See the long deep significant analgesia extended to 230±7.07 in G2 (TX) compare with G1 (T). \*\* denote to significant differences  $p \leq 0.05$ .

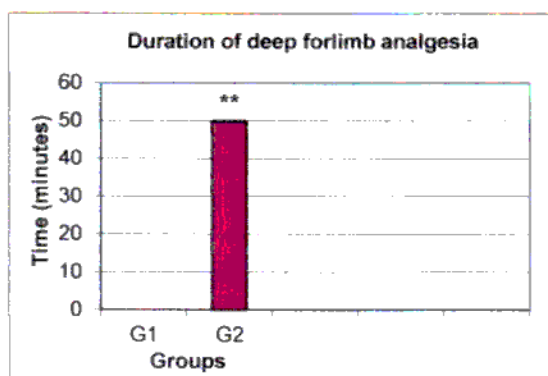


Fig. (5) Duration of deep forlimb analgesia in goats after lumbo- sacral epidural injection with, G1 (Tramadol), G2 (Tramadol + Xylazine). See the long deep analgesia 50±3.53 min. in G2(TX). \*\* denote to significant differences  $p \leq 0.05$ .

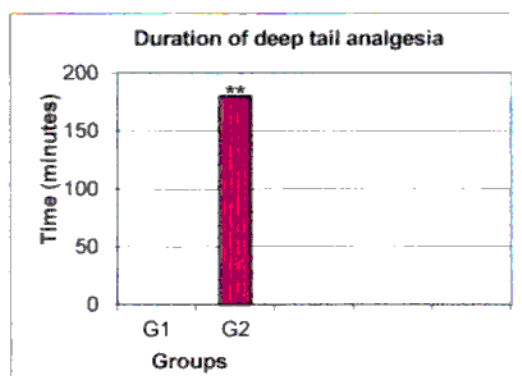


Fig. (6) Duration of deep tail analgesia in goats after lumbosacral epidural injection with, G1 (Tramadol), G2 (Tramadol+Xylazine). See the long deep analgesia 180±3.53 min. in G2 (TX), compare with no analgesia in G1(T). \*\*denote to significant differences  $p \leq 0.05$ .

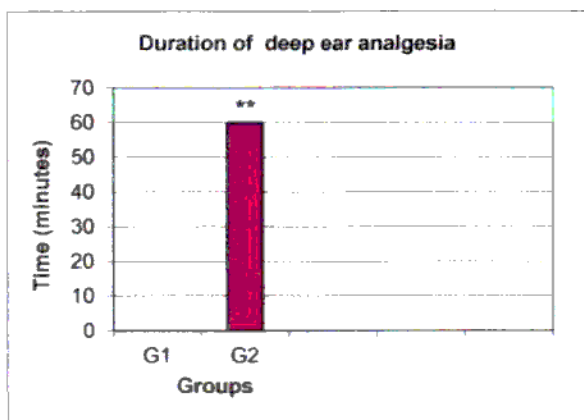


Fig. (7) Duration of deep ear analgesia in goats after lumbosacral epidural injection with, G1 (Tramadol), G2 (Tramadol+Xylazine). See the long significant deep ear analgesia 60±1.61 min. in G2 (TX), compare with no ear analgesia in G1(T). \*\* denote to significant differences  $p \leq 0.05$ .



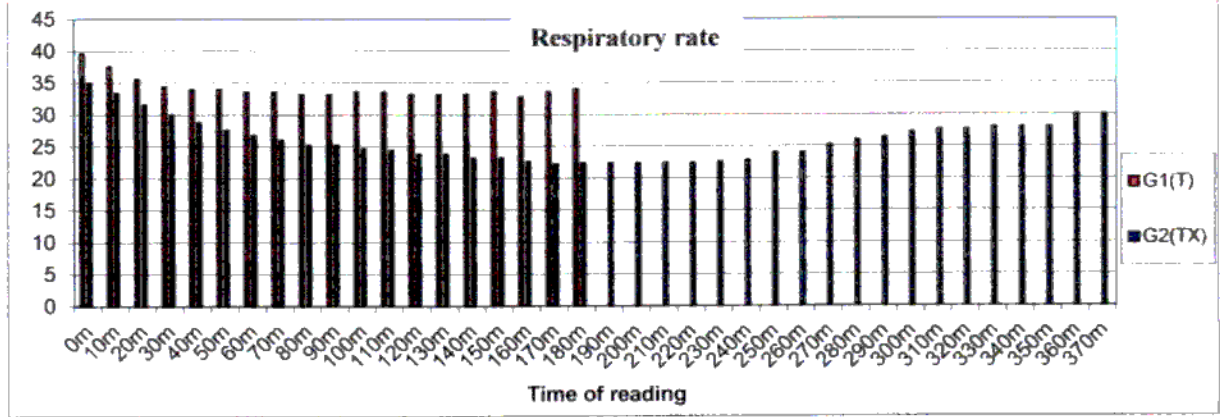


Fig. (8) The respiratory rate in goats after lumbosacral epidural injection with, G1 (Tramadol), and G2 (Tramadol+Xylazine). See the significant depression of respiration in G2 (TX). Data of respiration in G1 was ended where the analgesia was ended at 180 min.

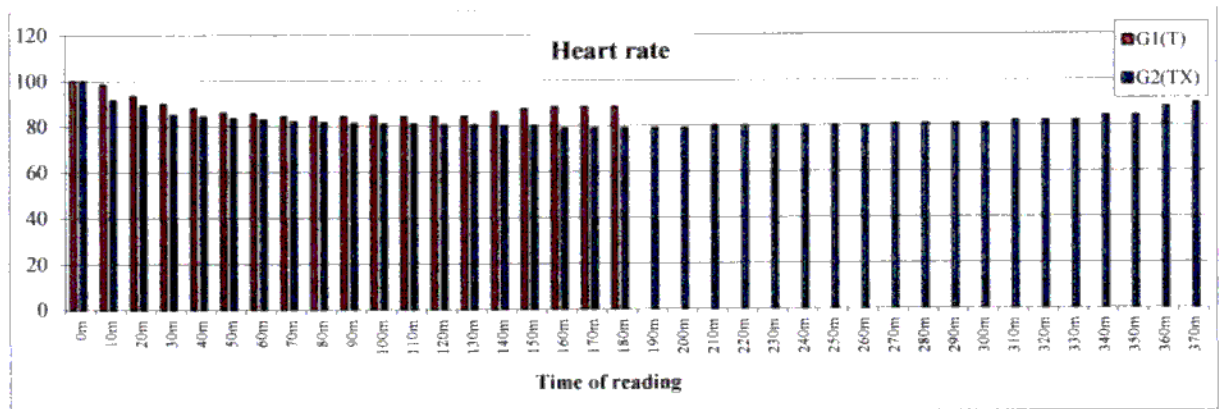


Fig. (9) The heart rate in goats after lumbosacral epidural injection with, G1 (Tramadol), and G2 (Tramadol+Xylazine). See the decrease of heart rate in G2 (TX). Data of heart rate in G1 was ended where the analgesia was ended at 180 min.

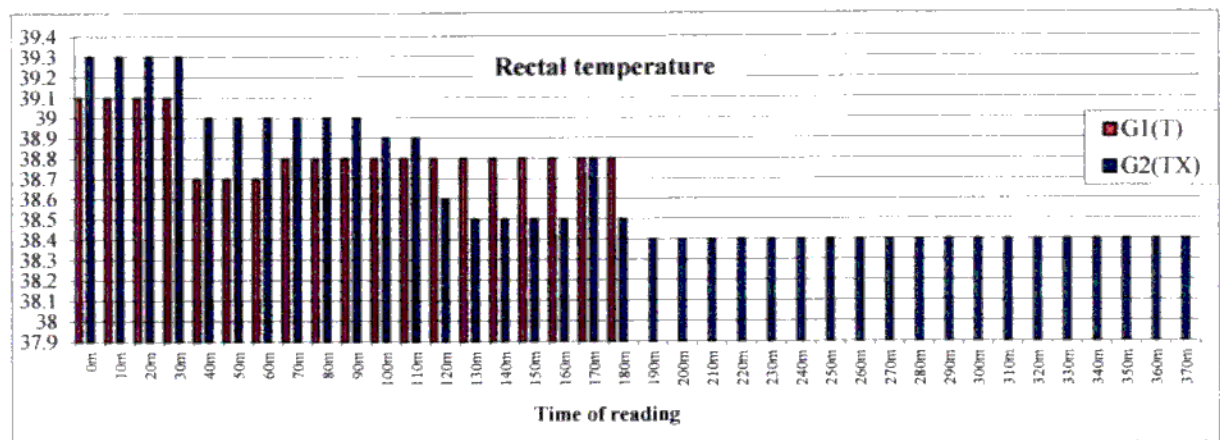


Fig. (10) The rectal temperature in goats after lumbosacral epidural injection with, G1 (Tramadol), and G2 (Tramadol + Xylazine). Data of rectal temp. in G1 was ended where the analgesia was ended at 180 min.


### Discussion

In ruminants, flank region is the common site for laparotomy such as caesarian section, rumenotomy, intestinal obstruction, volvulus, ruminal fistula, foreign body and hernia (16, 17). The flank is innervated by the last thoracic nerve (T13), first lumbar (L1) and second lumbar (L2) spinal nerves (18). These nerves are necessary to block for operation carried out through flank region. During regional anesthesia of flank, nerves

are blocked through injected of anesthetic drugs as they emerge from the vertebral canal through the vertebral foramina in proximal paravertebral nerve block or more distally at free ends of the lumbar transverse process and posterior border of the head of the last rib during distal paravertebral nerve block (16, 17). From the results a significant deep analgesia in all groups is gained at 10 min. after giving of drugs epidurally. This result is in agreement with the previous studies in different species of animals (3, 8, 19, 20, 21). The lumbo-sacral injection of tramadol in G1 is gained deep high and low flank analgesia at 10 min. The onset of analgesia is delayed 10 minutes. Similar results have been demonstrated by other authors (8, 22, 23). Tramadol influences the monoaminergic system with pain modulating effects. It inhibits norepinephrine and 5-hydroxy-tryptamine reuptake. Further to that tramadol exerts a local anesthetic type effect on peripheral nerves (24). Also it has been seen effective when used as subcutaneous local anesthetic (25, 26). Tramadol also act as agonist of transient receptor potential vanilloid-1 (TRPV1) (is a nonselective calcium permeable cation channel, which was originally described on nociceptive sensory afferents as a central integrator of pain sensation), activation of TRPV1 on sensory neurons is followed by a local release of vasoactive neuropeptides and a marked desensitization of the afferent fibers (termination of pain sensation) explaining the analgesic as well as the local anesthetic effect of tramadol (27). The duration of deep high flank analgesia in G1 extend to 110 min. These results agree with study in goats (23) and less than other study in lambs that it reached to 318 min. (8). Further analgesia produced in the regions of tail, inguinal, hind limbs, fore limbs and ear. These results are in agreement with other studies (8, 23). The RR and RT are show less decrease than the zero time reading (control reading), this result is in agreement with (8, 23). The HR in G1 is decreased slowly. This result is disagreed with (11) in lambs who found lightly rise in HR. Tramadol may be advantageous because of low risk of respiratory depression, does not have alpha or beta receptor affinity, but it has an affinity for mu- receptor, also tramadol inhibits the reuptake of norepinephrine and serotonin, thus increasing the concentrations of these two neurotransmitters in the central nervous system, the pharmacological profile of tramadol such as activation of opioid receptors, inhibition of the monoaminergic system and local anesthetic effect (28). The addition of xylazine to the tramadol in G2 causes significant deep high flank analgesia between 10-320 min. The xylazine as a  $\alpha_2$  agonist drugs produce analgesia through both local and central mechanisms. In group G1 there is no deep analgesia in forelimbs and ears indicating the local effect of tramadol on the spinal nerves to produce analgesia, not the systematic effect (19, 29, 30). Tramadol and xylazine in lumbosacral epidural combination has got synergistic effect in our study. Since both  $\alpha_2$  agonist and opioid give analgesia through both spinal and central actions. This is not surprising because  $\alpha_2$  adrenoceptors and opioid receptors share similar regions of the brain and even some of the same neurons. Binding of either  $\alpha_2$  adrenergic or  $\mu$  opioid receptor against results in activation of the same transduction system (1). The analgesia are extend to low flank, tail, inguinal, hind limb, fore limb and ear and slowly decrease in HR, RR and RT. The increase of analgesia in the other parts of the body also due to the synergistic effect of the tramadol and xylazine. While the analgesia of forelimb and ear, it attributed to the systemic effect of xylazine after absorption from the spinal venous plexuses, and reaching to the CNS by blood circulation. The depression effect on the HR, RR and RT also due to the effect of xylazine. In all species of animals xylazine cause marked bradycardia due to central stimulation and mediated through the vagus nerves. In ruminant tachypnea may occur, reaching to breathing appears to require a considerable effort. Further to that xylazine cause an increase in urination, through inhibition of ADH release, also induce hypothermia (1). In G2 the animal showed varied sings of ataxia, sedation, some salivation, cardio-respiratory depression and decrease in body temperature, which attributed to the anesthetic action of xylazine. These sings has also been reported by (31, 32, 33, 34, 35) in calves goats and cattle.

### References

1. Hall, L. W.; Clarke, K. W. & Trim, C. M. (2001). Veterinary Anesthesia, 10<sup>th</sup> ed. W. B Saunders, London, 3, 226: 83-87: 320-341.
2. Sadegh, A. B.; Shfie, Z. & Nazhvani, S. D. (2009). Comparison of epidural anesthesia with lidocaine-distilled water and lidocaine-magnesium sulfate mixture in goats. Veterinarski Arhiv., 79: 11-17.
3. Sakrda, R. T. & Tranquilli, W. J. (2007). Local and regional anesthetic and analgesic techniques: Ruminant and swine. In: Tranquilli, W. J.; Thurmon, J. C.; Grimm, K. A. ed., Lumb and Jones, Veterinary Anesthesia and Analgesia. 4<sup>th</sup> ed. Ames, IA: Blackwell publishing, PP. 643-681.
4. Elhakim, M.; El-Megid, W. A.; El-Hennawy, A. & El-Queseny, K. (2005). Analgesic and antacid properties of i.m. tramadol given before Caesarian section under general anesthesia. Br. J. of Anesth., 95: 811-815.
5. Natalini, C. C. & Robinson, E. P. (2003). Effects of epidural opioid analgesic on heart rate, arterial blood pressure, respiratory rate, body temperature, and behavior in horses. Veterinary Therapeutics, 4: 364-375.
6. Siddik-Sayyid, S.; Aouad-Maroun, M.; Sleiman, D.; Sfeir, M. & Baraka, A. (1999). Epidural tramadol for postoperative pain after cesarean section. Can. J. Anesthesia, 46:731-735.
7. Kaki, A. M. & Marakbi, W. (2008). Post herniorrhaphy infiltration of tramadol versus bupivacaine for post-operative pain relief: randomized study. Ann. Saudi Med., 28:165-168.
8. Habibian, S.; Bigham, A. S. & Aali, E. (2010). Comparison of lidocaine, tramadol, and lidocaine-tramadol for epidural analgesia in lambs. Res. Vet. Sci., 91:434-438.
9. Lemke, K. A. (2007). Anticholinergics and sedative. In: Tranquilli, W. J.; Thurmon, J. C. & Grimm, K. A., ed. Lumb and Jones, Veterinary Anesthesia and Analgesia. 4<sup>th</sup> ed. Ames, IA: Blackwell publishing, PP. 203-239.
10. Al-Jabouri, K. U. H. (2009). Evaluation the effect of xylazine and fentanyl injected epidurally in goats. M.Sc. Thesis, College of Vet. Med. Al-Qadisiya University, Iraq.
11. Fubini, S. I. & Ducharme, N. G. (2004). Farm Animal Surgery. W. B. Saunders. P. 429.
12. Al-Kattan, L. M. D. (1999). Using alpha 2 adrenergic agonist xylazine and medetomidine for injection in epidural space in goats. M.Sc. Thesis, College of Vet. Med. Univ. of Mosul. Iraq.
13. DeRossi, R.; Sampaio, B. F. B.; Varela, J. V. & Junqueira, A. L. (2004). Perineal analgesia and hemodynamic effects of the epidural administration of meperidine or hyperbaric bupivacaine in conscious horses. Can. Vet. J., 45: 42-47.
14. Yanagitate, F. & Dohi, S. (2004). Epidural oxycodone or morphine following gynecological surgery. Br. J. Anesth., 93 (3):362-367.
15. Al-Rawi, K. M. & Kalaf-Allah, A. M. (1980). Design and analysis of agriculture experiments. Dar-Alkutub. Mosul-Iraq and Spss10. ANOVA analysis.
16. Kumar, A. (2003). Paravertebral Anesthesia. In: Veterinary Surgical Techniques 1<sup>st</sup> Ed., Vikas Publishing House PVT.LTD., New Delhi, India, PP.117-119.
17. Lee, L. (2006). Local anesthesia and analgesia. In: Veterinary Surgery. Vol. 1, PP.12-18. cvhs.okstate. edu/vmed5412/pdf/14 Local Anesthesia 2006.
18. Getty, R. (1975). The Anatomy of The Domestic Animals. Sisson and Grossmans 1, 5<sup>th</sup> ed. W. B. Saunders Co. Philadelphia, PP.1065-1080.
19. DeRossi, R., Junqueira, A. L. & Beretta, M. P. (2003). Analgesia and systemic effects of ketamine, xylazine and lidocaine after subarachnoid administration in goats. Am. J. Vet. Res., 64(1):51-56 (Abstract).





20. Kamiloglu, A.; Kamiloglu, N. N.; Ozturk, S.; Atalan, G. & Kılıc, E. (2005). Clinical assessment of epidural analgesia induced by xylazine-lidocaine combination accompanied by xylazine sedation in calves. *Irish Vet. J.*, 58: 567-570.
21. Adetunji, A.; Ajadi, R. A. & Opiya, R. E. (2002). Comparison of epidural anesthesia with Xylazine, Bupivacaine and Bupivacaine/Xylazine mixture in west African dwarf goats. *Isr. J. Vet. Med.*, 57: 104-109.
22. Bigham, A.; Habibian, S.; Ghasemian, F. & Layeghi, S. (2010). Caudal epidural injection of lidocaine, tramadol, and lidocaine-tramadol for epidural anesthesia in cattle. *J. Vet. Pharmacol. Ther.*, 33: 439-443.
23. Dehkordi, S. H.; Bigham-Sadegh, A. & Gerami, R. (2012). Evaluation of anti-nociceptive effect of epidural tramadol, tramadol-lidocaine and lidocaine in goats. *Vet. Anesth. and Analg.*, 39 (1): 106-110.
24. Tsi, Y. C.; Chang, P. J. & Jou, M. (2001). Direct tramadol application on sciatic nerve inhibits special to sensory evoked potentials in rats. *Anesth. Analg.*, 92: 1547-51.
25. Altunkaya, H.; Ozer, Y.; Karagi, E.; Ozkock, I.; Hosnuter, M.; Dimirel, C. B. & Babuccu, O. (2004). The postoperative analgesic effect of tramadol when used as subcutaneous local anesthetic. *Anesth. Analg.*, 99:1461-1464.
26. Kargi, K.; Babuccu, O.; Altunkaya, H.; Hosnuter, M.; Ozer, Y.; Babuccu, B. & Payasli, C. (2008). Tramadol as a local anesthetic in tendon repair. *Surgery of the Hand*. 36: 971-978.
27. Marincsak, R.; Toth, B. I.; Czifra, S. T.; Kovacs, L. & Biro, T. (2008). The analgesic drug, tramadol, acts as an agonist of the transient receptor potential vanilloid-1. *Anesth. Analg.*, 106: 1890-1896.
28. Altunkaya, H.; Ozer, Y.; Karg, E. & Babuccu, O. (2003). Comparison of local anesthetic effect of tramadol with prilocaine for minor surgical procedures. *Br. J. Anesth.*, 90: 320-322.
29. Khan, M. A.; Ashraf, M.; Pervez, H.; Rashid, B.; Mohmood, A. K. & Chaudhry, M. (2004). Comparative effects of detomidine and xylazine as sedative and analgesic agents in small ruminants. *Paki. Vet. J.*, 24(2): 62-69.
30. Singh, K. & Kinjavadekar, P. (2007). Comparison of the analgesic, clinicophysiological and hematobiochemical effects of epidural bupivacaine in healthy and uremic goats. *Small Rumin. Res.*, 71(1):13-20.
31. Singh, V.; Kinjavdekar, P. A.; Pratap, K. & Aithal, H. P. (2003). Comparison of xylazine and medetomidine with and without ketamine for epidural analgesia in buffalo calves. *Indian J. Vet. Surg.*, 24 (2): 76-82.
32. Picavet, M. T.; Gasthuys, F. M.; Laevens, H. H. & Watts, S. A. (2004). Cardiopulmonary effects of combined xylazine-guaiphenesin-ketamine infusion and extradural (inter-coccygeal lidocaine) anesthesia in calves. *Vet. Anesth. and Analg.*, 31: 11-19.
33. DeRossi, R.; Junqueira, A. L. & Bertta, M. P. (2005). Analgesic and systemic effects of xylazine, lidocaine and their combination after subarachnoid administration in goats. *Al-S Afr. Vet. Ass.*, 76: 79-84.
34. Umar, M. A. & Gapsiso, R. H. (2008). Comparison of xylazine, lignocaine and combination of xylazine and lignocaine for epidural anesthesia in goats. *Nigerian Vet. J.*, 29(2):15-19.
35. Abid, T. A. (2002). Caudal epidural injection of xylazine in cattle. *Al-Qadisiya J. Vet. Med. Sci.*, 2(1): 32-33.