

## Comparative Protective Effect of Zileuton and MK-886 against Acute Kidney Injury Induced by Doxorubicin

Ahmed M Sultan, Hussam H Sahib, Hussein A Saheb\* and Bassim I Mohammad

College of Pharmacy, University of Al-Qadisiyah, Iraq

\*Corresponding author: Hussein A Saheb, College of Pharmacy, University of Al-Qadisiyah, Al Qadisiyah, Governorate, Al Oruba city, Iraq, Tel: 009647817955666; E-mail: hu.za815@gmail.com

Received Date: October 11, 2018; Accepted Date: October 16, 2018; Published Date: October 22, 2018

### Abstract

**Objective:** To determine the protective effects of the leukotriene inhibitors MK-886 and Zileuton on doxorubicin (DX)-induced acute kidney damage in a rat model.

**Methods:** A rat model of acute kidney injury (AKI) was established by a 3-day regimen of DX. The animals were suitably treated with MK-866 or Zileuton, and untreated DX injected and healthy controls were also included. The rat sera were analyzed for the levels of creatinine and urea as markers of renal injury and for the levels of the oxidative stress markers GSH and MDA using standard assays. In addition, the renal tissues of the rats were processed and histo-pathologically analyzed by HE staining.

**Results:** DX injection significantly increased the levels of creatinine and urea, indicating dysfunctional kidneys. The levels of both metabolites were restored to baseline levels by MK-866 while Zileuton significantly affected only urea levels. In addition, the GSH levels were significantly decreased and that of MDA was increased upon DX exposure, indicating oxidative damage. While MK-866 treatment significantly reversed the status of both GSH and MDA compared to the DX group, Zileuton had no significant effects on the levels of either. Finally, DX caused extensive renal tissue damage, which was rescued by MK-866 and to a lesser extent by Zileuton.

**Conclusions:** Zileuton and MK-886 have a protective effect against AKI induced by doxorubicin, with MK-886 performing better than Zileuton.

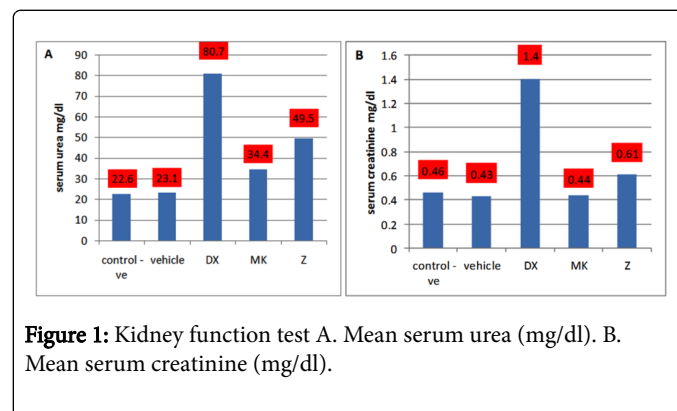
**Keywords:** Leukotriene inhibitors MK-886; Zileuton; Doxorubicin (DX)-induced acute kidney damage; Dysfunctional kidneys; Creatinine; Urea; Acute renal failure

**Abbreviations:** AKI: Acute kidney injury; CKD: Chronic kidney disease; ARF: Acute renal failure; DX: Doxorubicin; LT: Leukotrienes; Cys-LTs: Cysteinyl leukotrienes; PMN: Polymorphonuclear neutrophil

### Introduction

Acute kidney injury (AKI) is characterized by a sudden (about several hours to several days) decline in renal tissue function [1]. Several studies have shown that AKI often progresses to chronic kidney disease (CKD), resulting in high mortality and morbidity [2]. Despite treatment options, development of acute renal failure (ARF) is associated with increased mortality rates from 40% to 90%, as well as non-renal complications [3]. The increasing prevalence of AKI has been reported in both developing and developed countries and is consistently associated with increased mortality and morbidity, as well as increased incidence of CKD [4]. Every year, 2 million people die of AKI worldwide [5].

Doxorubicin (DX) has been used for cancer treatment since 1969. However, due to its considerable renal, cardiac, pulmonary, hematological, and testicular toxicities [6], its use in chemotherapy has greatly decreased. The toxic effects of DX are attributed to increased oxidative stress due to lipid peroxidation and protein oxidation that leads to tissue injury [7]. Although the exact underlying mechanism of DX-induced nephrotoxicity is not yet known, it is likely related to the generation of free radicals, and oxidative damage of iron-dependent macromolecules, membrane lipid peroxidation and protein oxidation [8].



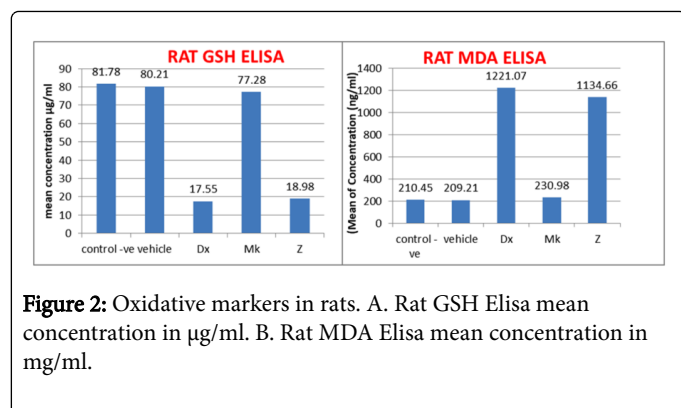
**Figure 1:** Kidney function test A. Mean serum urea (mg/dl). B. Mean serum creatinine (mg/dl).

Leukotrienes (LT) are pro-inflammatory lipid mediators produced by 5-lipoxygenase-mediated arachidonic acid oxidation [9]. Zileuton is a strong inhibitor of 5-lipoxygenase and can block the formation of cysteinyl leukotrienes (Cys-LTs) and LTB<sub>4</sub>. It is also used to ameliorate the symptoms of asthma [10,11]. MK-886 is a suppressor of LT production in vitro and in vivo and inhibits the activation and translocation of 5-lipoxygenase by inhibiting LT biosynthesis indirectly by a membrane-bound 5-lipoxygenase-activating protein [12].

### Materials and Methods

#### Animals

Thirty healthy adult male albino rats weighing on an average 220 ± 20 g were housed at the animal facility of the College of Pharmacy, University of Al-Qadisiyah under 12 hours light/12 hours dark cycle at 28 ± 2 °C. The animals were given standard rodent chow diet and tap water.



**Figure 2:** Oxidative markers in rats. A. Rat GSH Elisa mean concentration in µg/ml. B. Rat MDA Elisa mean concentration in ng/ml.

## Materials

Doxorubicin Ebewe (50 mg in 25 ml) was purchased from EBEWE Pharma Ges. MBH (4866-A Unterach, Austria). Zileuton (Lot A2513) and MK-886 (Lot H3116) were purchased from Santa Cruz Biotechnology.

## Experimental design

The rats were randomized into five groups (n=6): a) control untreated rats with free access to water and standard diet, b) vehicle group—ethanol injection i.p. c) DX group daily single dose of DX (15 mg/kg i.p.) [13] d) MK group-0.6 mg/kg i.p. MK-886 30 minutes before DX administration [12] and e) Z group-10 mg/kg i.p. Zileuton 30 minutes before DX administration [14]. After three days of DX regimen, all rats were sacrificed by intraperitoneal injection of sodium thiopental (70 mg/kg) [15].

## Determination of serum urea and creatinine levels

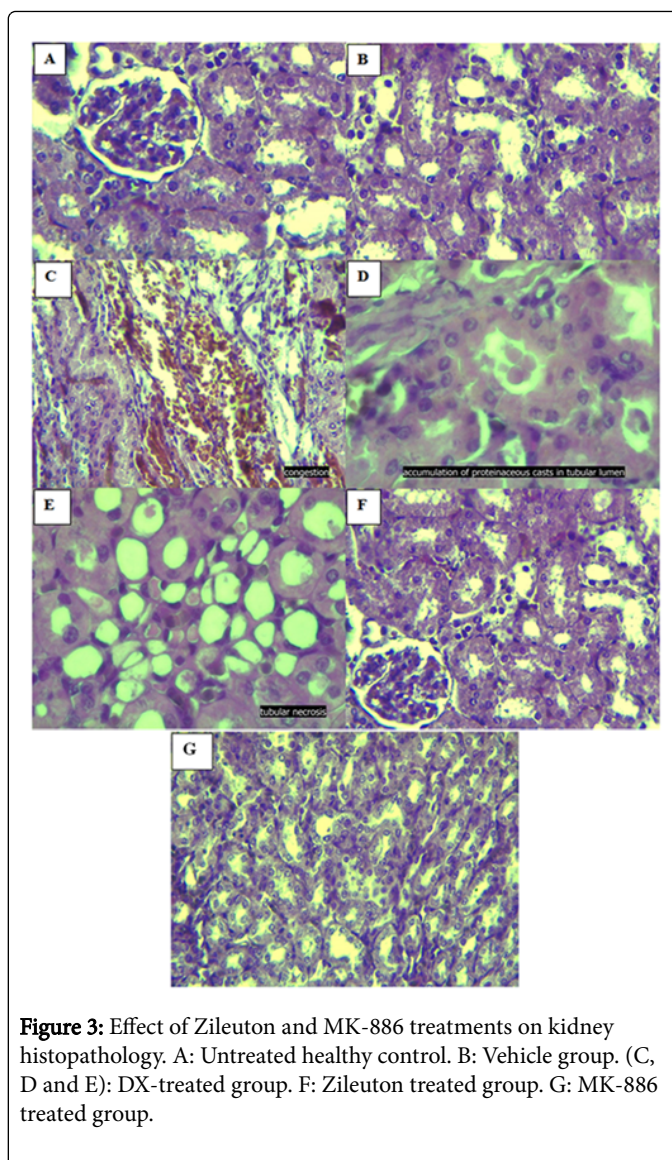
Blood was drawn and placed immediately in gel separator tubes and allowed to clot at 25 °C. The blood samples were centrifuged at 30 °C for 10 minutes at 3000 rpm, and the supernatant layer of the serum was carefully aspirated with a pipette into another dry tube. The sera were frozen at -30 °C till further analysis.

## Determination of GSH and MDA levels

Serum glutathione (GSH) levels (µg/ml) were measured using GSH ELISA Kit Catalog No: E-EL-0026 (96T), and serum malondialdehyde (MDA) levels (ng/ml) with MDA ELISA Kit Catalog No: E-EL-0060 (96T) from Elabscience Biotechnology Inc. according to the manufacturer's instructions.

## Histopathological examination

Right kidneys were removed from each rat and fixed in 10% neutral buffered formalin and embedded in paraffin. Histopathological evaluation was done using a semi-quantitative scale as follows: 3+ = severe, 2+ = moderate, 1+ = mild, 0= not found [16].



**Figure 3:** Effect of Zileuton and MK-886 treatments on kidney histopathology. A: Untreated healthy control. B: Vehicle group. (C, D and E): DX-treated group. F: Zileuton treated group. G: MK-886 treated group.

## Statistical analysis

SPSS 12.0 program for windows was used for statistical analysis. Results were presented as means ± SE using a one-way analysis and Dunnett's test with significance threshold at p<0.05.

## Results

### Effect of Zileuton and MK-886 treatment on the functional biomarkers of kidney

DX resulted in a significant increase in creatinine and urea levels compared to the untreated controls (P<0.05). MK-886 treatment significantly decreased creatinine and urea levels (p<0.05) compared to the DX group rats. Zileuton, on the other hand, significantly decreased serum urea (P<0.05), but only moderately decreased the serum creatinine levels compared with the DX group. The vehicle did not affect study parameters (Figure 1).

### Effect of Zileuton and MK-886 treatment on GSH and MDA levels

DX-treated rats showed a significant decrease in GSH levels compared to the untreated controls. While MK-866 treatment significantly increased GSH levels compared to the DX group, no significant changes were seen after Zileuton treatment. In contrast, the MDA levels were significantly higher in the DX group compared to untreated control group. MK-866 treatment significantly reduced the MDA levels compared to the DX group while Zileuton did not result in any significant change. The vehicle did not have any effect on MDA and GSH levels (Figure 2).

### Effect of Zileuton and MK-886 treatments on kidney histopathology

The untreated control and vehicle groups showed normal kidney tissue architecture (Figures 3A,3B). Renal tissues of the DX group showed varying degrees of damage (Figures 3C-3E) while that of the Z group had mild to moderate proteinaceous accumulation in tubular lumen, mild necrosis, and mild to moderate tubular congestion (Figure 3F). Finally, the MK-886 treated group showed mild proteinaceous accumulation without tubular congestion or necrosis (Figure 3G).

Findings	-Ve control gr.	Vehicle gr.	DX-treated gr.	Z plus DX-treated gr.	MK plus DX-treated gr.
Accumulation of Proteinaceous casts in the tubular lumen	0	0	+2 (3/6) +3 (3/6)	0 (3/6) +1 (2/6) +2 (1/6)	0 (4/6) +1 (2/6)
Tubular necrosis	0	0	+1 (4/6) +2 (2/6)	0 (3/6) +1 (3/6)	0 (6/6)
Congestion	0	0	+1 (2/6) +2 (4/6)	0 (2/6) +1 (3/6) +2 (1/6)	0 (4/6) +1 (2/6)

**Table 1:** Kidney histological evaluation of the rats [Severity scores: 0=Not found; 1+ = Mild; 2+ = Moderate; 3+ = Severe].

### Discussion

Anti-cancer drugs usually target some physiological functions that may also affect healthy tissues. For example, the use of anthracyclines like DX is limited due to its significant toxicity in several organs such as kidneys [17]. Nephrotoxic effects of DX are correlated with free radical induction [18]. In our study, DX mediated nephrotoxicity was indicated by the significant increase in the levels of the serum creatinine and urea, sensitive indicators of renal function [19] along with histopathological injuries. DX mediates its nephrotoxic action by decreasing the rate of glomerular filtration which leads to increased levels of these markers, consistent with previous studies [20].

GSH is an antioxidant produced by the GST and GPx enzymes that quenches the O<sub>2</sub> generated from the DX [21]. Consistent with other studies [22], we found that GSH levels were significantly decreased in the sera of rats treated with DX compared to untreated controls. Oxidative stress results in cellular dysfunction by lipid peroxidation of cellular membranes. One of the end products of lipid peroxidation or -oxidation is MDA [23]. Concomitantly, we also found significantly high levels of MDA upon DX treatment, as reported previously by Yagmurca [24].

MK-886 is an inhibitor of leukotriene B<sub>4</sub> (LTB<sub>4</sub>) and cysteinyl leukotrienes (cysLTs) biosynthesis. Şener discovered its protective role in a rat model of renal ischemia [25], where it blocked polymorphonuclear neutrophil (PMN) infiltration in the ischemic tissues and prevented ROS production. Furthermore, MK-886 also inhibits iNOS, thereby blocking NO production, protein and DNA damage and lipid peroxidation, which prevents oxidative damage and dysfunction of the renal tissue [26]. In agreement with the above, MK-886 administration resulted in a significant decrease in serum urea and

creatinine levels, along with higher GSH and lower MDA levels when compared to the DX-treated group.

Zileuton, an inhibitor of 5-lipoxygenase and LTs, has also been shown to decrease MDA levels in rats. It also blocks NF-κB and iNOS activation, which downregulates inflammatory response and oxidative stress response, respectively [27]. Najah demonstrated that Zileuton also significantly reduced the serum GSH titer [10]. In contrast, Zileuton had no effect on the oxidative stress markers in our study.

Noiri et al showed that LTB<sub>4</sub> was an important factor in activation of the PMNs in ischemic kidneys, and LTB<sub>4</sub> receptor-antagonists prevented PMN infiltration [28]. Furthermore, inhibiting LTB<sub>4</sub> biosynthesis by MK-886 also decreased PMN activation and infiltration by reducing the expression of cell-adhesion molecules and endothelium layer attachment, and blocking the release of proteases, ROS, cytokines, myeloperoxidase (MPO) and elastase [29]. Daglar et al showed similar results in ischemic hepatic tissue in rats and found that LT inhibition by MK-886 or montelukast had therapeutic and protective effects against I/R injury by decreasing apoptosis and inhibiting ROS formation [30].

We also demonstrated that the Zileuton-treated rats had mild to moderate kidney damage while the MK-886 treated ones showed mild kidney damage compared to the DX group. Nimesh et al showed a reduction in the renal I/R injury in the 5-lipoxygenase knockout mice by Zileuton [31]. Finally, this is the first study to show any beneficial effect of MK-886 on kidney damage.

### Conclusion

Zileuton and MK-886 have a protective effect against AKI induced by doxorubicin, with MK-886 performing better than Zileuton.

## References

1. Singbart K, Joannidis M (2015) Short-term effects of acute kidney injury. *Crit Care Clin* 31: 751-762.
2. Mehta RL, Cerda J, Burdmann EA, Tonelli M, Garcia GG, et al. (2015) International society of nephrology's by 25 initiative for acute kidney injury (zero preventable deaths by 2025): a human rights case for nephrology. *Lancet* 385: 2616-2643.
3. Dirkes S (2011) Acute kidney injury: not just acute renal failure anymore? *Crit Care Nurse* 31: 37-50.
4. Li PK, Burdmann EA, Mehta RL (2013) Acute kidney injury: global health alert. *Kidney Int* 83: 372-376.
5. Murugan R, Kellum JA (2011) Acute kidney injury: what's the prognosis. *Nat Rev Nephrol* 7: 209-217.
6. Fadillioglu E, Erdogan H, Sogut S, Kuku I (2003) Protective effects of erdosteine against doxorubicin-induced cardiomyopathy in rats. *J Appl Toxicol* 23: 71-74.
7. Karaman A, Fadillioglu E, Turkmen E, Tas E, Yilmaz Z (2006) Protective effects of leflunomide against ischemia-reperfusion injury of the rat liver. *Pediatr Surg Int* 22: 428-434.
8. Liu LL, Li QX, Xia L, Li J, Shao L (2007) Differential effects of dihydropyridine calcium antagonists on doxorubicin-induced nephrotoxicity in rats. *Toxicology* 231: 81-90.
9. Golden PM, Henderson WR (2007) Leukotrienes. *N Engl J Med* 357: 1841-1854.
10. Hadi NR, Mohammad BI, Ajeena IM, Mahmood A, Majeed SA, et al. (2015) Leukotriene synthesis inhibitors modulate atherosclerosis progression in hypercholesterolemic rabbits. *RJPBCS* 6: 363.
11. Hadi NR, Mohammad BI, Almudhafer A, Yousif N, Sultan AM (2013) Montelukast and zileuton retard the progression of atherosclerosis via down-regulation of the inflammatory and oxidative pathways. *J Clin Exp Cardiol* 4: 250.
12. Amran FG, Hadi NR, Hashim AM (2011) Leukotriene biosynthesis inhibition ameliorates acute lung injury following hemorrhagic shock in rats. *J Cardiothorac Surg* 6: 81.
13. Mansour MA, El-Kashif HA, Al-shabanah OA (1999) Effect of captopril on doxorubicin-induced nephrotoxicity in normal rats. *Pharmacol Res* 39: 233-237.
14. Rossi A, Pergola C, Koeberle A, Hoffmann M, Dehm F, et al. (2010) The 5-lipoxygenase inhibitor, zileuton, suppresses prostaglandin biosynthesis by inhibition of arachidonic acid release in macrophages. *Br J Pharmacol* 161: 555-570.
15. Bolat D, Selcuk M (2013) Stereological and biochemical evaluation of diclofenac-induced acute nephrotoxicity in rats. *Revue Med Vet* 164: 290-294.
16. Palipoch S, Punsawad C, Chinnapun D, Suwannalert P (2013) Amelioration of cisplatin-induced nephrotoxicity in rats by curcumin and  $\alpha$ -tocopherol. *Trop J Pharm Res* 12: 973-979.
17. Injac R, Boskovic M, Perse M, Furlan KE, Cerar A, et al. (2008) Acute doxorubicin nephrotoxicity in rats with malignant neoplasm can be successfully treated with fullerol C60 (OH) 24 via suppression of oxidative stress. *Pharmacol Rep* 60: 742-749.
18. Rashid S, Ali N, Nafees S, Ahmad ST, Arjumand W, et al. (2013) Alleviation of doxorubicin-induced nephrotoxicity and hepatotoxicity by chrysin in Wistar rats. *Toxicol Mech Methods* 23: 337-345.
19. Khan N, Sultana S (2004) Abrogation of potassium bromate-induced renal oxidative stress and subsequent cell proliferation response by soy isoflavones in Wistar rats. *Toxicology* 201: 173-184.
20. Mohan M, Kamble S, Gadhi P, Kasture S (2010) Protective effect of Solanum torvum on doxorubicin-induced nephrotoxicity in rats. *Food Chem Toxicol* 48: 436-440.
21. Shinde N, Jagtap A, Undale V, Kotwal S, Patil R (2010) Protective effect of Lepidium sativum against doxorubicin-induced nephrotoxicity in rats. *Res J Pharm Biol Chem Sci* 1: 42-49.
22. Sheikh AK, Morsy MA, Mahmoud MM, Rifaai RA, Abdelrahman AM (2012) Effect of coenzyme-Q10 on doxorubicin-induced nephrotoxicity in rats. *Adv Pharmacol Sci* 8.
23. Morsy MA, Ibrahim SA, Amin EF, Kamel MY, Rifaai RA, et al. (2013) Curcumin ameliorates methotrexate-induced nephrotoxicity in rats. *Adv Pharmacol Sci* 7.
24. Yagmurca M, Erdogan H, Iraz M, Songur A, Ucar M, et al. (2004) Caffeic acid phenethyl ester as a protective agent against doxorubicin nephrotoxicity in rats. *Clinica Chimica Acta* 348: 27-34.
25. Sener G, Sehirli O, Ogunc VA, Cetinel S, Gedik N, et al. (2006) Montelukast protects against renal ischemia/reperfusion injury in rats. *Pharm Res* 54: 65-71.
26. Meister A (1988) Glutathione metabolism and its selective modification. *J Biol Chem* 263: 17205-17208.
27. Tu XK, Yang WZ, Wang CH, Shi SS, Zhang YL, et al. (2010) Zileuton reduces inflammatory reaction and brain damage following permanent cerebral ischemia in rats. *Inflammation* 33: 344-352.
28. Noiri E, Yokomizo T, Nakao A, Izumi T, Fujita T, et al. (2000) An in vivo approach showing the chemotactic activity of leukotriene B4 in acute renal ischemia-reperfusion injury. *Proc Natl Acad Sci USA* 97: 823-828.
29. Rabb H, Meara YM, Maderna P, Coleman P, Brady HR (1997) Leukocytes, cell adhesion molecules and ischemic acute renal failure. *Kidney Int* 51: 1463-1468.
30. Daglar G, Karaca T, Yuksek YN, Gozalan U, Akbiyik F, et al. (2009) Effect of Montelukast and MK-886 on Hepatic Ischemia-Reperfusion Injury in Rats. *J Surg Res* 153: 31-38.
31. Patel NA, Cuzzocrea S, Chatterjee PK, Di Paola R, Sautebin L, et al. (2004) Reduction of Renal Ischemia-Reperfusion Injury in 5-Lipoxygenase Knockout Mice and by the 5-Lipoxygenase Inhibitor Zileuton. *Mol Pharmacol* 66: 220-227.