ResearchGate

See discussions, stats, and author profiles for this publication at: https://www.researchgate.net/publication/297255468

STUDY OF EFFECTS OF WATERY POMEGRANATE PEELS EXTRACT IN THE TREATMENT OF DIARRHEA INDUCED EXPERIMENTALLY IN RATS

Research · March 2016

DOI: 10.13140/RG.2.1.2822.6322

CITATIONS
0

READS
8

1 author:

Ahmed Neama
Alexandria University

9 PUBLICATIONS **0** CITATIONS

SEE PROFILE

All in-text references underlined in blue are linked to publications on ResearchGate, letting you access and read them immediately.

Available from: Ahmed Neama
Retrieved on: 24 October 2016

A Peer Reviewed International Journal of Asian Academic Research Associates

AARJMD

ASIAN ACADEMIC RESEARCH JOURNAL OF MULTIDISCIPLINARY

STUDY OF EFFECTS OF WATERY POMEGRANATE PEELS EXTRACT IN THE TREATMENT OF DIARRHEA INDUCED EXPERIMENTALLY IN RATS

ALI MOHAMMED GHAZI[1] ; HASSAN KHALAF ULAIW[2] ; AHMED JASEM NEM[3]

[1]College of veterinary medicine , Al-Qadissyia university
[1]College of veterinary medicine , Al-Qadissyia university
[1]College of veterinary medicine , Al-Qadissyia university

Abstract

Objective of the study was focused on the study of ant-diarrheal activity of The watery pomegranate extract in diarrheic rats induced experimentally by pathogenic *E.coli* .The results of local study revealed beginning from second week of treatment normal liver and intestine and any abnormal gross lesions not observed in the (GT1) group and that differs completely from the gross lesions that observed in the control positive (GC^+) group where gross lesions characterized by hemorrhagic hepatitis and severe hemorrhagic enteritis, presence of large white sac in the liver and the intestine slightly enlarged and emphysematous, as well as, presence of pasty yellowish contents and presence of large white enlargement in the liver. Also differs from gross lesions observed in the (GT2) group that treatment with *amoxicillin* that revealed congestion of intestine with presence of pasty yellowish contents.

The results of morphological alterations revealed in the (GC^+) after 7 days of induction infection with *E.coli* were include hemorrhagic hepatitis. Changes in the small intestine revealed severe sloughing in the intestinal villi with edema and necrosis in the mucosa, as well as necrosis of intestinal glands, while after 14 days of infection the changes were hemorrhagic necrosis of liver associated with fatty degeneration and accumulation of inflammatory cells. The histopathological changes in the small intestine showed hypertrophy of intestinal villi with accumulation of inflammatory cells. The morphological alterations in (GC^+) after 14 days include hepatitis that characterized congestion with accumulation of inflammatory cells. The morphological alterations in the group (GT1) after 7 days of treatment with *Punica granatum L* showed normal liver texture but there are dilatation of some bile ducts and sinuses as well as engorgement some of bile ducts with bile. At the same time the results of morphological study in the intestine revealed normal intestinal tissues. After 14 days of treatment with *Punica granatum L* the liver undergo the same changes that observed after 7 days of treatment also the intestine. After 21 days of treatment with *Punica granatum L* the intestine showed normal intestinal tissues, but there is a thickening in the muscularis layer of mucosa and enlargement in the intestinal glands that full with secretion. The morphological alterations in the group (GT2) after 7 days of treatment with amoxicillin showed hydropic degeneration with accumulation of inflammatory cells with necrosis of some of hepatocytes, while in the small intestine showed atrophic mucosa thinner than normal and shortened and widely separated. The mucosa consists of irregular glands and many of them containing large droplets of mucin. After 14 days the alterations includes hydropic degeneration with accumulation of inflammatory cells with necrosis of some of hepatocytes, while in the intestine revealed infiltration of the duodenal mucosa by inflammatory cells with loss of villi (villous atrophy), and hyperplasia (elongation) of crypts. After 21 days of treatment with amoxicillin the changes showed flat small bowel mucosa with infiltration of the duodenal mucosa by inflammatory lymphocytes and plasma cells.

Key words: pomegranate watery extracts, diarrhea, *E.coli*, rats.

Introduction:

Infectious bacterial diseases are becoming serious threat in developing countries where peoples are not aware of their primary healthcare. Due to the lack of proper treatment, indiscriminate use of antibiotics and also ignorance are the major problems to control such bacterial diseases. Nowadays, it is a common phenomenon that microorganisms are developing their resistance to many commercial antibiotics that is the major cause of failure to treat various infectious diseases. Therefore, immense clinical problem in the treatment of infectious diseases has been raised [(1).] Diarrhea can be defined as the increased frequency of bowel movements, accompanied by a loose consistency of Stools [(2).] Intestinal disorders especially diarrhoea are a major cause of morbidity and mortality in developing countries The rate of occurrence is usually high in infants and children[(3)] It is often caused by enterotoxins which are produced by bacteria such as *Escherichia coli*, *Salmonella typhi*, *Salmonella typhimurium*, *Clostridium difficile*, *Clostridium freundii*, *Aeromonas hydrophila*, *Campylobacter jejuni* and *Vibrio cholerae*, to name a few [(4).]Generally, antimicrobial agents are used both therapeutically and prophylactically in *E. coli* infection. However, the increased resistance to these drugs has produced an unavoidable side effect of antibiotic use, and recent studies have shown a rapid increase in the prevalence of antibiotic resistance to *E. coli* [(5)] Thus,they may become from important for the development of naturally occurring active compounds from plants or others capable to controlling on this problem . Plants and plant products have been used extensively throughout history to treat medical problems. Numerous studies have been carried out to extract various natural products for screening different disease disorders. .About 80% of the populations in developing countries still use traditional medicine for their healthcare. Modern pharmacopoeias contain at least 25% of drugs derived from plants and many others which are synthetic analogues build on prototype compounds isolated from plants [(6).] Medicinal plants also serve as the starting point for the discovery of semi synthetic chemical compounds. The chemical structures derived from plant substances can also be used as models for new synthetic compounds[(7).] The Pomegranate (*Punica granatum*) belongs to the family of punicaceae . It is an important fruit of tropical and subtropical regions, which originated in the Middle East and India and has been used for centuries in ancient cultures for its medicinal purposes . It is widely reported that pomegranate exhibits antivirus, antioxidant, anticancer, and antiproliferative activities [(8)] . Pomegranate is an important source of bioactive compounds and has been used in folk medicine for many centuries .[(9)] In recent times, the pomegranate plant has attracted the interest of researchers in examining its composition and biological properties.[(10)] Dried fruit peels

are used for treatment of diarrhea , respiratory and urinary tract infections , as well as , pomegranate fruit peels exerted diverse pharmacological functions as antioxidant activity [(11).] So the present study was designed to evaluate the antidiarrhoeal effects of watery extract of pomegranate peels by *E.coli* induced diarrhea in experimental rats.

Materials and methods :

- **Plant materials :**

Pomegranate fruit peels purchased from local market in Al-Diwanyia city , then dried and powdered before extraction.

- **Preparation of watery extract :**

To obtain the watery extract of pomegranate peels , 100 gram of the ground ,air dried peels were packed in the column of soxhlet apparatus (Wisd / Korea) assembly and about 500 ml of distilled water was taken in a round bottomed flask. The apparatus was set up in the mantle and the extraction was carried out for 8 hrs at 100 C. the resultant solution was filtered through a filter paper after that , the filtrates was concentrated by rotary evaporator (IKA / Germany) at 60 C . The yield obtained was found to be 28% from crude material. The dried crude extract was kept in refrigerator at 4 C until use.

- **Laboratory Animals :**

Thirty two adult 12 weeks old, male albino rats (Rattus *norvegicus*), weighing 200-215 gm were used for *in vivo* study. They were obtained from animal's house of the veterinary medicine college, University of Al-Qadissiyia, Iraq. They were housed in standard plastic cages. The animals were kept in a well ventilated room, temperature of 24- 28°C with 12 hrs natural light and 12 hrs darkness. The rats had free access to tap water and dry rat pellets obtained from local market *ad libitum*. Food was withdrawn 18 h before induce of infection with *E.coli* but water was allowed.

- ***E.coli* isolate :**

Clinical isolate of *E.coli* obtained from Educational children hospital in Al-Diwanyia city , Iraq . The strain was isolated from patient with severe gastrointestinal infection. The isolate was re-identified using standard biochemical tests and confirmed by vitek apparatus . after that , the bacterial culture was maintained in MacConkey agar slants at 37°C. The microorganism was reactivated prior

to induce infection by transferring it into a separate test tube containing brain heart infusion broth and incubated overnight at 37°C.

- **Bacterial suspension preparation :**

Respective suitable slant medium was used to activate the bacterial isolate to be tested by means of sterile operation and inoculate it into the corresponding liquid medium it was taken as stock solution after culturing in the constant temperature incubator at the most suitable temperature for 16-18 hrs. Bacterial suspension containing bacteria of about 1×10^8 cell/ ml was prepared with sterile physiological saline for *in vivo* study.

- **Experimental design :**

The rats were allowed to acclimatize for ten days and then divided into 4 equal groups (8 animals per group) . Diarrhea was induced orally in all group rats (Except for negative control group) using *E.coli* suspension prepared previously for this purpose contained 1×10^8 cell / ml . The first group of animals assigned as negative control , the second group (positive control GC^+) received 1 ml of *E.coli* suspension orally and leave without treatment , the third group (GT1) of animals received 1 ml of *E.coli* suspension orally and treated with 200 mg/ml watery extract of pomegranate given orally twice daily , the fourth group (GT2) received 1 ml of *E.coli* suspension orally and treated with amoxicillin (10 mg/Kg) given orally twice daily , all treatments were began immediately after induction of infection . two animals from each groups sacrificed at days 7 , 14 , 21 after induction of infection for examined the development of case , in the same time specimens from intestine , liver was sectioned for detection on histopathological changes.

- **Procedure of routine histological technique:**

Fixation the speciemence in buffered formalin (10%) is the first step in the procedure in the histological study. Tissue speciemence (from livers and intestines) were dehydrated in ascending concentrations of ethanol (70%, 80%, 90% and 100%), after that clearing by xylol. Infiltration is the process by which the xylene is replaced by paraffin. First a 50:50 mixture of xylene (30 minutes) and paraffin followed by two changes of 100% paraffin. The first paraffin bath lasts for 2 hours. The second one is 3 hours to overnight, best not to exceed 5 or 6 hours since tissue tends to shrink in the heat. Infiltration typically occurs in an oven at 58 -60°C. Next the tissues are oriented and embed in a paraffin block. Block is placed in ice water to solidify. Sections (7 µm) were fixed on slides, deparaffinized by place slides in xylene for 10 minutes. Next a second change of xylene for 10 minutes. Slides are then rehydrated through a grades series of alcohols to distilled water. The slides

are then placed in hematoxylin for 3 to 5 minutes. Next place the slides in 70% ethanol for 2 to 5 minutes. Counter stain with eosin in 70% ethanol for 2 to 5 minutes. Rinse off excess eosin. Next dehydrate and clear in xylene. Add a small drop of mounting medium to the slide and finally add a cover slip. Allow to dry before examining.

Results & discussion :

- **The results of gross lesions:**

The results revealed that the gross lesions that observed in the group of control positive (GC^+) after 7 days of induction of infection were hemorrhagic hepatitis and severe hemorrhagic enteritis (figures: 1&2), while after 14 days the gross lesions characterized by presence of large white sac in the liver and the intestine slightly enlarged and emphysematous (figure: 3). After 21 days of induction of infection the lesions includes congestion of intestine with presence of pasty yellowish contents and presence of large white enlargement in the liver (figures: 4 &5). The gross lesions of group (GT1) after 14 days of treatment with *Punica granatum L* showed normal liver and intestine (figure: 6). The lesion that observed in the group (GT2) after 14 days of treatment with *Punica granatum L* includes congestion of intestine with presence of pasty yellowish contents (figure: 7).

- **The results of histopathological study:**

The results revealed that the morphological alterations in the (GC^+) after 7 days of induction of infection with *E.coli* include hemorrhagic hepatitis; there are hepatocytes degeneration (Ballooning cells), extravassated RBCs and accumulation of inflammatory cells. Changes in the small intestine revealed severe sloughing in the intestinal villi with edema and necrosis in the mucosa, as well as necrosis of intestinal glands (figures: 8, 9 &10), while after 14 days of infection the changes were hemorrhagic necrosis of liver associated with fatty degeneration and accumulation of inflammatory cells (figures:11&12). The histopathological changes in the small intestine showed hypertrophy of intestinal villi with accumulation of inflammatory cells (figure: 13). The morphological alterations in (GC^+) after 21 days include hepatitis that characterized congestion with accumulation of inflammatory cells (figures: 14, 15 & 16). The histological examination of infected groups showed mild diffuse inflammation with high numbers of neutrophils which may be due to attachment of bacteria to the intestinal cells which cause lesion progressing with effacement of the microvillus and changing the cells morphology [(12)]. The *E. coli* infection is characterized by *E. coli* attached intimately to the epithelial cell surface membrane with effacement of brush border microvilli and vascular necrosis, as

well as neutrophil mediated epithelial cell destruction [13]. The liver showed swelling of their hepatocytes with decreased sinusoidal spaces and necrotic foci and this may be due to *E coli* infection because there is same degree of liver necrosis displayed by the hepatic cells in all bacterial infections [14], also there is hemorrhagic foci and microthrombi which may caused by intra–vascular –hemolysis [15].

The morphological alterations in the group (GT1) after 7 days of induction of infection and beginning of treatment with *Punica granatum L* showed normal liver texture but there are dilatation of some bile ducts and sinuses as well as engorgement some of bile ducts with bile (figures: 17&18). At the same time the results of morphological study in the intestine revealed normal intestinal tissues (figure: 19). While after 14 days of treatment with *Punica granatum L* the liver undergo the same changes that observed after 14 days of treatment also the intestine (figure: 20). After 21 days of treatment with *Punica granatum L* the intestine showed normal intestinal tissues, but there is a thickening in the muscularis layer of mucosa and enlargement in the intestinal glands that full with secretion (figures: 21, 22 & 23). Many researchers were accordance with our results revealed that the histological examination of liver sections in the rats treated with *P.granatum* against Pentachlorophenol-Induced Oxidative Stress, Cytogenetic Toxicity and hepatic damage in rats showed a normal hepatic architecture with distinct hepatic cells, sinusoidal spaces and a central vein, portal tract with prominent nucleus. There were no abnormalities or histological changes in the liver of rats treated with two doses of *P. granatum* (200 & 400 mg/kg/day) [16].The hepatoprotective effect of pomegranate has been investigated by animal experiments *in vivo* these effect was considered to be probably resulted from the potent antioxidant activity of polyphenols in flower extract of pomegranate[17;18]. Many researchers suggest that an appropriate bioactive compound may be developed from *P. granatum* pericarp as alternative treatment for the *E. coli* O157: H7 infection. The crude plant may also be administered to prevent VT (Verocytotoxin) production in the human intestine to solve the problem of subinhibitory effects from the use of antibiotics [19]. Several studies investigated the antidiarrheal activity of aqueous and alcohol extracts of the pomegranate fruit rind in 3 experimental models using albino rats. The extracts exhibited significant activity in rats when compared to loperamide hydrochloride, astandard antidiarrheal drug [20].

The morphological alterations in the group (GT2) after 7 days of treatment with amoxicillin showed hydropic degeneration with accumulation of inflammatory cells with necrosis of some of hepatocytes (figure: 24), while in the small intestine showed atrophic mucosa thinner than normal and shortened

and widely separated. The mucosa consists of irregular glands and many of them containing large droplets of mucin (figure: 25). After 14 days of treatment with amoxicillin the alterations includes hydropic degeneration with accumulation of inflammatory cells with necrosis of some of hepatocytes, while in the intestine revealed infiltration of the duodenal mucosa by inflammatory cells with loss of villi (villous atrophy), and hyperplasia (elongation) of crypts (figure 26). After 21 days of treatment with amoxicillin the changes showed flat small bowel mucosa with infiltration of the duodenal mucosa by inflammatory lymphocytes and plasma cells (figure: 27).

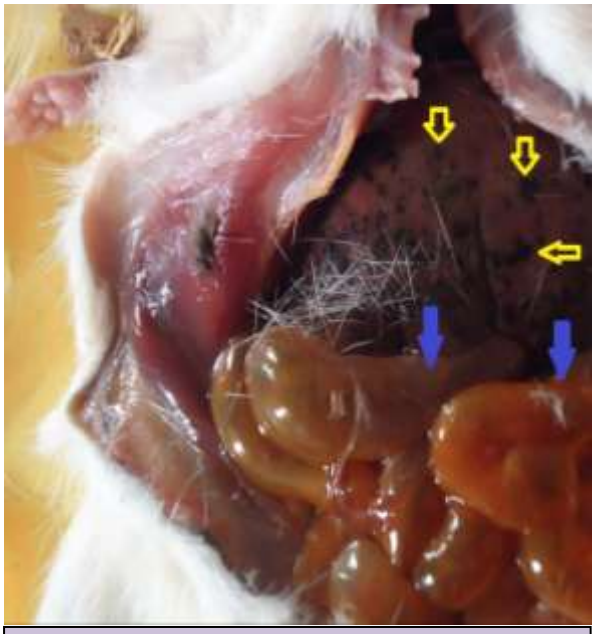

Figure (1) GC^+ : day7: hemorrhagic hepatitis (yellow arrows) and hemorrhagic enteritis (blue arrows).

Figure (2) GC^+ day 7: Severe hemorrhagic enteritis.

Figure (3) GC^+ : day14: presence of large white sac in the liver (yellow arrow) while

Figure (4)GC^+ : day21: gross lesions of intestine and livers showed congestion of

Figure (5) GC^+ day 21: part of small intestine contain pasty yellowish contents.

Figure (6)GT1- day14: gross lesion showed normal liver and intestine after 3 days of treatment.

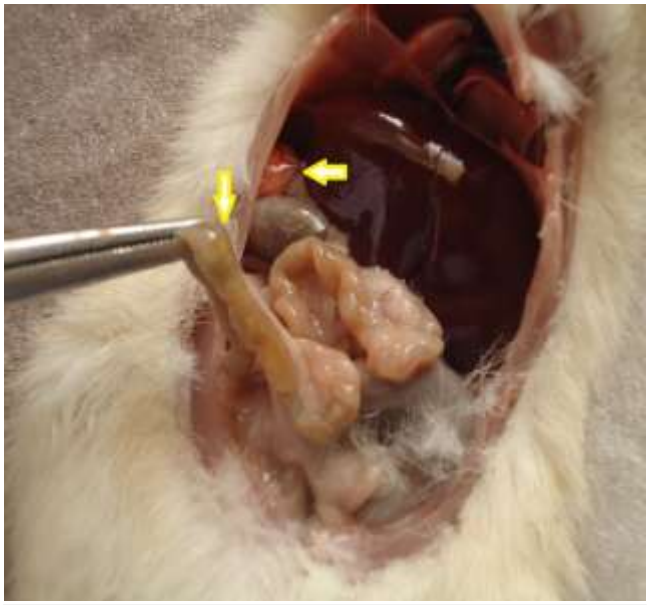

Figure (7) GT2-day14: gross lesions of intestine showed congestion of intestine with presence of pasty yellowish contents.

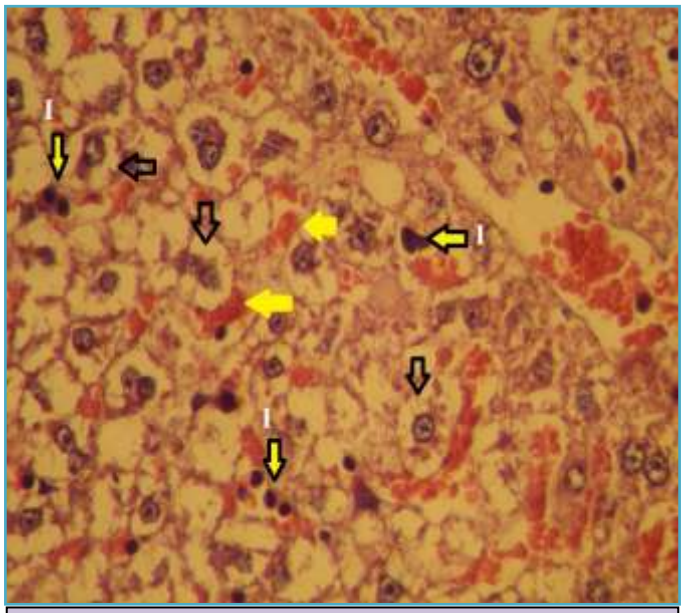

Figure (8) GC^+ - day7: section of liver revealed hemorrhagic hepatitis; there are hepatocytes degeneration (Ballooning cells)(black arrows), extravassated RBCs (yellow arrow) and accumulation of inflammatory cells (I). H&E, 400X.

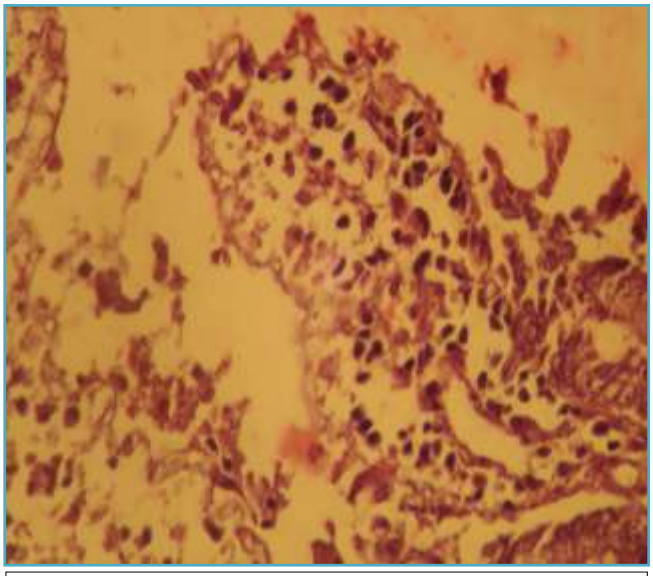

Figure (9)GC^{+}day7: section of small intestine revealed severe sloughing in the intestinal villi with edema and necrosis in the mucosa. H&E, 400X.

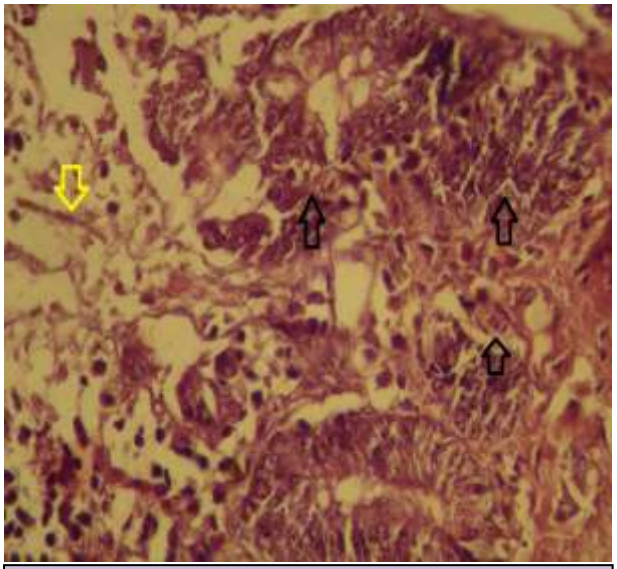

Figure (10) GC^{+}day7: section of small intestine showed sloughing and distruction of intestinal villi(yellow arrow) as well as necrosis of intestinal glands (black arrows). H&E, 400X.

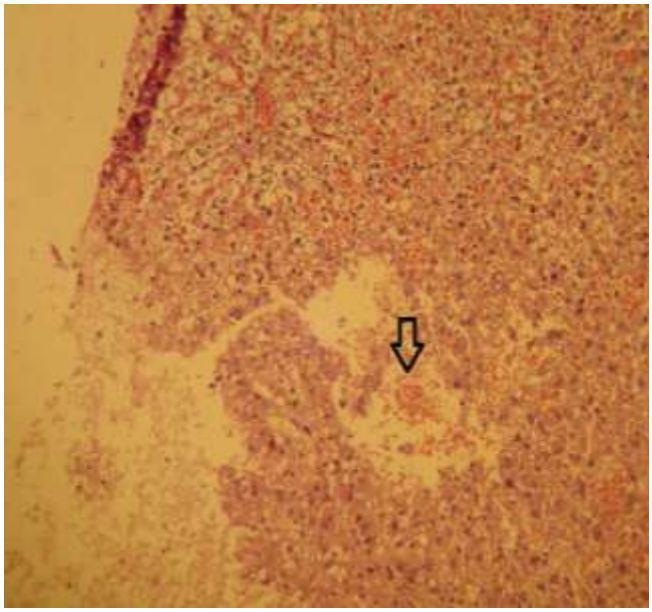

Figure (11)GC^{+}day14: section of liver revealed hemorrhagic necrosis of liver. H&E, 100X.

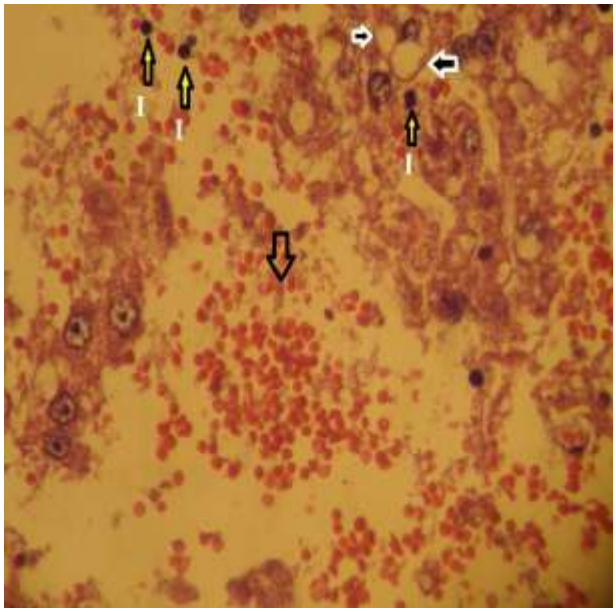

Figure (12)GC^{+}day14: section of liver revealed hemorrhagic necrosis (black arrow) associated with fatty degeneration (white arrows) and accumulation of inflammatory cells (yellow arrows). H&E,

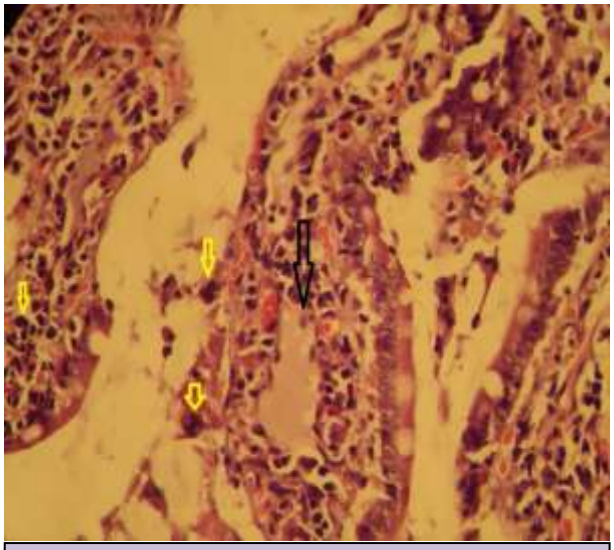

Figure (13)GC^{+}day14: section of small intestine showed hypertrophy of intestinal villi (black arrow) with accumulation of inflammatory cells (yellow arrows). H&E, 400X.

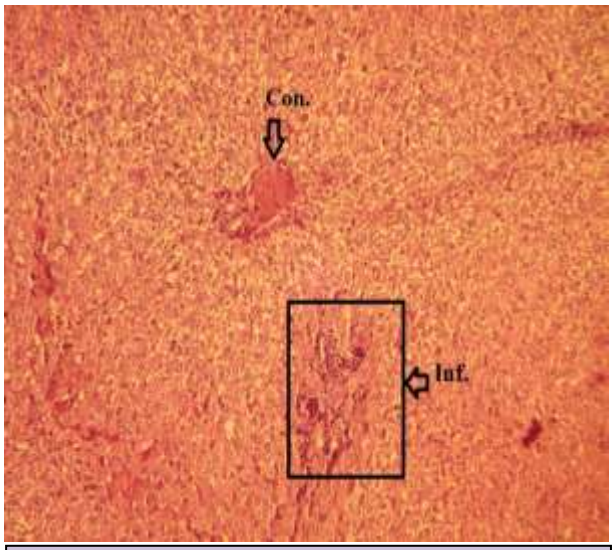

Figure (14)GC^{+}day21: section of liver showed hepatitis ; there are congestion(Con.) with accumulation of inflammatory cells (Inf.). H&E, 100X.

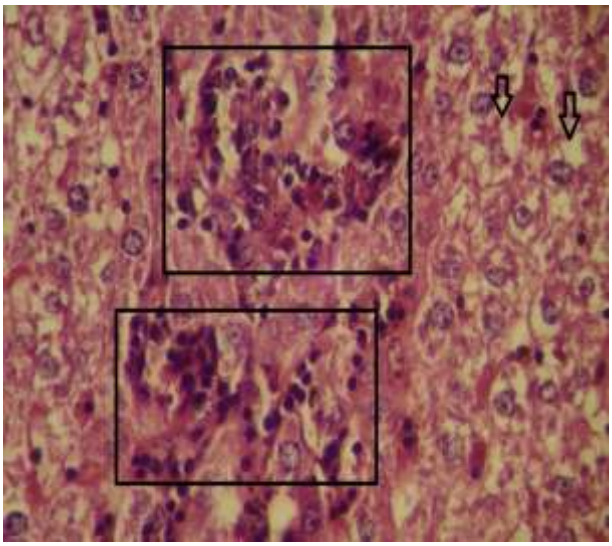

Figure (15)GC^{+}day21: section of liver showed hydropic degeneration (black arrows) with accumulation of inflammatory cells (boxes). H&E, 400X.

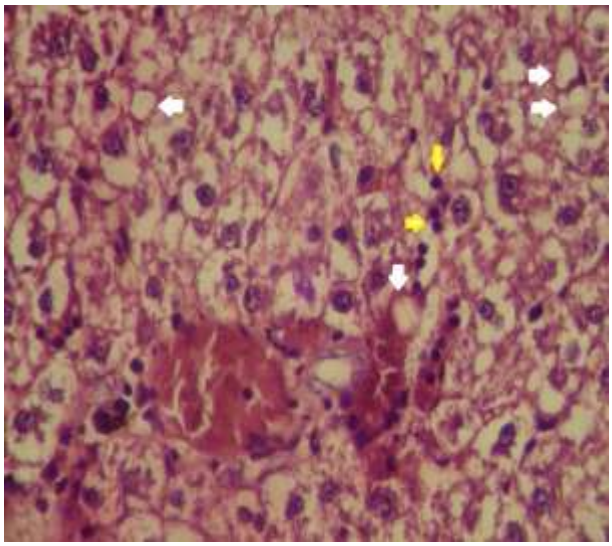

Figure (16)GC^{+}day21: section of liver showed congestion with fatty changes (white arrows) in some of hepatocytes and accumulation of inflammatory cells (yellow arrows).

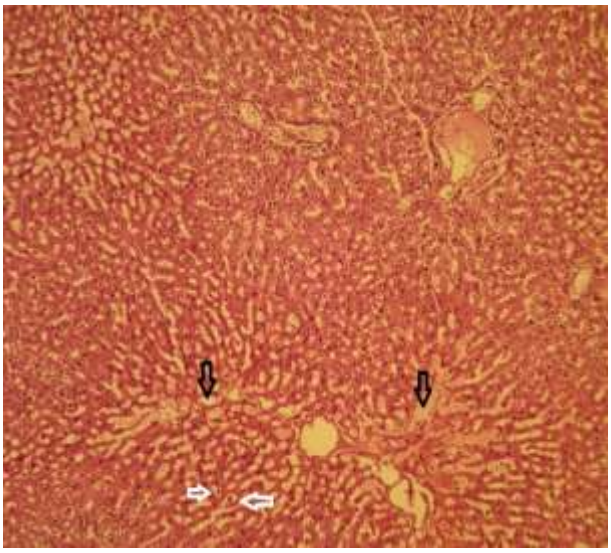

Figure (17) GT1-day7: section of liver showed normal liver texture but there are dilatation of some bile ducts and sinuses (black arrows) as well as engorgement some of bile ducts with bile (white arrows). H&E, 100X.

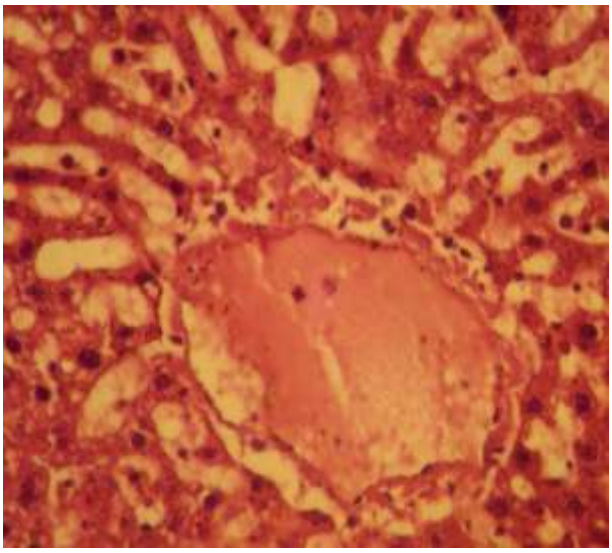

Figure (18) GT1-day7: section of liver showed normal hepatocytes, but there are congestion of portal vein with dilation of bile ducts. H&E, 400X.

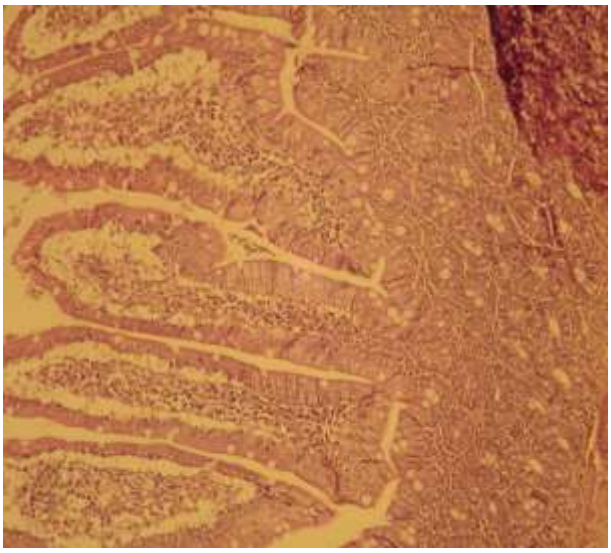

Figure (19)GT1-day7: section of intestine showed normal intestinal tissues. H&E, 100X.

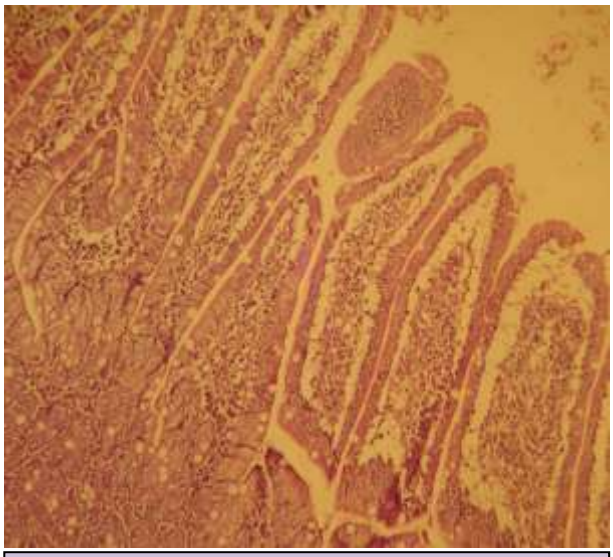

Figure (20)GT1-day14: section of intestine showed normal intestinal tissues. H&E, 100X.

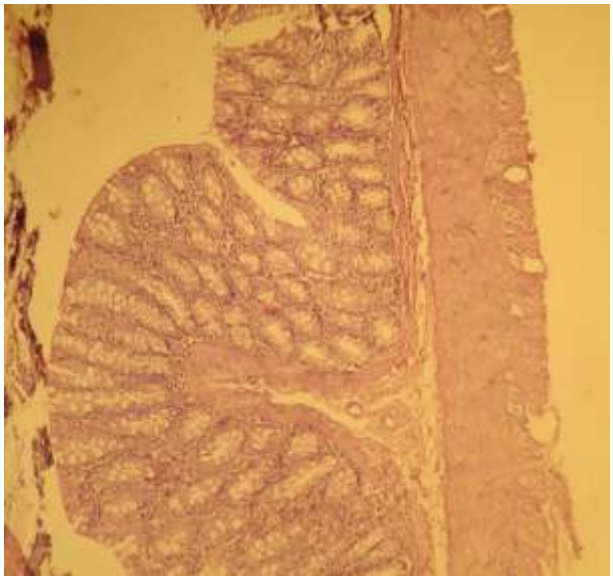

Figure (21)GT1-day21: section of intestine showed normal intestinal tissues, but there is a thickening in the muscularis layer of mucosa. H&E, 100X.

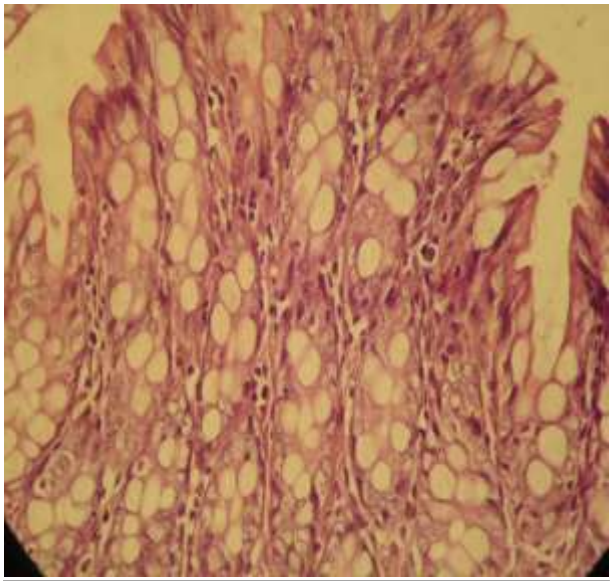

Figure (22)GT1-day21: section of intestine showed normal intestinal tissues. H&E, 400X.

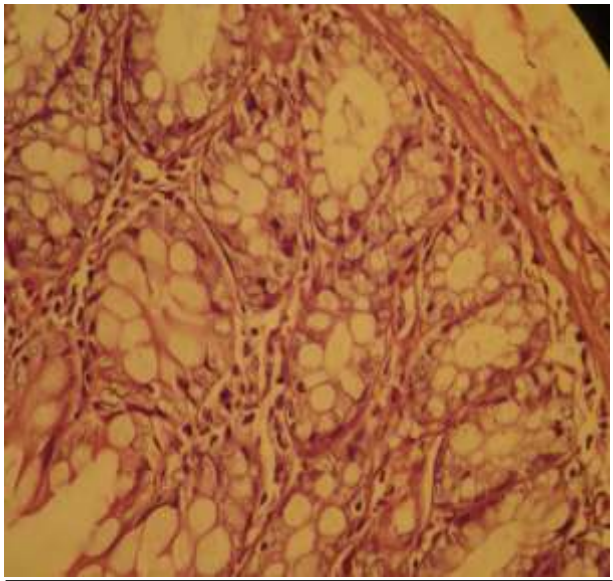

Figure (23) GT1-day21: section of intestine showed normal intestinal tissues as well as enlargement in the intestinal glands that full with secretion. H&E, 400X.

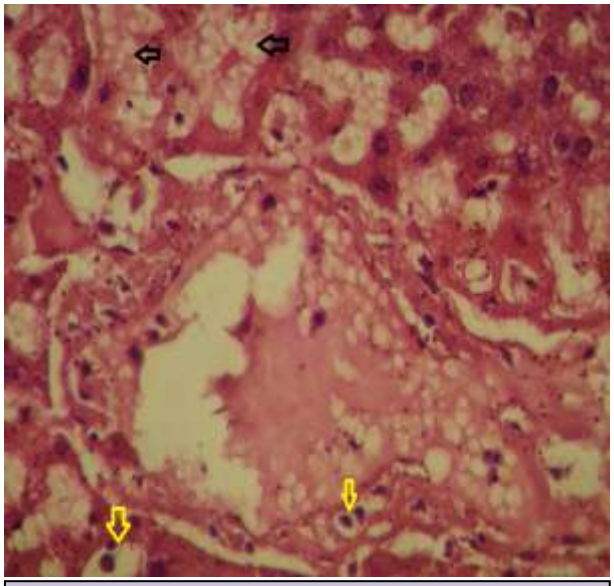

Figure (24) GT2-day7: section of liver showed hydropic degeneration (yellow arrows) with accumulation of inflammatory cells (boxes) with necrosis of some of hepatocytes (Black arrow). H&E, 400X.

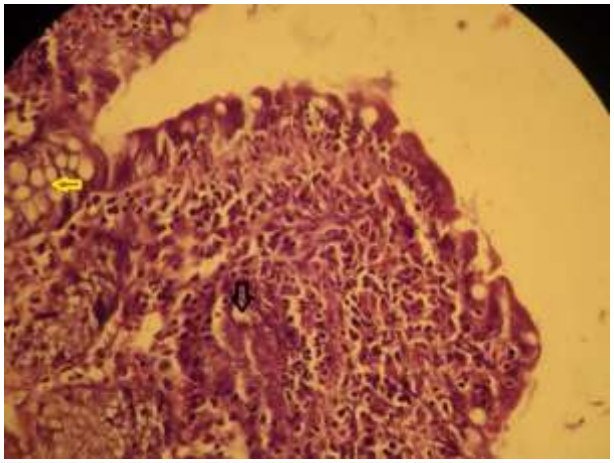

Figure (25) GT2-day7: section of small intestine showed atrophic mucosa thinner than normal and shortened and widely separated. The mucosa consists of irregular glands (black arrow) and many of them containing large droplets of mucin (yellow arrow). H&E, 100X.

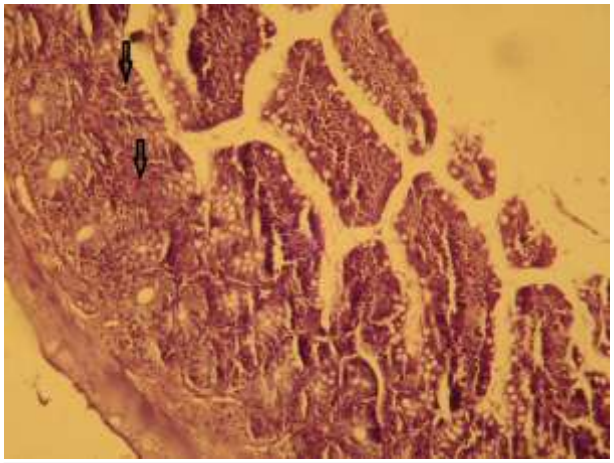

Figure (26) GT2-day14: section of small intestine showed infiltration of the duodenal mucosa by inflammatory cells (black arrows) with loss of villi (villous atrophy), and hyperplasia (elongation) of crypts. H&E, 100X.

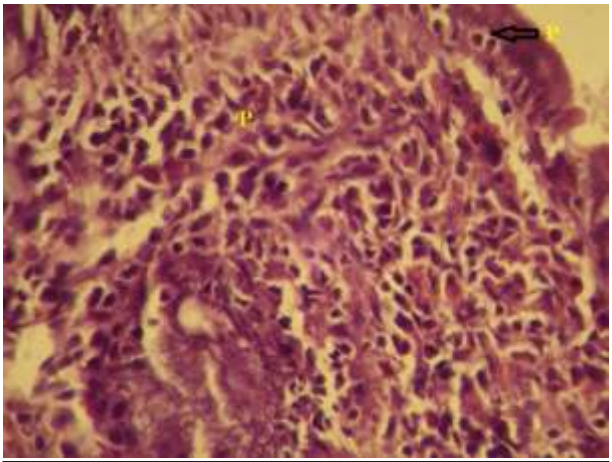

Figure (27) GT2- day21: section of small intestine showed flat small bowel mucosa with infiltration of the duodenal mucosa by inflammatory lymphocytes (L) and plasma cells (P). H&E, 100X.

Acknowledgment: We take this opportunity to express our profound thanks and gratitude to the Iraqi ministry of higher education & scientific research / development & research department to support our study in all scientific apparatuses, chemicals & laboratory instruments that needed for complete this work.

References

1. **Davies , J. (1994).** Inactivation of antibiotic and the dissemination of resistence genes.Sci.264:375-382.
2. **Akah, P.A. (1989)** .Purgative potentials of *Euphorbia heterophylla*. Fitoterapia 60: 45 – 48
3. **Knutton, S.; Baldwin, T.; Williams, P. H. and McNeish, A. S. (1989).** Actins accumulation at sites of bacterial adhesion to tissue culture cells: basis of a new diagnostic test for enteropathogenic and enterohemorrhagic *Escherichia coli .Infect Immun*.; 57: 1290-8.
4. **Jed W.F. and Moringa, O.(2005).** Review of the medical evidence for its nutritional, therapeutic and prophylactic properties. Part1. Trees for life;1(5).
5. **Alali, W.Q.; Scott,H.M. ; Christian,K.L.; Fajt,V.R.; Harvey,R.B and Lawhorn,D.B. (2009).** Relationship between level of antibiotic use and resistance among *Escherichia coli* isolates from integrated multi-site cohorts of humans and swine. Prev Vet Med, 90: 160-167. Bae JH, 2005. Antimicrobial effect of *Lonicerae Flos*
6. **De Sliva , T. (2000).** Industrial utilization of medicinal plants in developing countries. Industrial sector and environmental division UNIDO.PP:1-11.
7. **Gotep, J.G. ; Agada, G. ; Gbise, S. and Chollom , S.(2009).**Antibacterial activity of ethanolic extract of *Acalypha wilkesiana* leaves growing in jos , plateau state ,Negeria. Malaysian Journal of Microbiology, Vol 6(2) 2010, pp. 69-74.
8. **Wang ,Z.; Pan ,Z. ; Ma ,H. and Atungulu,G.G.(2011).**Extract of phenolics from Pomeganate peels. The Open Food Science Journal, 2011, 5, 17-25.

9. **Li, Yunfeng, Guo, Changjiang, Yang, Jijun, Wei, Jingyu, Xu, Jing and Cheng, Shuang, (2006).** Evaluation of antioxidant properties of pomegranate peel extract in comparison with pomegranate pulp extract . Food Chemistry, 96: 254-260.

10. **Endo, E.H.; Ueda-Nakamura,T. ; Nakamura,C.V. and Fihlo,B.P.(2012).** Activity of Spray-dried Microparticles Containing Pomegranate Peel Extract against *Candida albicans.*molecules . 17 : 10094-10107.

11. **Ahmed , M.M. and Ali,S.E. (2010).** Protective effect of pomegranate peel ethanol extract against ferric nitrilotriacetate induced renal oxidative damage in rats Journal of Cell and Molecular Biology 7(2) & 8(1): 35-43.

12. **Moon, H.W. (1997).** Comparative histopathology of intestinal infections. *Adv Exp Med Biol.*; 412:1-19.

13. **Griffin, P. M. ; Olmstead, L. C. and Petras, R. E. (1990).** *Escherichia coli* O157:H7-associated colitis: a clinical and histological study of 11 cases.*Gastroenterology;* 99:142-149 .

14. **Nadim, M.A.; AL-Samarrae, S.A.G.; Zafer, S.A.; Hanna, A.T. and Khalf, A.M. (1982).** Clinical Vetetinary medicine 1sted AL-Resala-Kiwut. pp: 2274 .

15. **Agha, F.E.; Hassannane, M.M.; Omara, E. A.; Hasan, A. M. and El-Toumy, S. A. (2013).** Protective Effect of *Punica granatum* Peel Extract Against Pentachlorophenol-Induced Oxidative Stress, Cytogenetic Toxicity and Hepatic Damage in Rats. Australian Journal of Basic and Applied Sciences, 7(2): 853-864.

16. **Kaur, G.; Jabbar, Z.; Athar, M. and Alam, M.S. (2006).** *Punica granatum* (pomegranate) flower extract possesses potent antioxidant activity and abrogates Fe-NTA induced hepatotoxicity in mice. Food Chem. *Toxicol.*; 44: 984-993.

17. **Celik, I.; Atilla, T. and Ismail, I. (2009).** Hepatoprotective role and antioxidant capacity of pomegranate (*Punica granatum*) flowers infusion against trichloroacetic acid-exposed in rats. *Food Chem. Toxicol.*; 47: 145-149.

18. **Voravuthikunchai, S. P.; Sririrak, T.; Limsuwan, S.; Supawita, T.; Iida, T. and Honda, T.(2005).** Inhibitory Effects of Active Compounds from *Punica granatum* Pericarp on Verocytotoxin Production by Enterohemorrhagic *Escherichia coli* O157: H7. *J.Health Sci.*, 51(5): 590-596.

19. **Pillai, N.R. (1992).** Anti-diarrhoea activity of *Punica granatum* in experimental animals. *Int. J. Pharmacol.*; 30: 201.

20. **Viuda-Martos, M.; Fernández-López, J. and Pérez-Álvarez, J.A. (2010).** Pomegranate and its Many Functional Components as Related to Human Health: A Review. *Comprehensive Reviews in Food Science and Food Safety*; 9 (6):635–654.

دراسة تأثير خلاصة قشور الرمان المائية في علاج الاسهال المستحدث تجريبيا في الجرذان

علي محمد غازي حسن خلف عليوي احمد جاسم نعمة
كلية الطب البيطري / جامعة القادسية

الخلاصة :

هدفت الدراسة الحالية التحري عن الفعالية المضادة للاسهال للخلاصة المائية لقشور الرمان في الجرذان المستحدثة فيها الاسهال تجريبيا عن طريق اعطاء جرثومة الاشريشيا القولونية . كشفت نتائج الدراسة الحالية وابتدا من الاسبوع الثاني من بدء العلاج ان كل من الكبد والامعاء كانا طبيعيين ولم يلاحظ اي افات عيانية واضحة في مجموعة GT1 والتي كانت تختلف بصورة كبيرة عن الافات العيانية التي تم تسجيلها في مجموعة السيطرة الموجبة GS^+ حيث لوحظ وجود التهاب الكبد النزفي والتهاب الامعاء الشديد ، وجود اكياس بيضاء اللون في الكبد وتضخم الامعاء الخزبي ، اضافة الى تواجد محتويات عجينية صفراء وتضخم بالكبد في الوقت نفسه لوحظت اختلافات في الافات العيانية عن مجوعة GT2 والتي عوملت بلاموكسسلين والتي كشفت وجود احتقان في الامعاء كما اظهرت وجود محتويات عجينية صفراء داخل الامعاء .

اظهرت نتائج التغيرات الشكلية في مجموعة GS^+ بعد 7 ايام من احداث الاصابة بجرثومة الاشريشيا القولونية وجود التهاب الكبد النزفي ، كما سجلت وجود تغيرات واضحة في الامعاء الدقيقة تمثلت بوجود انسلاخات شديدة في زغابات الامعاء وخزب وتنخر في الطبقة المخاطية كذلك وجود تنخر في الغدد المعوية ، بعد 14 يوم من احداث الاصابة تمثلت التغيرات المرضية بوجود تنخر نزفي بالكبد رافقه تنكس دهني وتجمع للخلايا الالتهابية ، كما اظهرت التغيرات النسجية في الامعاء الدقيقة حدوث فرط تنسج للزغابات مع تجمع للخلايا الالتهابية.

اما التغيرات الشكلية في مجموعة GT1 بعد 7 يوما من بدء العلاج بخلاصة قشور الرمان لوحظ وضع كبد طبيعي مع وجود توسع محدود لبعض القنوات الصفراوية والجيوب واحتقان بعض القنوات الصفراوية وامتلاءها بمادة الصفراء. في الوقت نفسه اظهرت الدراسة الشكلية ان نسيج الامعاء طبيعي ، بعد 14 يوما من العلاج بخلاصة قشور الرمان اظهر الكبد والامعاء نفس التغيرات التي ظهرت عند اليوم السابع من العلاج ، بعد 21 يوما كانت الامعاء طبيعية مع وجود تثخن في الطبقة العضلية للبطانة المعوية وتضخم محدود في الغدد المعوية .

اظهرت التغيرات الشكلية في مجموعة GT2 بعد 7 ايام من العلاج بعقار الاموكسلين وجود تنكس مائي مع تجمع للخلايا الالتهابية وتنكسات لبعض الخلايا الكبدية بينما كانت الامعاء الدقيقة ضمورا والبطانة انحف من الطبيعي واقصر ومنفصلة بشكل واسع ، الطبقة المخاطية تحتوي على غدد غير منتظمة والعديد منها تحتوي على قطرات كبيرة من المخاط ، بعد 14 يوما من بدء العلاج تضمنت التغيرات تنكس مائي مع تجمع للخلايا الالتهابية وتنخر بعض الخلايا الكبدية ، اما الامعاء فلوحظ ارتشاح للخلايا الالتهابية مع فقدان للزغابات وفرط التنسج للاقبية وبعد 21 يوما من العلاج بالاموكسلين لوحظ تسطح للطبقة المخاطية المعوية وارتشاح للخلايا اللمفاوية والخلايا البلازمية للطبقة المخاطية للاثنى عشري

.....

الكلمات الافتتاحية : الخلاصة المائية للرمان ، الاسهال ، الاشريشيا القولونية ، الجرذان