

Comparative Study for Complications of Otoplasty between Patients under Ten Years and above Ten Years Old

Ahmed Miri saadoon ¹, Ali Abd-Almer Jwad ² and Riyadh K. Madloul ³

^{1,2} University of Al-Qadisiyah, College of Medicine, Department of surgery, Iraq

³ Al-Diwaniyah teaching hospital, Diwaniyah, Iraq

Email: ahmedalmrsool2@yahoo.com

ABSTRACT

The term prominent ears refer to ears that stick out enough to appear abnormal. Ears can be considered prominent if they stand out more than 2 cm from the side of the mastoid. The normal external ear is separated by less than 2 cm from, and forms an angle of less than 25 degree with, the side of the head. To correct prominent ears, the anatomical abnormality is determined. The three main common causes of prominent ears are under development of antihelical fold, conchal hypertrophy and protruding earlobe. Patient and Methods: Twenty patients with congenital prominent ears presented to the department of plastic surgery at Diwaniya teaching hospital and private clinic between January ,2015 to May ,2018. Patients were studied clinically and evaluated preoperatively according to:- (1) Age: we divided the patients into two age groups (under ten years and above ten years). (2) Sex (3) Whether the ear deformity was unilateral or bilateral. (4) If the cause of prominent was antihelix, conchal, earlobe problems or combinations of theses causes. Results: The total number of patients involved in this study was 20 patients , 14 patients (70%) were male and 6 patients (30%) were female with male to female ratio was 2.3:1 .Ten patients were below ten years with median age was seven years and the other ten patients were above ten years with median age was twenty one years. Otoplasty was bilateral in all patients The procedure was performed under general anesthesia in all patients under ten years old and in five patients above ten years (50%).The cause of deformity was loss of definition of antihelix in ten patients(50%) and the management was according to the age , the children under ten years of age were managed by suturing technique (Mustarde) for correction of antihelix deformity and in patients above ten years were managed by combination of incision , scoring and suture techniques. Four patients (20%), the cause of deformity was conchal hypertrophy and corrected by conchal reduction.

Keywords: Otoplasty, antihelical fold, conchal hypertrophy, protruding earlobe, suturing technique, conchal reduction

Correspondence:

Ahmed Miri Saadoon

Al-Diwaniyah teaching hospital, Diwaniyah, Iraq

Email: ahmedalmrsool2@yahoo.com

INTRODUCTION

The term prominent ears refer to ears that stick out enough to appear abnormal. Ears can be considered prominent if they stand out more than 2 cm from the side of the mastoid ¹.The normal external ear is separated by less than 2 cm from ,and forms an angle of less than 25 degree with , the side of the head . To correct prominent ears, the anatomical abnormality is determined. The three main common causes of prominent ears are under development of antihelical fold conchal hypertrophy and protruding earlobe.

Goals of otoplasty: The goal of otoplasty is to set back the ears in such a way that the contours appear soft and natural.

Timing of otoplasty

There is no absolute role about when otoplasty should be performed. In young children with extremely prominent ears, a preferable age is approximately 4 years and the procedure require general anesthesia. In other cases, usually minor, the parents may choose to wait until the child can participate in the decision. This may allow the procedure to be performed under local anesthesia ². Performing ear surgery on children often provide significant psychological benefits. Children with large ears may feel self- conscious ³.

In children up to the age of ten years , a soft ,elastic or easily pliable auricular cartilage is often still present so that simple procedures ,such as suturing technique described by Mustarde , are frequently enough to achieve

a cosmetically good and lasting result. In adults, the auricular cartilage has usually become stiff. Therefore, a combination of incision, scoring and suture techniques is usually required ⁴.

Operative procedure

Numerous methods have been described for correcting the anatomic abnormalities:

Antihelical fold manipulation

1.Suturing of cartilage. Matress sutures 5. 2.Stenstrom technique of anterior abrasion ⁶. 3.Full thickness incisions. A single full thickness incision (the Converse /Wood-Smith technique) ⁷.

Conchal alteration

1.Suturing: was described Furnas ⁸. 2.Conchal excision: from either anterior or posterior approach, a piece of cartilage crescent in shape ². 3.Combination of Furnas and conchal excision procedures.

Correction of earlobe prominence: a small amount of skin is excised on medial surface of the earlobe described by Gosain ⁹.

complications of otoplasty surgery

1.infection 2. bleeding 3. suture complications 4. recurrence: the ear that start sticking out again. 5. unsatisfactory appearance 6. asymmetry 7. patient dissatisfaction.

A thorough explanation of risks of the procedure must be accompanied by a discussion that patient may need reoperation to achieve the desired result¹.

PATIENTS AND METHODS

Twenty patients with congenital prominent ears presented to the department of plastic surgery at Diwaniya teaching hospital and private clinic between January ,2015 to May ,2018. Patients were studied clinically and evaluated preoperatively according to:-

1. Age: we divided the patients into two age groups (under ten years and above ten years). 2. Sex 3. Whether the ear deformity was unilateral or bilateral.

4. If the cause of prominent was antihelix, conchal, earlobe problems or combinations of these causes.

Operative measures

1. Anesthesia: surgeries were done under local and general anesthesia.

2. Systemic cephalosporin prophylactic antibiotic was giving pre-operatively.

3. Surgical techniques: the technique that used to correct deformity was different according to the age of the patients and the cause of deformity.

In children under ten years of age, suturing technique described by Mustarde (Matress sutures are placed from the scapha to concha) used to correct antihelix deformity. In adults, the auricular cartilage is stiff therefore we used

combination of incision, scoring and suture techniques. Non-absorbable nylon suture (4-0) was used in suturing maneuver. In cases of conchal hypertrophy, conchal reduction may require both in children and adults. In all cases our approach was posterior.

Post-operative measures

oral cephalosporin prophylactic antibiotic was giving for eight days post-operatively. The patient will need bandages over their ears for seven days after surgery. While the bandages are in place, they will not be able to wash their hair. After removing the bandages, a loose but supportive headband is worn over the ears at night.

The skin stitches removed at eight post-operative day and the patient can return to normal activity after two weeks.

On follow up we assessed

During the 1st month we saw the patients every 10 days looking for early wound complications like infection, bleeding and hematoma.

After that we followed the patient everyone month for six months looking for:

1. position of ears related to scalp and if there is any asymmetry. 2. recurrence of the prominence. 3. patient satisfaction 4. extrusion of stiches 5. scar problems.

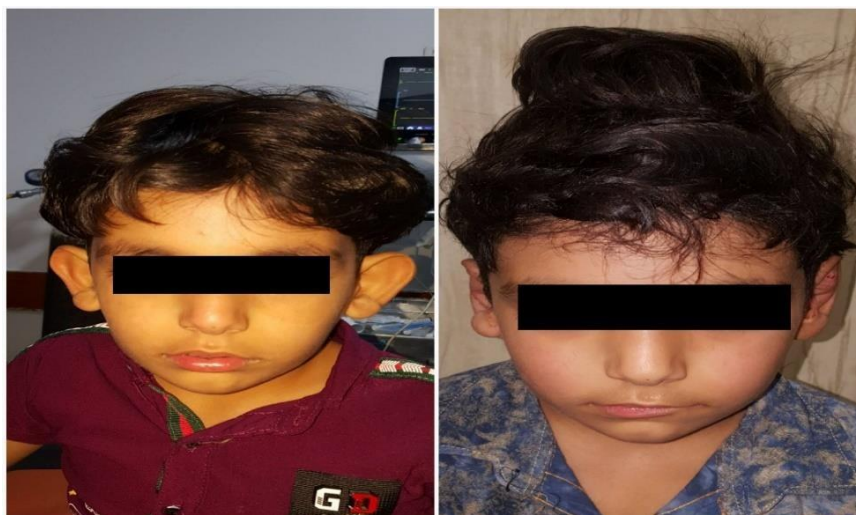

Figure 1. pre- and post-operative child less than 10 years with prominent ear

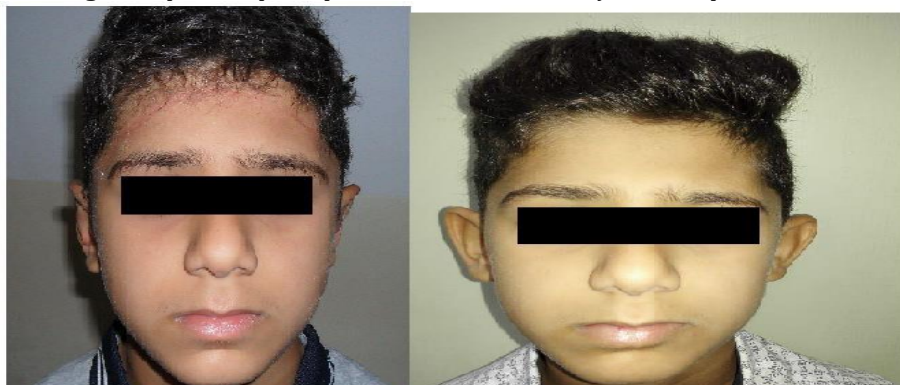

Figure 2. pre- and post-operative child above 10 years with prominent ear

RESULTS

The total number of patients involved in this study was 20 patients, 14 patients (70%) were male and 6 patients (30%) were female with male to female ratio was 2.3:1

Ten patients were below ten years with median age was seven years and the other ten patients were above ten years with median age was 21 years.

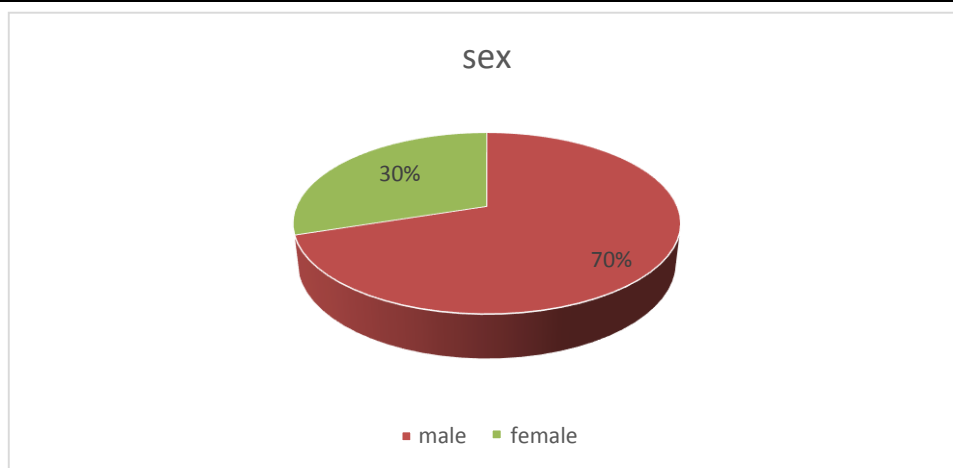


Figure 2. Male: Female ratio

Otoplasty was bilateral in all patients.

The procedure was performed under general anesthesia in all patients under ten years old and in five patients above ten years (50%).

Table 1. type of anesthesia

Type of anesthesia	Patients under ten years		patients above ten years		p-value
	Number	Percent	Number	Percent	
General anesthesia	10	100%	5	50%	0.01
Local anesthesia	0	0	5	50%	

The cause of deformity was loss of definition of antihelix in ten patients(50%) and the management was according to the age , the children under ten years of age were managed by suturing technique (Mustarde) for correction of antihelix deformity and in patients above ten years were managed by combination of incision , scoring and suture techniques. Four patients (20%), the cause of deformity was conchal hypertrophy and corrected by conchal reduction

Early post-operative complications

- a. infection: one case complicated by superficial wound infection without chondritis the patient was 8 years old and treated by systemic antibiotic.
- b. bleeding: one patient complicated by bleeding at the same day of surgery. The patient was 20 years old treated by exploration of the wound in the operating room and cauterization of bleeder.
- c. hematoma: no hematoma was reported.

Table 2. early postoperative complications of otoplasty

Complications	Patients under 10 years		Patients more than 10 years		p-value
	Number	Percent	Number	Percent	
Infection	1	10%	0	0	0.9
Bleeding	0	0	1	10%	0.9
Hematoma	0	0	0	0	

Late complications

- a. Asymmetry: one patient (10%) under 10 years and two patients (20%) above ten years were complaining from asymmetry between right and left ears. The asymmetry was noticed one month after surgery, we informed the patients that may need another surgery to correct the asymmetry, but they did not come back for surgery.
- b. Recurrence: one patient (10%) under 10 years and two patients (20%) above ten years were complaining from recurrence of the prominence. we did for them another corrective surgery after one year and the result was satisfactory.

- c. Patients and parents' dissatisfaction: two patients (20%) under 10 years and four patients (40%) above ten years were unsatisfied from the result because of the asymmetry or recurrence of the prominence.
- d. Extrusion of stiches: only one patient (10%) above ten years old was complained from stich extrusion from the wound two months after surgery, the knot was grasped with forceps and excised with fine scissor.
- e. Scar problems: two patients (20%) under ten years old were complained from hypertrophic scar.

Table 3. late postoperative complications of otoplasty.

	Patients under 10 years		Patients more than 10 years		p-value
	Number	Percent	Number	Percent	
Asymmetry	1	10%	2	20%	0.5
Recurrence	1	10%	2	20%	0.5
Patients or parents' dissatisfaction	2	20%	4	40%	0.3
Extrusion of stiches	0		1	10%	1
Scar problems	2	20%	0	0	0.4

DISCUSSION

Pinnaplasty, the correction of protruding auricles, is a commonly performed cosmetic surgical procedure. It is a procedure that can produce considerable surgeon and patient satisfaction. Affecting 5% of the population, protruding or prominent auricle are a common congenital anomaly. solving this problem at early childhood can prevent ridicule from friends and enhance self-confidence. pinnaplasty is most commonly performed on children in contrast with other cosmetic surgeries that usually performed at adulthood.

In our study only one patient in age group under ten years developed early post-operative complication (infection) while in group above ten years only one patient developed early post-operative complication(bleeding) although statically not significant.

In late post-operative complications concerning patients below ten years Asymmetry only one patient. Recurrence only one patient, Patient or parents' dissatisfaction two patients Extrusion of stiches nil, Scar problems two patients. While in patient above ten years asymmetry only two patients. Recurrence two patients, Patient or parents' dissatisfaction four patients Extrusion of stiches one patient, Scar problems nil. although higher percentage of late complications in older age group but statically not significant, these results are comparable with Panettiere etal¹¹.

Like many surgical interventions involving the face of child, there is a concern about how the surgical site will react to effect of normal growth. Until recently, very few surgeons felt comfortable operating on the ear of a young child due to concerns about longevity and altered growth. Adamson et al. studied the growth patterns of the external ear of 2300 ears and showed that the ear reaches 85% of its adult size by 3 years of age¹⁰. unfortunately, we couldn't assess this outcome due to short duration of study Only 2% developed recurrence deformity, less than Kompatscher et al¹² who developed higher recurrence rate 14% while in compares with Murat Songu, Hamit Adibelli¹³ who developed less recurrence rate and more patients and parent satisfaction in considering they operate on age less than five.

Child with prominent auricle suffering from psychological pressure even in preschool period or kindergarten which is usually underestimated and management usually at school age.

Another advantage of early surgery is elasticity and malleability of auricular cartilage in younger age children which give the utility of no need to cartilage cutting.

CONCLUSION

1. Early and late prominent ear surgery had nearly the same successful and complications rate.

2. Early surgery offers better psychological outcomes.
3. Easer surgical techniques in dealing with cartilages were offered by early surgery
4. Late surgical correction makes local anesthesia as an option versus general anesthesia

REFERENCES

1. Christian Nordqvist.Otoplasty: is it a good idea.Wed 29 Mar 2017
2. Charles H. Throne. Otoplasty Grabb and Smith's Plastic Surgery (GRABB'S PLASTIC SURGERY) Seventh Ed (2014), P:530.
3. Charles H. Throne.benefit of otoplasty. Plastic and Reconstructive surgery
4. Andreas Naumann. Otoplasty –techniques, characteristics and risks GMS Current Topics in Otorhinolaryngology, Head and Neck Surgery Vols.6 2007.
5. Mustarde JC. Correction of prominent ears using buried mattress sutures.Clin Plast Surg. 1978; 5:459
6. Stenstrom JC. et al. The Stenstrom otoplasty. Clin Plast Surg. 1978; 5:465.
7. Converse JM,et al . Tetchical details in the surgical correction ofthe lop ear deformity, Plast Reconstr Surg. 1963 ;31 (2):118.
8. Furnas D. Suture otoplasty update. Perspect Plast. Surg. 1990; 4:136.
9. Gosain AK, et al. A noval approach to correction of the prominent lobule during otoplasty. Plast Reconstr Surg 2003;112,2:575-583
10. Panettiere P, Marchetti L, Accorsi D, Del Gaudio GA. Otoplasty: a comparison of techniques for antihelical defects treatment. Aesthetic Plast Surg 2003;27(6):462–5 [Epub March 22, 2004].
11. J.E. Adamson, C.E. Horton,H.H. Crawford, Growth pattern of the external ear, Plast. Reconstruct. Surg. 36 (1965) 466–470)
12. Kompatscher P, Schuler CH, Clemens S, et al. The cartilage-sparing versus the cartilage-cutting technique: a retrospective quality control comparison of the Francesconi and Converse otoplasties. Aesthetic Plast Surg 2003;27(6):446–53[Epub March 4, 2004].
13. Ewaid, S.H., Abed, S.A., 2017. Water quality index for Al-Gharraf river, southern Iraq. Egypt. J. Aquatic Res. 43 (2), 117–122. <http://dx.doi.org/10.1016/j.ejar.201703001>.
14. Ewaid, S.H.; Abed, S.A.; Al-Ansari, N. Crop Water Requirements and Irrigation Schedules for Some Major Crops in Southern Iraq. Water 2019, 11, 756.

15. Ewaid, S.H.; Abed, S.A.; Al-Ansari, N. Water Footprint of Wheat in Iraq. *Water* 2019, 11, 535.
16. Salwan Ali Abed et al 2019 *J. Phys.: Conf. Ser.* 1294 072025.
17. Ewaid, S.H.; Abed, S.A.; Al-Ansari, N. Assessment of Main Cereal Crop Trade Impacts on Water and Land Security in Iraq. *Agronomy* 2020, 10, 98.
18. Ewaid, S.H.; Abed, S.A.; Al-Ansari, N.; Salih, R.M. Development and Evaluation of a Water Quality Index for the Iraqi Rivers. *Hydrology* 2020, 7, 67.
19. Murat Songu, Hamit Adibelli *International Journal of Pediatric Otorhinolaryngology* 74 (2010) 292–296.